

## "ALL-ON-6", ADVANTAGES AND DISADVANTAGES OF THIS MODERN DENTAL RESTORATION SOLUTION

Oleg Solomon<sup>1</sup>, Viorica Chetrus<sup>1\*</sup>, Anamaria Zaharescu<sup>2\*</sup>, Razvan Leata<sup>2</sup>, Mariana Ilie<sup>2</sup>, Antoanela Magdalena Covaci<sup>2</sup>, Kamel Earar<sup>2</sup>

<sup>1</sup> Faculty of Stomatology, Nicolae Testemitanu State University of Medicine and Pharmacy, Chisinau, Republic of Moldova

<sup>2</sup> Faculty of Medicine and Pharmacy, University "Dunarea de Jos" Galati, Romania

Corresponding authors: [viorica.chetrus@usmf.md](mailto:viorica.chetrus@usmf.md), [anamaria.zaharescu@ugal.ro](mailto:anamaria.zaharescu@ugal.ro)

All authors have the same contributions.

### Abstract

The All-on-6 technique is a modern and effective solution for complete tooth restoration, using six dental implants to support a fixed denture. This method provides excellent long-term results, with significant benefits in terms of durability, stability, and functionality of the implants. Titanium implants, once integrated into the bone through the osseointegration process, can last for decades, and the prosthesis attached to them provides patients with an experience similar to that of natural teeth. One of the major advantages of the All-on-6 technique is the prevention of bone resorption, a common problem in patients who have lost teeth. The implants stimulate the jawbone, maintaining volume and preventing facial changes associated with bone loss. In the long term, the success of this treatment depends on rigorous oral hygiene and regular visits to the dentist for denture maintenance and monitoring of the condition of the implants. Although the risks of complications such as peri-implantitis or osseointegration failure exist, they are rare and can be prevented with proper care. In conclusion, All-on-6 offers a durable, aesthetic and functional solution for patients with severe tooth loss.

**Keywords:** all-on-6, osseointegration, dental restoration, bone resorption, peri-implantitis

### Introduction

Tooth loss can have a significant impact on quality of life, affecting not only the ability to chew and speak, but also self-confidence. With the advancement in the field of dentistry, dental restoration has evolved from traditional removable dentures to modern and much more effective solutions, such as dental implants. Among these solutions, the All-on-6 technique has gained considerable popularity due to its many advantages over conventional methods. This procedure provides a fully fixed dentition, supported on six dental implants strategically placed in the maxillary or mandibular arch [1-3].

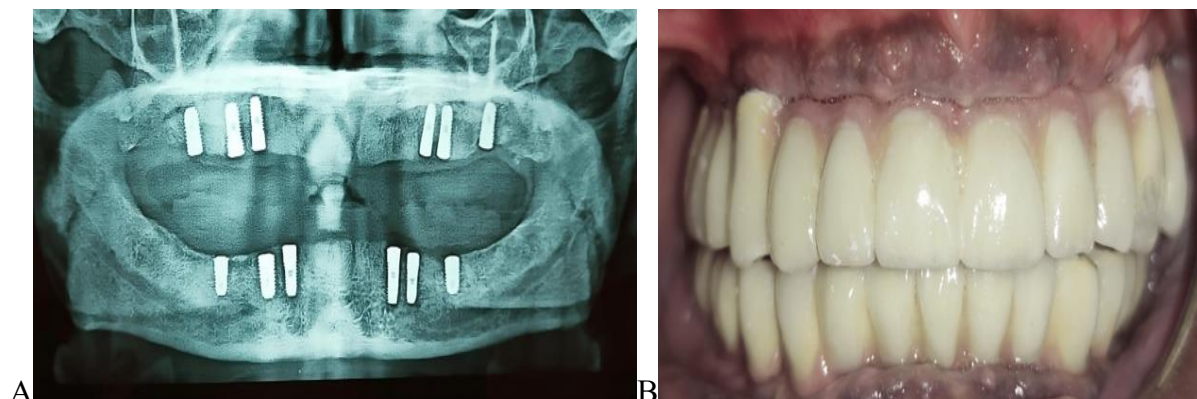
Before the advent of modern techniques, patients who lost most of their

teeth had only two main options available: removable dentures or individual dental implants. Each of these had considerable drawbacks. Mobile dentures, while affordable, often caused discomfort, were unstable, and affected gum and jawbone health. On the other hand, individual implants, although they offer a stable and aesthetic result, involve a much higher cost and a long treatment period, especially when they are necessary for the entire dental arch [1-3].

This is where the All-on-6 technique comes in, which combines the stability benefits of dental implants with a reduced number of interventions, without compromising functionality or aesthetics. This involves fixing a complete dental

prosthesis on only six implants, providing patients with fixed, stable and aesthetic teeth in a relatively short time. The procedure is particularly attractive for those

who have suffered multiple tooth losses or for those who have had to wear removable dentures for years and want a permanent solution [2-4].



**Fig 1.** A-An X-ray showing six implants inserted in both the maxillary and mandibular arches. B-Insertion of the final prosthesis [2].

Another major advantage of the All-on-6 technique is that it can also be applied in cases where patients have some bone loss. Dental implants usually require a sufficient amount of jawbone to be properly fixed. In cases where the maxillary bone has resorbed over time, patients would need additional bone addition procedures. The All-on-6 technique, due to the strategic positioning of implants, can avoid the need for such procedures, thus providing an alternative for those who would otherwise be considered ineligible candidates for traditional dental implants [2-4].

All-on-6 represents a significant evolution in the field of dental restoration not only because of its aesthetic and functional result, but also because of its efficiency in relation to the time required for treatment. In many cases, patients can leave the clinic with a temporary prosthesis fixed on the same day as surgery. This temporary denture provides immediate comfort and allows patients to resume their normal activities without the discomfort of a removable denture [3-5].

However, like any medical procedure, All-on-6 is not without its challenges and risks. Although it is suitable for a wide range of patients, treatment requires careful evaluation of the patient's overall health and bone condition. Correct diagnosis and careful planning are essential for the long-term success of implants [3-5].

In conclusion, the All-on-6 technique offers a revolutionary solution for complete tooth restoration, combining efficiency, aesthetics and durability in a single procedure. It is an excellent option for patients who want fixed and natural teeth, without going through the costs and time required for individual implants. The All-on-6 has thus become one of the most preferred options in modern dentistry, promising long-lasting results and increased comfort for patients [3-5].

#### **All-on-6 procedure, stages and technical details of treatment**

The All-on-6 technique is a modern and effective treatment that involves placing six dental implants to support a

complete fixed denture on the upper or lower arch. This is considered a top solution for patients with total edentulousness or who have lost a significant number of teeth. The procedure is carried out in a series of well-defined stages, meant to ensure stability and long-term results [4-6].

The first step is a detailed consultation with the dentist specialized in implantology. In this stage, the patient's general oral health is assessed, as well as the bone condition through imaging investigations, such as panoramic X-rays or computed tomography (CT). These investigations are essential to determine the

quantity and quality of the maxillary bone, as the implants must be placed in areas that provide sufficient stability [5-7].

Based on the results of the investigations, the doctor develops a personalized treatment plan. This planning involves establishing the exact positions in which the dental implants will be placed. In the case of the All-on-6 technique, the six implants are strategically placed to maximize contact with the bone and evenly distribute the pressure exerted by the fixed prosthesis. This step is crucial to ensure the long-term success of the treatment [5-7].

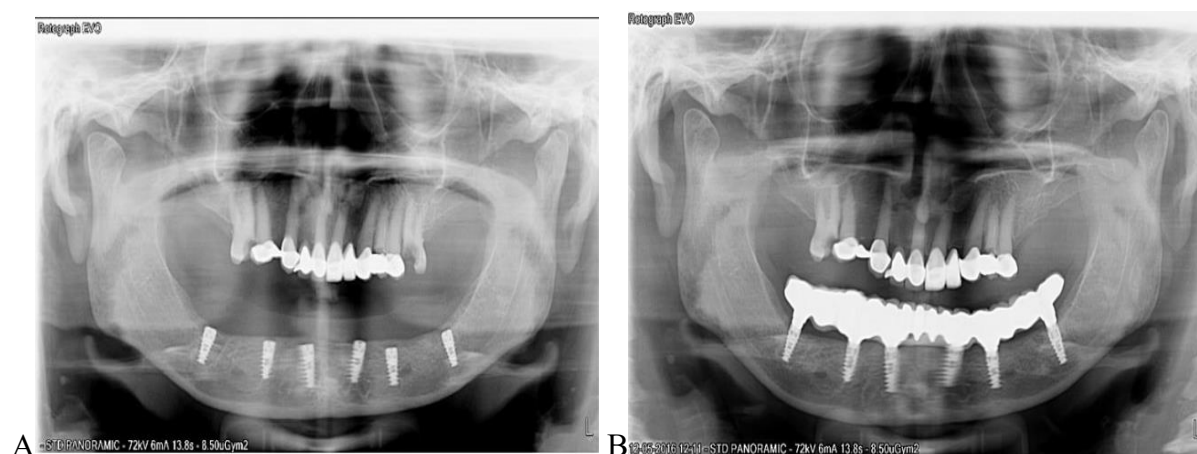


Fig 2. A-Implant positioning, B-Final prosthesis [6].

The actual implantation procedure is a surgical one and is performed under local or general anesthesia, depending on the complexity of the case and the patient's preferences. During the intervention, the doctor makes incisions in the gum to expose the jawbone and insert the six dental implants. The implants are made of titanium, a biocompatible material that integrates very well with the bone through the osseointegration process. These implants are placed at an optimal angle to ensure maximum stability and prevent the need for additional bone addition

interventions [7-9]. A major advantage of this technique is that, in many cases, the doctor can fit a temporary fixed prosthesis on the very day of the intervention. This temporary prosthesis allows the patient to have immediate functionality, providing comfort and adequate aesthetics until the permanent prosthesis is fitted [7-9].

After the implants are placed, there is a healing period that lasts between 3 and 6 months. During this time, the implants gradually integrate with the bone, a process called osseointegration. During this time, patients should follow the doctor's

instructions to prevent complications and ensure proper healing. The temporary prosthesis fixed on the implants offers significant comfort during this period [8-10].

After the osseointegration process is complete, the patient returns for the fitting of the definitive prosthesis. It is made of durable and aesthetic materials, such as zirconium or acrylate, providing a natural look and optimal functionality. The permanent prosthesis is fixed to the implants by means of screws or other fastening systems, providing long-term stability [8-10].

After completing the treatment, the patient must follow a strict oral hygiene protocol and attend regular check-ups to monitor the condition of the implants and prosthesis. Proper oral hygiene and regular visits are essential to prevent complications such as peri-implantitis and to ensure the long-term durability of implants [9-11].

### **Advantages of the All-on-6 technique**

The All-on-6 technique brings multiple benefits, being considered one of the most effective and modern solutions for the complete restoration of teeth in cases of severe total or partial edentulousness. This procedure offers a number of significant advantages in both functional and aesthetic terms, compared to other traditional methods of dental restoration [9-11].

One of the main advantages of the All-on-6 technique is the high stability it provides to the dentures. Dental implants, made of biocompatible titanium, integrate directly into the jawbone through the osseointegration process, ensuring a solid

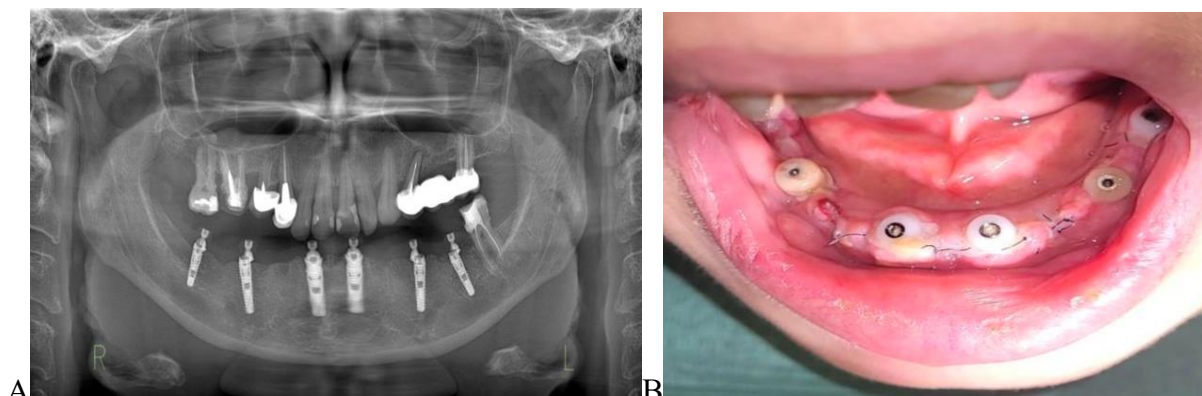
and long-lasting fixation. This stability allows patients to eat, talk, and smile without fear that the denture will move or detach, as is frequently the case with traditional removable dentures [10-12].

Unlike removable dentures, which can cause irritation and discomfort, the All-on-6 technique offers a higher level of comfort. The implant-attached prosthesis does not require adhesives or frequent adjustments and does not put pressure on the gums. Also, the dentures used in this treatment are made of high-quality materials, such as zirconium or acrylate, which mimic the natural appearance of the teeth, providing a particularly pleasing aesthetic [10-12].

Compared to other complete restorative solutions, such as individual dental implants, All-on-6 is a faster and more efficient procedure. Due to the use of only six implants for the entire dental arch, the surgery is less invasive, and the time required for recovery is shorter. Additionally, many patients may receive a temporary denture on the same day as the intervention, meaning they may leave the clinic with immediate functional and aesthetic teeth [11-13].

The All-on-6 technique is ideal for patients who have lost some of their jaw bone mass. Due to the strategic positioning of the implants, this procedure can avoid the need for bone addition, an additional intervention required in the case of individual dental implants. Thus, even patients with moderate bone loss can benefit from this technique without additional complicated procedures [11-13].





**Fig 3.** A-Radiological appearance after insertion of the 6 mandibular implants. B-Six implants placed with healing abutments [12].

Dental implants stimulate the jawbone, preventing bone resorption that frequently occurs as a result of tooth loss. In the absence of stimulation provided by natural tooth roots or implants, the bone begins to resorb, which can lead to changes in the physiognomy of the face. The All-on-6 technique contributes to the maintenance of bone structure and prevents these aesthetic and functional changes [12-14].

Although the upfront costs for All-on-6 can be higher than those for a traditional removable denture, this technique is more affordable than the option of individual implants for each lost tooth. The use of six implants for the entire dental arch significantly reduces treatment costs, and the durability of the prosthesis and implants provides an excellent long-term cost-benefit ratio [12-14].

#### **Disadvantages of the All-on-6 technique**

Although the All-on-6 technique is recognized for its many advantages in restoring complete teeth, it is not without certain disadvantages and challenges. Before opting for this type of treatment, it is important for patients to understand the possible limitations and risks associated with the procedure [14-16].

One of the main disadvantages of the All-on-6 technique is the relatively high cost compared to other dental restorative solutions, such as traditional removable dentures. Although in the long term this investment may be more cost-effective, due to the durability of the implants and the fixed denture, the initial amount can be a barrier for some patients. The costs include not only the implantation procedure itself, but also the preliminary investigations, the materials used and the postoperative follow-up visits [14-16].

The All-on-6 procedure involves complex surgery, which can discourage patients who are afraid of surgery or who have certain health conditions that increase the risks during surgery. Although it is a minimally invasive solution compared to individual dental implants, the All-on-6 technique remains a surgical procedure that can cause discomfort and requires a postoperative recovery period [15-17].

After surgery, it takes a healing period that can last between 3 and 6 months, during which time the implants integrate into the bone (osseointegration). During this period, there is a risk of complications, such as infections or failure of osseointegration, which can lead to rejection of the implants. Patients should also strictly follow their

doctor's recommendations to avoid such problems, which can be a challenge for some patients [15-17].

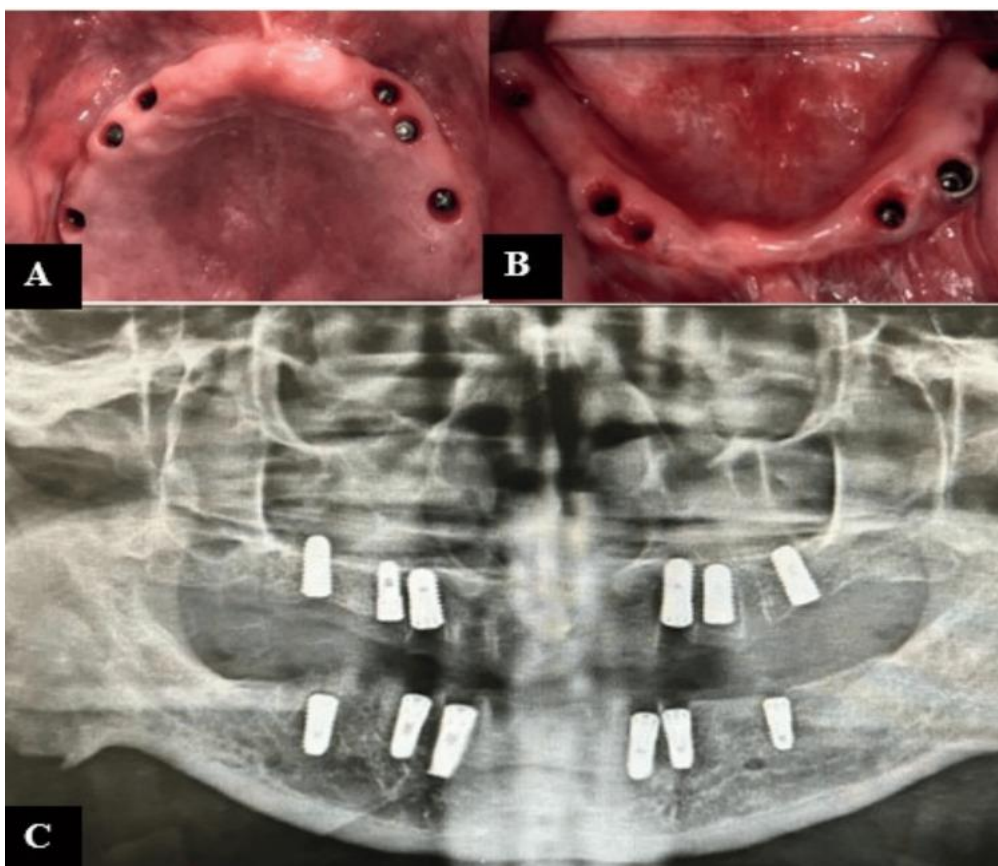
The All-on-6 technique requires an adequate quantity and quality of bone for implant placement. Patients suffering from severe bone loss, especially those who have lost their teeth for a long time, may need additional interventions, such as bone addition or sinus lifts, before they can benefit from this technique. These additional procedures add extra costs and recovery time [15-17].

Although the All-on-6 offers a stable and long-term solution, implant-fixed dentures require regular maintenance and rigorous oral hygiene. Patients must follow

a strict hygiene protocol, and check-ups with the dentist are essential to monitor the condition of the implants and prosthesis. If not properly maintained, problems such as peri-implantitis, an inflammation of the tissue around the implants, can occur that can compromise their stability [16-18].

#### The ideal candidate for All-on-6

The All-on-6 technique is an excellent solution for patients who want a complete restoration of their teeth, but not all patients are suitable candidates for this procedure. To ensure the success of the treatment, there are certain eligibility criteria that the patient must meet in terms of oral and general health [16-18].



**Fig 4.** (A) Maxillary arch (six implants); (B) mandibular arch (six implants); (C) post-operative radiograph [16].

The ideal candidate for All-on-6 is the person who has lost most or all of the

teeth in a dental arch, either due to periodontal disease or due to extensive

cavities or dental trauma. These patients can no longer benefit from conservative solutions, such as individual implants or traditional dental restoration treatments [16-18].

An essential factor for the success of the All-on-6 technique is the existence of a sufficient amount of bone in the jaw or mandible to allow the implants to be fixed. Although All-on-6 can also be applied to patients with moderate bone loss, a minimum volume of bone is required for proper implant fixation. In cases of severe bone loss, bone addition may be necessary, which prolongs and complicates treatment [15-17].

Like any surgery, the placement of All-on-6 implants involves certain risks, which is why the ideal candidate must be in a general state of good health. Patients with serious systemic conditions, such as uncontrolled diabetes, autoimmune diseases, or severe cardiovascular conditions, may be at higher risk of postoperative complications and implant osseointegration failure. Smokers are also more at risk of implant rejection due to tobacco's negative influence on bone and soft tissue healing [15-17].

The ideal candidate is the patient who wants fixed and stable teeth, compared to traditional mobile solutions. All-on-6 offers an aesthetic solution, which imitates natural teeth very well, and superior functionality, which allows patients to eat and talk without discomfort. It is an ideal option for those who want a long-term solution and are willing to invest in this type of treatment [17-19].

Another important criterion for the ideal candidate is availability and the ability to strictly adhere to all postoperative recommendations. This includes rigorous

oral hygiene, regular visits to the dentist for check-ups, and proper denture maintenance. Patients who cannot follow these recommendations are at risk of developing complications such as peri-implantitis, which can compromise the stability of implants [17-19].

### **Long-term results of the All-on-6 technique**

The All-on-6 technique is recognized for its long-term durability and effectiveness, providing patients with a fixed and aesthetic solution for complete tooth restoration. Long-term results depend on several factors, such as the quality of the implants, proper maintenance, and the overall health of the patient [18-20].

The dental implants used in the All-on-6 technique are made of titanium, a biocompatible material that, once integrated into the bone, can last for decades. With proper care and regular visits to the dentist, implants can remain stable and functional for a lifetime. In some cases, implant-attached dentures may require replacement or adjustment after 10-15 years, depending on wear and tear [20-26].

One of the main advantages of the All-on-6 technique is the stability it offers in the long term. Thanks to the osseointegration process, the implants become an integral part of the bone structure, providing a solid basis for the fixed prosthesis. This provides near-natural functionality, allowing patients to eat, talk, and smile confidently without fear of the denture moving or falling off [26-34].

In the long term, All-on-6 implants help maintain bone health by preventing bone resorption, a common problem in edentulous patients. The implants act as artificial roots that stimulate the jawbone,

maintaining its volume and density. This appearance helps preserve facial contouring and prevents the aging appearance associated with bone loss [3-21].

Long-term results depend largely on oral hygiene and regular maintenance of implants and dentures. Patients must follow a strict daily cleaning protocol and attend regular check-ups with the dentist. These controls allow the doctor to identify any problems in time and intervene before they affect the stability of the implants or the condition of the prosthesis, it is important to follow the indications of the biomaterials and possible innovation systems. [35-47].

Although the All-on-6 technique has a high degree of long-term success, there are potential risks, such as peri-implantitis (inflammation of the tissues around the implants) or failure of osseointegration. However, these complications are rare and can be largely prevented through good oral hygiene and regular check-ups [17,19,48-51].

### Conclusions

The All-on-6 procedure offers a stable and aesthetic solution for patients who have lost most of their teeth. By placing six well-positioned dental implants, patients benefit from a fixed denture that looks and functions like natural teeth. Although it involves surgery, this technique is preferred for its speed and efficiency,

reducing discomfort and providing long-lasting and quality results.

The All-on-6 technique offers a modern and effective solution for complete tooth restoration, but it comes with certain disadvantages that must be taken into account. High upfront costs, the need for surgery, and the risks associated with osseointegration and long-term maintenance are important factors to evaluate. Despite these challenges, for patients who are eligible and willing to invest in this solution, All-on-6 remains an excellent option for achieving stable and aesthetic teeth.

The ideal candidate for the All-on-6 technique is a person who has lost most of their teeth, has adequate general and oral health, and is looking for a permanent and aesthetic solution for tooth restoration. However, the success of treatment also depends on rigorous adherence to oral hygiene and postoperative recommendations. Thus, for patients who meet these criteria, All-on-6 offers a stable, durable and high-quality solution.

The All-on-6 technique offers excellent long-term results, providing patients with a stable, aesthetic and functional solution for tooth restoration. With proper maintenance and regular care, All-on-6 implants can last a lifetime, providing long-term comfort and confidence.

### References

1. Kwok V, Caton JG, Hart ID, Kim TS. Dental implant prognostication: A commentary. *J Periodontol.* 2023 Jun;94(6):713-721. doi: 10.1002/JPER.22-0196.
2. Minase DA, Sathe S, Bhoyar A, Apte A, Pathak A. Prosthetic Rehabilitation of All-on-Six Implant-Supported Prosthesis: A Case Report. *Cureus.* 2024 Jan 9;16(1):e51946. doi: 10.7759/cureus.51946.
3. Albaqawi AH. "All-on-4" and "All-on-6" treatment concept applied using computer-guided surgery in a patient: Case report with a 2-year follow-up. *Clin Case Rep.* 2023 Mar 14;11(3):e7101. doi: 10.1002/ccr3.7101.



4. Brånemark PI. Osseointegration and its experimental background. *J Prosthet Dent.* 1983 Sep;50(3):399-410. doi: 10.1016/s0022-3913(83)80101-2.
5. Gómez-Polo M, Ortega R, Gómez-Polo C, Martín C, Celemín A, Del Río J. Does Length, Diameter, or Bone Quality Affect Primary and Secondary Stability in Self-Tapping Dental Implants? *J Oral Maxillofac Surg.* 2016 Jul;74(7):1344-53. doi: 10.1016/j.joms.2016.03.011.
6. Thayyil Sivaraman Hrishi ,Government Dental College Calicut. Full Arch Implant rehabilitation using all on 6 concept -A Case series , March 2021, DOI:10.13140/RG.2.2.17088.66569
7. Cocoş DI, Bucur SM, Coman TM, Păcurar M. Observational study on the frequency of anchorage auxiliaries in fixed orthodontics, *Romanian Journal of Oral Rehabilitation* vol. 13, nr. 3,(iulie-septembrie) anul 2021.
8. Cocoş DI, Earar K, Bucur SM, Păcurar M, Mariş M, Cocoş ID, Galea C. Frequency of third molar pathology: innovative causes, symptoms and treatment options. *Romanian Journal of Oral Rehabilitation* Vol. 15, No.4 October-December 2023
9. Cocoş DI, Dumitriu Buzia O, Tatu AL, Dinu M, Nwabudike LC, Stefan CS, Earar K, Galea C. Challenges in Optimizing Nanoplatfoms Used for Local and Systemic Delivery in the Oral Cavity. *Pharmaceutics.* 2024; 16(5):626. <https://doi.org/10.3390/pharmaceutics16050626>
10. Costa RS, Santos PA, Nary HF, Brånemark PI. Key biomechanical characteristics of complete-arch fixed mandibular prostheses supported by three implants developed at P-I Brånemark Institute, Bauru. *Int J Oral Maxillofac Implants.* 2015 Nov-Dec;30(6):1400-4. doi: 10.11607/jomi.3944.
11. Park JC, Baek WS, Choi SH, Cho KS, Jung UW. Long-term outcomes of dental implants placed in elderly patients: a retrospective clinical and radiographic analysis. *Clin Oral Implants Res.* 2017 Feb;28(2):186-191. doi: 10.1111/clr.12780.
12. Marius Constantin Moraru ,Cătălin Buzdugă ,Irina Luciana Gurzu ,Vasile-Deniss Mereuta ,Elena Oana ,Ciurcanu ,Mihail Balan ,Edlibi Al ,Hage Walid ,Laura Iulia Bozomitu ,Alin Horatiu Nedelcu ,Mihaela Mitrea ,Mihaela Mitrea. The advantage of the all-on-six and all-on-eight technique compared to the all-on-four technique ,April 2024 ,DOI:10.6261/RJOR.2024.1.16.17
13. La Monaca G, Pranno N, Annibali S, Di Carlo S, Pompa G, Cristalli MP. Immediate flapless full-arch rehabilitation of edentulous jaws on 4 or 6 implants according to the prosthetic-driven planning and guided implant surgery: A retrospective study on clinical and radiographic outcomes up to 10 years of follow-up. *Clin Implant Dent Relat Res.* 2022 Dec;24(6):831-844. doi: 10.1111/cid.13134.
14. Lopes A, Maló P, de Araújo Nobre M, Sánchez-Fernández E, Gravito I. The NobelGuide® All-on-4® Treatment Concept for Rehabilitation of Edentulous Jaws: A Retrospective Report on the 7-Years Clinical and 5-Years Radiographic Outcomes. *Clin Implant Dent Relat Res.* 2017 Apr;19(2):233-244. doi: 10.1111/cid.12456.
15. Manfredini M, Poli PP, Maiorana C, Salina FE, Tandurella M, Beretta M. Computer Aided Full Arch Restoration by Means of One-Piece Implants and Stackable Guide: A Technical Note. *Dent J (Basel).* 2023 Nov 1;11(11):256. doi: 10.3390/dj11110256.
16. Beri A, Pisulkar SG, Bansod A, Rauniyar S, Jain R, Deshmukh S. Full Mouth Rehabilitation With All-on-Six Concept With Computer-Aided Design/Computer-Aided Manufacturing (CAD/CAM) Milled Bar Retained Zirconia Prosthesis. *Cureus.* 2024 Aug 22;16(8):e67465. doi: 10.7759/cureus.67465.
17. Poli PP, Manfredini M, Maiorana C, Salina FE, Beretta M. Correlation between Accuracy in Computer-Guided Implantology and Peri-Implant Tissue Stability: A Prospective Clinical and Radiological Pilot Study. *J Clin Med.* 2023 Aug 3;12(15):5098. doi: 10.3390/jcm12155098.
18. Azpiazu-Flores FX, Lee DJ, Jurado CA, Nurrohman H. 3D-Printed Overlay Template for Diagnosis and Planning Complete Arch Implant Prostheses. *Healthcare (Basel).* 2023 Apr 7;11(8):1062. doi: 10.3390/healthcare11081062.
19. Antohe, M.E. , Stamatina, O., Paval, D., Tibeica, A., Cretu, C. , Forna, N.C., Clinical-technological interactions of treatment in partially extended edentulousness,2022, *Romanian journal of oral rehabilitation* 14 (1) , pp.195-204Luca, L.
20. Ciubara, A.B., Antohe, M.E., Peterson, I., Ciubara, A., Social media addiction in adolescents and young adults - psychoeducational aspects, *Archiv Euromedica*, 2022, 12.

21. Bolat, M; Antohe, M and Forna, NC, Clinical aspects of therapeutical solutions involved in oral rehabilitation of partially edentulous patients, 2013, Romanian journal of oral rehabilitation 5 (4) , pp.75-81
22. Bansod A, Pisulkar SG, Beri A, Umre U, Jain R, Deshmukh S. Crafting Confidence: A Comprehensive Case Study of Full-Mouth Reconstruction Utilizing Implant-Supported Computer-Aided Design/Computer-Aided Manufacturing (CAD/CAM) Zirconia Restorations. *Cureus*. 2024 Jul 31;16(7):e65897. doi: 10.7759/cureus.65897.
23. Albaqawi AH. "All-on-4" and "All-on-6" treatment concept applied using computer-guided surgery in a patient: Case report with a 2-year follow-up. *Clin Case Rep*. 2023 Mar 14;11(3):e7101. doi: 10.1002/ccr3.7101.
24. Dinu M, Tatu AL, Cocoş DI, Nwabudike LC, Chirilov AM, Stefan CS, Earar K, Dumitriu Buzia O. Natural Sources of Therapeutic Agents Used in Skin Conditions. *Life*. 2024; 14(4):492. <https://doi.org/10.3390/life14040492>
25. Forna, N.C. and Sader, R., Oral rehabilitaion on small substance loss cases,2009,Romanian journal of oral rehabilitation, 1 (4) , pp.15-20
26. Cristea, I., Agop-Forna, D., Martu, M.A., Dascalu, C., Topoliceanu, C., Török, R., Török, B., Bardis, D., Bardi, P.M., Forna, N., Oral and Periodontal Risk Factors of Prosthetic Success for 3-Unit Natural Tooth-Supported Bridges versus Implant-Supported Fixed Dental Prostheses, *Diagnostic*, 2023 13 (5)
27. Vitalariu, A.M., Markomanolaki, CC, Chonta, I, Luca, O Tatarciuc, MS Dascalu, C.G., Study on teeth morphology variations among greek patients, Romanian journal of oral rehabilitation, 2017,9 (1) , pp.68-74
28. Galea C, Cocoş DI, Forna NC, Păcurar M, Earar K. Phytochemical study of the essential oil of pelargonium roseum by gas chromatographic method. *Romanian Journal of Oral Rehabilitation* Vol. 16, No.3 July-September 2024. DOI : 10.6261/RJOR.2024.3.16.65
29. Tüzes L, Cocoş DI, Szóts M, Bucur SM. Coronavirus prevention methods in dental practices *Romanian Journal of Oral Rehabilitation* Vol. 14, No.2 April-June 2022.
30. Decusara M, Cocoş DI, Caraiane A. Rehabilitation of agenesis 2.2 with pram involvement. case report. *medicine and materials* Volume 3, Issue 1, 2023: 23-30 | ISSN: 2784 – 1499 & e-ISSN: 2784 – 1537 DOI: 10.36868/Medmater.2023.03.01.023
31. Solomon O, Galea C, Feier R, Mostovei A. Actions of drosera sp in dentistry diseases. phitochemical components, pharmacological actions. *medicine and materials* Volume 3, Issue 1, 2023: 37-42 | ISSN: 2784 – 1499 & e-ISSN: 2784 – 1537 DOI: 10.36868/Medmater.2023.03.01.037
32. Galea C, Cocoş DI, Feier F, Moales D. The use of essential oils in the development of dermato-cosmetic products. *medicine and materials* Volume 3, Issue 1, 2023: 31-36 | ISSN: 2784 – 1499 & e-ISSN: 2784 – 1537 DOI: 10.36868/Medmater.2023.03.01.031
33. Baci D, Bujoreanu-Bezman L, Salcianu IA. Treatment of fractures performed with biomaterials in the arm and forearm. *Medicine and materials* Volume 4, Issue 1, 2024: 3-10 | ISSN: 2784 – 1499 & e-ISSN: 2784 – 1537 DOI: 10.36868/MEDMATER.2024.04.01.003.
34. Calin AM, Bratu IC, Dinu CA, Nechita A. Transmission of human immunodeficiency virus (hiv) from mother to fetus with implications in oral pathology. *Medicine and materials* Volume 4, Issue 1, 2024: 11-16 | ISSN: 2784 – 1499 & e-ISSN: 2784 – 1537 DOI: 10.36868/Medmater.2024.04.01.011.
35. Bida FC, Agop-Forna D, Bulancea BP, Balcoş C, Forna NC. An Observational Study on Oral Health and Quality of Life for RPD Wearers in the N-E Region of Romania. *Medicina (Kaunas)*. 2022 Sep 9;58(9):1247
36. Budală DG, Surlari Z, Baci R, Bolat M, Bida FC, Virvescu DI, Vasluianu RI. Does the use of an adhesive improve conventional complete dentures? -literature review. *Romanian Journal of Oral Rehabilitation*. 2022 July-August; 14(3):207-212
37. Budacu CC, Agop Forna D, Dimofte AR, Miulescu M. OMF versus migraine pain: similarities, differences, and realization of laser treatment. *MEDICINE AND MATERIALS* Volume 4, Issue 1, 2024: 17-24 | ISSN: 2784 – 1499 & e-ISSN: 2784 – 1537 DOI: 10.36868/MEDMATER.2024.04.01.017.

38. Tiutiuca C, Ceban E, Solomon O. Anatomy and pathology of the optic nerve. *MEDICINE AND MATERIALS* Volume 4, Issue 1, 2024: 25-32 | ISSN: 2784 – 1499 & e-ISSN: 2784 – 1537 DOI: 10.36868/MEDMATER.2024.04.01.025.
39. Feier R, Pacurar M, Cocos DI. materials used in fracture rehabilitation "e fort I, II and III". *Medicine and materials* Volume 4, Issue 1, 2024: 33-42 | ISSN: 2784 – 1499 & e-ISSN: 2784 – 1537 DOI: 10.36868/MEDMATER.2024.04.01.033
40. Diaconu-Popa, D., Vitalariu, A., Martu, I., Luchian, I., Luca, O., Tatarciuc, M Full dentures realization -conventional vs digital technologies, *Romanian journal of oral rehabilitation*, 2021,13 (4) , pp.160-173
41. Salcianu IA, Bratu AM, Bratu IC, Parvu S. Biomaterials used in heart valve substitution. *Medicine and materials* Volume 4, Issue 1, 2024: 43-50 | ISSN: 2784 – 1499 & e-ISSN: 2784 – 1537 DOI: 10.36868/Medmater.2024.04.01.043.
42. Ionuta G, Iulia Alecsandra S, Monica D, Ana Magdalena B. Comparative analysis of post-extraction alveoli healing with and without the application of platelet-rich fibrin. *Medicine and materials*. 2024: 61-68. DOI: 10.36868/MEDMATER.2024.04.02.061
43. Norina Consuela F, Raluca U, Irinel L, Alina-Ramona D. Dental ceramics: advantages and benefits. *Medicine and materials*. 2024: 69-76. DOI: 10.36868/MEDMATER. 2024.04.02.069
44. Gradinaru, I, Jipu, R, Hurjui, LL, Pendefunda, AAC, Armencia, A.O., Mitrea, M., Antohe, M.E., Current aspect of metal-ceramic-biomaterial restorations and technology, *Romanian journal of oral rehabilitation*, 2020, 12 (2) , pp.116-127
45. Iordache C, Antohe M-E, Chiriac R, Ancuța E, Țănculescu O, Ancuța C. Volumetric Cone Beam Computed Tomography for the Assessment of Oral Manifestations in Systemic Sclerosis: Data from an EUSTAR Cohort. *Journal of Clinical Medicine*. 2019;
46. Antohe, M.E. Madarati, M.Forna, N.C., Clinical-technological interactions of treatment in partially extended edentulousness, *Romanian journal of oral rehabilitation*, 2022, 14 (1) , pp.195-204
47. Dascalu, CG, Antohe, ME, Zegan, G., Burlea, SL, Carausu, EM, Ciubara, A, Purcarea, VL, Blended Learning - The Efficiency of Video Resources and YouTube in the Modern Dental Education, *Revista de cercetare si interventie sociala*, 2022, 72 , pp.288-310
48. Forna N.C., Dascalu C., Forna D., Antohe M.E., Incidence and prevalence of dental - periodontal conditions and edentation in Moldavia, *Medical-Surgical Journal-Revista Medico-Chirurgicala*, 2013,117 (1) , pp.205-211
49. Braescu, R., Tatarciuc, M., Luca, O., Giusca, SE, Caruntu, ID, A short history of the histological processing techniques for tooth and supporting hard tissues, *Medical-surgical journal-revista medico-chirurgicala*, 2020, 124 (1) , pp.134-140
50. Budală DG, Surlari Z, Bida FC, Ciocan-Pendefunda AA, Agop-Forna D. Digital instruments in dentistry-back to the future. *Romanian Journal of Oral Rehabilitation*. 2023 April-June; 15(2):310-318
51. Dioguardi M, Spirito F, Quarta C, Sovereto D, Basile E, Ballini A, Caloro GA, Troiano G, Lo Muzio L, Mastrangelo F. Guided Dental Implant Surgery: Systematic Review. *J Clin Med*. 2023 Feb 13;12(4):1490. doi: 10.3390/jcm12041490.