PREVALENCE AND ENDODONTIC MANAGEMENT OF SEPARATED INSTRUMENTS INSIDE THE ROOT CANAL

Cristina Coralia Nistor[1], Ana Maria Țâncu[2*], Elena Claudia Coculescu[3*], Albu Cristina Crenguța[4], Ștefan Milicescu[5], Bogdan Dimitriu[1]

[1]"Carol Davila" University of Medicine and Pharmacy, Bucharest, Faculty of Dental Medicine, Department of Endodontics
[2]"Carol Davila" University of Medicine and Pharmacy, Bucharest, Faculty of Dental Medicine, Department of Prosthodontics
[3]"Carol Davila" University of Medicine and Pharmacy, Bucharest, Faculty of Dental Medicine, Department of Oral Pathology
[4]"Carol Davila" University of Medicine and Pharmacy, Bucharest, Faculty of Dental Medicine, Department of Genetics
[5]"Carol Davila" University of Medicine and Pharmacy, Bucharest, Faculty of Dental Medicine, Department of Dental Aesthetics
*Corresponding authors: *e-mail*: anamaria.tancu@umfcd.ro; *e-mail*: elena-claudia.coculescu@umfcd.ro

ABSTRACT
Separated instruments represent one of the procedural mishaps during endodontic treatment. Left unadressed, this complex situation may jeopardize the long term prognosis of root canal treatment. Clinical management depends on multiple factors. The options for approaching these situations are: removal of the fractured segment, bypassing and sealing the fragment within the root canal space. The aim of our study is to demonstrates the value of endodontic treatment in the successful management of these conditions and its contribution to complex oral rehabilitation.

Keywords: separated instruments, removal, bypassing, endodontic management

INTRODUCTION

Various complications may occur during endodontic treatment. Intracanal file fracture, made of various materials, including nickel-titanium (NiTi), stainless steel and carbon steel, is one of the procedural errors that occurs during root canal treatment [1]. The reasons for this procedural erros are the excessive strain or instrument fatigue, as well as operators who are not fully trained, but this last one is the most important factor [2]. This emphasizes the attention we should pay to the adequate training process of the undergraduates and clinicians in order for them to be able to safely manage uncomplicated root canal treatments [3].

Prevalence of broken instruments ranges from 0.5%–5% [4,5,6]. In a study that investigated the incidence of hand and rotary instrument separation in the endodontics graduate program, there was an incidence of hand and rotary instruments fracture of 0.25% and 1.68%, respectively [7].

Fracture of endodontic instruments, although it is not frequently encountered in everyday practice, as it is the case with the ledges, for example, nevertheless, due to the possible consequences, it is an extremely anxious event for both the doctor and the patient and involves additional costs for the management of this situation, emotional/affective consumption for the doctor and sometimes also has medico-legal implications. Last but not least, the desire to remove the fractured fragment at any cost leads to the weakening of the root resistance, through the excessive removal of the root dentin tissue.

The presence of these fragments in the canal does not affect the prognosis of endodontic treatment [8], but the inability to debride the canal apical from the

DOI : 10.6261/RJOR.2024.1.16.7

fractured fragment. If this is possible, however, by by-passing it through various techniques, then it can be left in place and the root canal obturation will contain it. It is one of the happy situations, when the endodontic treatment is carried out along the entire length of the canal, without having to remove from the thickness of the dentin walls, and thus the resistance of the tooth to the vertical root fracture will not be affected. This technique is all the more valuable in the case of fractured files beyond the curvature, when there is no visibility necessary to remove them without affecting the thickness of the dentine.

The current endodontic techniques provides us with important means, which have a special contribution in solving these situations and make it possible to keep the tooth functional and asymptomatic through a successful endodontic treatment. Thus, the dental operating microscope, ultrasound, lasso-type grasping devices, cone-beam computed tomography (CBCT), are the main equipment that can be used to approach such a situation, in order to remove the fractured fragment. Equally important is the endodontist's skill and experience, which make the difference in difficult cases, but also the amount of tissue removed in case management.

If none of the previously mentioned solutions lead to a result, the fragment will be left in place, monitoring in this case will highlight the direction of evolution and if a subsequent treatment, such as surgery or extraction, is required.

MATERIAL AND METHOD

2208 CBCT-scanned teeth from a patient database registered in a private clinic were retrospectively analyzed. The scans were recommended for diagnostic purposes and to establish the treatment plan, either endodontically or surgically. The CBCT images were acquired with Veraviewepocs 3D P (R100) equipment (J. Morita MFG Corp., Kyoto, Japan). The scan parameters were 90 kV, 5 mA, 9.4 s exposure time, 125 µm spatial resolution and 40×40 mm field of view (FoV). The CBCT scan examination was performed by an endodontist with CBCT experience. The CBCT imaging assessment methodology involved orienting the long axis of the tooth under examination with the reference lines within the visualization software, followed by an anatomical interpretation performed across the coronal, sagittal and axial planes.

RESULTS

Out of these teeth, 752 had previous endodontic treatment. There was a prevalence of 2.65% (n=20) for fractured instruments visible on CBCT scans.

CLINICAL CASES

Clinical case 1

A 38-year-old male patient was referred to our endodontic office for retreatment of his mandibular right first molar. The patient was in good general health. The tooth was tender to percussion at clinical examination, periodontal probing was within normal limits, with no mobility.

The preoperative radiograph (fig. 1a) showed a previous incomplete root canal treatment, and a 3 mm fragment of a file in a mesial root canal, in the middle third and normal periradicular tissues. All the filling materials were removed and we had to obtain a straight-line access to the fragment so that the coronal portion of the separated file could be visualized with the aid of a dental operating microscope. The separated instrument was removed with ultrasonics (fig. 1b) and the root canals were prepared with the Rotate rotary files (VDW GmbH, Munich, Germany) and obturated with AH Plus sealer (Dentsply Sirona) and warm

DOI : 10.6261/RJOR.2024.1.16.7

vertical compaction of the gutta-percha, using B&L (Biotech USA, Inc) (fig. 1c).

The patient returned to the referring dentist for the final restoration.



Figure 1a. Preoperative radiograph b. Radiograph after the removal of the fragment c. Postoperative radiograph

Clinical case 2

A 42-year-old female patient was referred to our office for the treatment of tooth 23. The referral dentist reported that he broke a rotary file inside the root canal, when performing a root canal treatment for this tooth, which was an abuttment for an extensive bridge. The tooth had no detectable mobility and the periodontal probing was within normal limits. A preoperative radiograph (fig. 2a) revealed approximately 15 mm of a separated file in the apical third of the root canal, with no periapical radiolucency. The tooth was completely asyptomatic.

The coronal portion of the separated file was visualized under the microscope. The separated file was successfully removed (fig. 2b) in 5 min using the BTR Pen file removal device (Cerkamed). The treatment was completed similar as case (fig. 2c).The patient returned to the referring dentist for the final restoration.

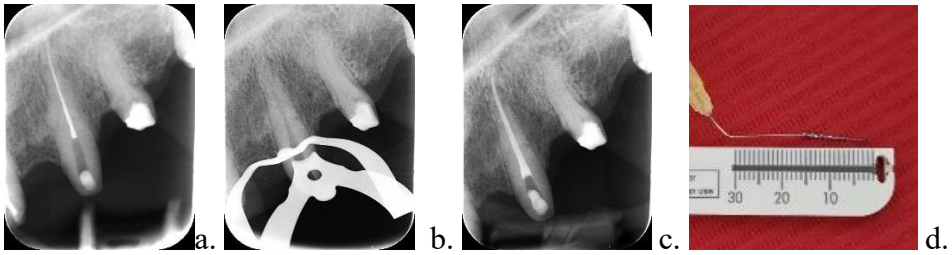

Figure 2 a. Preoperative radiograph b. Radiograph after the removal of the broken file c. Postoperative radiograph d. The retrieved fragment

Clinical case 3

A 22-year-old female was referred to our endodontic office for the retreatment of the right mandibular first molar. The patient reported that a year ago this tooth had to be endodontically treated. The tooth had to be restored with a crown due to the extensive caries and it was decided for a retreatment. and since then it remained slightly chewing sensitive. Clinical examination revealed that this tooth was sensitive to percussion. The periodontal probing was within normal limits A preoperative radiograph (fig. 3a) revealed approximately 3 mm of a separated file in the apical third of one of the mesial canals. There was a periapical radiolucency around the mesial root. The canals were underfilled. The patient did not wish for the retreatment of the distal canal and she insisted for the fragment be not retrieved, but instead by-passed, as she was informed that the removal implies the removal of some tooth structure. We decided to take a CBCT scan to further evaluate the tooh. The CBCT scan confirmed (fig. 3b) that the distal root

DOI : 10.6261/RJOR.2024.1.16.7

presented no periapical pathosis as yet and upon clinical evaluation under the scope, it could be left unretreated. As for the mesial root, the file was identified in the mesio-lingual canal. There was some space around the file and also the root canal was visible beyond the previous treatment. Gutta-percha root filling in the mesial canals was removed by rotary NiTi instrumentation without solvent. The by-bassing was successful and the treatment completed as in previous cases, the file being incorporated as part of the filling material (fig. 3c). The patient returned to the referring dentist for the final restoration.

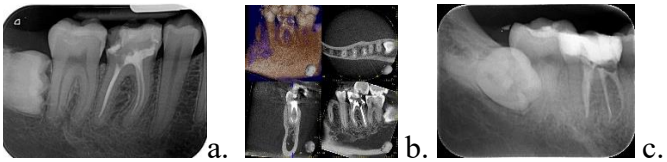

Figure 3 a. Preoperative radiograph b. CBCT scan c. Postoperative radiograph

Clinical case 4

A healthy 27-year-old female patient was reffered to our endodontic office for the treatment of tooth 47. The referral dentist mentioned that it had a separated file inside the mesial root and he had send the patient to another endodontist to remove the file. The file-removal attempt was not successful. Upon examining the radiograph send to us by the general dentist (fig. 4a), which was a preoperative radiograph, we decided to scan the patient, as the mesial root presented an abrupt curvature and the Lentullo spiral file was beyond the curvature. It was also a long, 7 mm fragment in the apical third of the canal. The distal canal presented a root canal filling. The distal root was associated with a periapical radiolucency. The CBCT revealed (fig. 4b) a perforation of the mesial root, due to the previous attempt to remove the file. Clinical examination revealed that the tooth presented an extensive tooth structure loss and was slightly sensitive to percussion. The periodontal probing was within normal limits. Upon access, the separated file was immediately visible under the microscope, as well as the root perforation. No preparation for the file removal was made with ultrasonic tips because the coronal portion of the canal was already overzealously enlarged. The separated file was initially resistant to the pulling motion of a micro-opener device, but it was finally removed (fig. 4c). The preparation of the canals was completed as in previous cases. The perforation was closed with gray MTA (Angelus) (fig. 4d). The patient was sent back to the referring dentist for a full coverage crown.

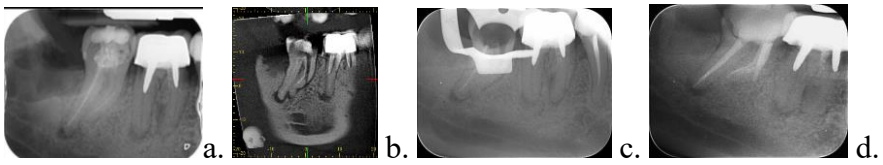

Figure 4 a. Preoperative radiograph b. CBCT scan, sagittal plane c. Radiograph after the ramoval of the file d. Postoperative radiograph

DOI : 10.6261/RJOR.2024.1.16.7

DISCUSSION

The approach of cases with fractured instruments depends on several factors, and the treatment options are: removal of the fractured segment, bypassing and sealing the fragment within the root canal space [9]. These factors are: their location, their visibility under the dental operating microscope, the shape and caliber of the canal around these fragments, the type of file (steel, Ni-ti, Lentullo), the length of the fragment, the technical equipment of the office, the skill of the doctor. In addition to these, the time when the incident occurred during the endodontic treatment, the strategic importance of the tooth in the context of the treatment plan and the presence or absence of chronic apical periodontitis should also be considered [10]. However, this last factor is reported to be the main prognostic aspect [11].

The least invasive technique is that of bypassing the fragment. Sometimes this operation is quite easy, if the fragment is of small diameter or the canal is wider. Other times, however, it is necessary to create space next to the fragment in order to reach it apically. In this case, the skill and experience of the doctor come into play as important success factors, otherwise a false path and the consequent perforation of the root can be created if we do not understand the information received through those manuals files with which we are trying to by-pass. By-passing the separated files and embedding them in the canal obturation mass does not affect the subsequent prognosis of the tooth, it is more important to ensure a tight coronal seal and clean the canal apical of the fragment [12].

More recently, it was described a new approach by using digital implantology software; in this way, a guide was constructed with a tube to guide a trephine and achieve straight-line access to the separated file. This static guided endodontic technique avoids excessive loss of dental structure and simplifies the procedure by reducing chair time and increasing the operator's confidence [13]. However, there are some serious limitations of this procedure, as it can be performed only on the straight portions of the root canals, it requires more time and costs for the patient. In addition, the limited space in the posterior region is also a limitation for this technique [14].

Sometimes we are also faced with frustrating situations when after removing the separated fragment, more or less easily, the canal is blocked or calcified and we do not succeed in negotiating it up to the apex. In such cases, the treatment options are either filling the root canal up to the separated file and then monitoring or surgical approach if the situation allows it.

Long fragments can only be removed by grasping. Fortunately, now there are many types of such devices on the market, such as loops, with wire of different materials and diameters, to cover a multitude of situations. They involve minimal removal of dental tissue, are safe and can cover a multitude of clinical situations [15].

Most situations are resolved with the help of ultrasonic techniques, assisted by the dental operating microscope, when at least part of the fractured instrument is in the straight portion of the root canal [16]. However, orthograde removal of separated instruments is considered quite difficult, time consuming and with a quite variable success rate [17].

The empirical attempt to apply this technique when the fragment is beyond the curvature, leads to perforations and seriously affecting the prognosis of the tooth in question. Other complications can be represented by the formation of ledges, especially in the case of curved canals, or

DOI : 10.6261/RJOR.2024.1.16.7

undermining the strength of the root walls by thinning the dentin layer [18]. There is a study that showed that canal enlargement of 40 to 50% of the root width increased susceptibility to vertical fracture [19].

Despite the technical diversity currently available in endodontics, the removal of fractured files is not always predictable, but depends on the techniques used in complex cases. Sometimes it can be a simple and quick work, other times it can cause serious complications, compromising the future of the tooth. Furthermore, there is no standard procedure in the endodontic literature for the safe removal of separated instruments [20].

CONCLUSIONS

Fractured instruments hinders cleaning and shaping of the root canal system and jeopardizes the prognostic of the root canal treatment.

Our clinical cases show different methods for managing cases with broken files, by removing or bypassing them.

CBCT and dental operating microscope are important tools for a successful management of these situations.

By recovering these teeth, otherwise with a poor prognosis, our study shows the value of endodontic treatment in complex oral rehabilitation.

REFERENCES

1. Parashos P, Messer HH. Rotary NiTi instrument fracture and its consequences. J Endod. 2006 Nov;32(11):1031-43. doi: 10.1016/j.joen.2006.06.008. PMID: 17055902.
2. Sonntag D, Delschen S, Stachniss V. Root-canal shaping with manual and rotary Ni-Ti files performed by students. Int Endod J. 2003 Nov;36(11):715-23. doi: 10.1046/j.1365-2591.2003.00703.x. PMID: 14641434.
3. Davey J, Bryant ST, Dummer PM. The confidence of undergraduate dental students when performing root canal treatment and their perception of the quality of endodontic education. Eur J Dent Educ. 2015 Nov;19(4):229-34. doi: 10.1111/eje.12130. Epub 2014 Dec 9. PMID: 25490882..
4. Abu-Tahun I, Al-Rabab'ah MA, Hammad M, Khraisat A. Technical quality of root canal treatment of posterior teeth after rotary or hand preparation by fifth year undergraduate students, The University of Jordan. Aust Endod J. 2014 Dec;40(3):123-30. doi: 10.1111/aej.12069. Epub 2014 Sep 4. PMID: 25197021
5. Eskibağlar M, Özata MY, Ocak MS, Öztekin F. Investigation of fracture prevalence of instruments used in root canal treatments at a faculty of dentistry: a prospective study. Restor Dent Endod. 2023 Nov 1;48(4):e38. doi: 10.5395/rde.2023.48.e38. PMID: 38053782; PMCID: PMC10695725
6. Fu M, Zhang Z, Hou B. Removal of broken files from root canals by using ultrasonic techniques combined with dental microscope: a retrospective analysis of treatment outcome. J Endod. 2011 May;37(5):619-22. doi: 10.1016/j.joen.2011.02.016. PMID: 21496659.
7. Iqbal MK, Kohli MR, Kim JS. A retrospective clinical study of incidence of root canal instrument separation in an endodontics graduate program: a PennEndo database study. J Endod. 2006 Nov;32(11):1048-52. doi: 10.1016/j.joen.2006.03.001. Epub 2006 Sep 25. PMID: 17055904..
8. Spili P, Parashos P, Messer HH. The impact of instrument fracture on outcome of endodontic treatment. J Endod. 2005 Dec;31(12):845-50. doi: 10.1097/01.don.0000164127.62864.7c. PMID: 16306815

DOI : 10.6261/RJOR.2024.1.16.7

9. Vivekananda Pai AR, Mir S, Jain R. Retrieval of a metallic obstruction from the root canal of a premolar using Masserann technique. Contemp Clin Dent. 2013 Oct;4(4):543-6. doi: 10.4103/0976-237X.123069. PMID: 24403807; PMCID: PMC3883342
10. Madarati AA, Hunter MJ, Dummer PM. Management of intracanal separated instruments. J Endod. 2013 May;39(5):569-81. doi: 10.1016/j.joen.2012.12.033. Epub 2013 Mar 15. PMID: 23611371.
11. Cujé J, Bargholz C, Hülsmann M. The outcome of retained instrument removal in a specialist practice. Int Endod J. 2010 Jul;43(7):545-54. doi: 10.1111/j.1365-2591.2009.01652.x. Epub 2010 May 4. PMID: 20456518.
12. Saunders JL, Eleazer PD, Zhang P, Michalek S. Effect of a separated instrument on bacterial penetration of obturated root canals. J Endod. 2004 Mar;30(3):177-9. doi: 10.1097/00004770-200403000-00012. PMID: 15055438
13. Bordone A, Ciaschetti M, Perez C, Couvrechel C. Guided Endodontics in the Management of Intracanal Separated Instruments: A Case Report. J Contemp Dent Pract. 2022 Aug 1;23(8):853-856. doi: 10.5005/jp-journals-10024-3395. PMID: 37283022.
14. Connert T, Weiger R, Krastl G. Present status and future directions - Guided endodontics. Int Endod J. 2022 Oct;55 Suppl 4(Suppl 4):995-1002. doi: 10.1111/iej.13687. Epub 2022 Feb 4. PMID: 35075661; PMCID: PMC9790195.
15. Terauchi Y, O'Leary L, Suda H. Removal of separated files from root canals with a new file-removal system: Case reports. J Endod. 2006 Aug;32(8):789-97. doi: 10.1016/j.joen.2005.12.009. Epub 2006 Jun 6. PMID: 16861084.
16. Ward JR, Parashos P, Messer HH. Evaluation of an ultrasonic technique to remove fractured rotary nickel-titanium endodontic instruments from root canals: an experimental study. J Endod. 2003 Nov;29(11):756-63. doi: 10.1097/00004770-200311000-00017. PMID: 14651285.
17. Alomairy KH. Evaluating two techniques on removal of fractured rotary nickel-titanium endodontic instruments from root canals: an in vitro study. J Endod. 2009 Apr;35(4):559-62. doi: 10.1016/j.joen.2008.12.019. PMID: 19345805.
18. Souter NJ, Messer HH. Complications associated with fractured file removal using an ultrasonic technique. J Endod. 2005 Jun;31(6):450-2. doi: 10.1097/01.don.0000148148.98255.15. PMID: 15917685
19. Wilcox LR, Roskelley C, Sutton T. The relationship of root canal enlargement to finger-spreader induced vertical root fracture. J Endod. 1997 Aug;23(8):533-4. doi: 10.1016/S0099-2399(97)80316-0. PMID: 9587326.
20. Malentacca A, Zaccheo F, Rupe C, Lajolo C. Endodontic Clinical Outcome after Separated Instrument Removal Using a Spinal Needle Technique: A Retrospective Study of Thirty Years of Clinical Experience. J Endod. 2023 Aug;49(8):980-989. doi: 10.1016/j.joen.2023.06.007. Epub 2023 Jul 7. PMID: 37422250.

DOI : 10.6261/RJOR.2024.1.16.7