NEW APPROACHES TO LASER TREATMENT FOR ORAL PERI-IMPLANT MUCOSITIS

Codruta Elena Ciurescu[1], Lorena Dima[1], Vlad Alexandru Ciurescu[2], Marius Alexandru Moga[3], Marius Traian Leretter[4*], Laura-Cristina Rusu[5], Codruta Victoria Tigmeanu[5]

[1] Department of Fundamental Disciplines and Clinical Prevention, "Transylvania" University of Brasov, Faculty of Medicine Brasov, 56 Nicolae Balcescu Str., 500019 Brasov, Romania ;
[2] "Iuliu Hatieganu" University of Medicine and Pharmacy, Faculty of Dental Medicine, 8 Victor Babes Str., 400012 Cluj-Napoca, Romania;
[3] Department of Medical and Surgical Specialities, "Transylvania" University of Brasov, Faculty of Medicine, 56 Nicolae Balcescu Str., 500019 Brasov Romania;
[4] Department of Prosthodontics, Multidisciplinary Center for Research, Evaluation, Diagnosis and Therapies in Oral Medicine, "Victor Babeș" University of Medicine and Pharmacy Timisoara, 2 Eftimie Murgu Sq., 300041, Timisoara, Romania;
[5] Department of Oral Pathology, Multidisciplinary Center for Research, Evaluation, Diagnosis and Therapies in Oral Medicine, "Victor Babes" University of Medicine and Pharmacy Timisoara, 2 Eftimie Murgu Sq., 300041 Timisoara, Romania;
[6] Department of Technology of Materials and Devices in Dental Medicine, Multidisciplinary Center for Research, Evaluation, Diagnosis and Therapies in Oral Medicine, "Victor Babes" University of Medicine and Pharmacy Timisoara, 2 Eftimie Murgu Sq., 300041, Timisoara, Romania.

Corresponding author; *e-mail:* mariusleretter@yahoo.com

ABSTRACT

Aim of the study The objective of this study is to examine the impact of treatment with two simultaneous lasers on implant mucositis. **Material and methods** A number of 40 patients (90 implants) were included in this research. They were allocated randomly in 2 groups. **Results** Both variables as Pocket depth around implants (if diminished under 6 mm of depth) and the absence of clinical signs of inflammation by means the absence of measured bleeding on probing at 6 months after performing the treatment were evaluated together as parameters evaluating the success of the performed treatment, and significantly better results were observed in first group of subjects at their evaluation.

Key words: Er,Cr: YSGG laser, mucositis, dental implant, InGaAsP

INTRODUCTION

A dental implant is a popular treatment solution for a missing tooth or teeth, with certain advantages over conventional fixed partial dentures [1]. Despite the fact that nowadays implant supported prosthesis have shown a high survival rate comparing to traditional dental supported prosthesis, still a high prevalence of implant inflammatory complications is occurring [2]. Due to specific physiopathological conditions peri-implant tissues are more susceptible to bacterial challenge that might lead to inflammatory complications and future implant loose [3].

The implant inflammatory complications are classified as peri-implant mucositis and peri-implantitis, as defined in the 2017 World Workshop of the American Academy of Periodontology and European Federation of Periodontology [4].

Peri-implant mucositis lesion is distinctly identified by the presence of an inflammatory cell infiltrate within the connective tissue lateral to the barrier epithelium [5].

Peri-implant mucositis refers to the complications associated with the

DOI : 10.62610/RJOR.2024.1.16.1

accumulation of plaque around the implant [6] and characterized by bleeding on gentle probing, and often associated with puss, increased probing depth around implant, discreet pain on probing and aspect modification of the surrounding soft tissue around implants as redness and swelling [7]. According to WWCP classification peri-implantitis follows mucositis with subsequential bone loss around implant as consequence of inflammation and constant bacterial challenge around implants [8]. Clinical signs of peri-implantitis are common with the ones described for mucositis and but the X-ray examination evidence bone lose around implants that overcame the accepted bone remodeling after prosthetic delivery [9].

Peri-implantitis is an infection around dental implants, that can cause pain and discomfort for patients. The pain can vary in severity and affect the patient's quality of life [10]. Without proper intervention both peri-implant inflammatory diseases will evolve in progressive bone loss around implant will end with the loos of the implant itself [11].

Conventional non-surgical mechanical therapy is currently the most common widely accepted treatment for peri-implant mucositis [12]. There is not enough evidence to support the use of additional chemical or mechanical agents in improving clinical and microbiological outcomes [13].

In a study published in 2020, the researchers suggests that clinicians should use soft tissue grafting to create a thick, keratinized, and attached peri-implant tissue when necessary. This will help protect the underlying crestal bone and make it easier to remove plaque [14].

Chlorhexidine mouthwash is commonly used by oral health care professionals and the general public to reduce bacteria in the mouth and prevent oral diseases [15]. It is considered one of the most widely used antimicrobial agents for this purpose [16]. The local use of chlorhexidine does not have a significant effect on treatment outcome [17]. Peri-implantitis are proposed to be treated by surgical intervention but the result may vary depending on the clinical conditions and to the surgical protocol and method of decontaminate the implant that was used can still be resolved through surgical treatment without the use of antimicrobial agents, and the results may vary depending on the characteristics of the implant surface [18]. Chlorhexidine can cause cell cytotoxicity, which can prevent the implants from integrating properly and lead to failure [19]. It is advised to avoid using chlorhexidine in cases of peri-implantitis and use alternative antimicrobial agents instead [20].

As treatment for peri-implant inflammatory complications even though several treatment protocols have been proposed with: air powered abrasive powder (glycine, Perio-Flow), citric acid, ultrasonic or manual plastic curettes, titanium curettes, titanium brushes, several antiseptics, most of them failed to achieve a complete elimination of the bacteria from the implant site [21]. Some of these methods ended by damaging the implant surface or charging the soft tissue with titanium particles [22].

Due to their special characteristic's lasers appear to be the next player on the scene. Each laser came with its own treatment benefits according to their special laser tissue interaction that came from the specific wavelength and specific dosage. Sometime combination of different lasers has been considered to increase the patient clinical benefit from 2 complementary lasers, with 2 laser tissue specific interactions [23], [24], [25].

DOI : 10.62610/RJOR.2024.1.16.1

Er,Cr: YSGG laser (as part of the Erbium lasers group) is known for a verry delicate curettage performed on the soft tissue, with a penetration depth up to 24 microns due to the content in water of the soft tissue, delicate and efficient curettage of the surrounding bone without damaging it and more than that it has proven an efficient cleaning, conditioning and decontaminating properties on the surface of the implant without damaging it if proper dosage have been used. Implant surfaces treated with Er,Cr: YSGG are restored their wettability, is free from cell debris, contaminants and toxins. Er,Cr: YSGG is known for its antibacterial effect independent of the characteristics of bacteria due to the fact that is efficiency is related to the water content of living cells (by means bacteria but not exclusively) [26]. The antibacterial effect is extended to all human tissue that the laser is firing together with a delicate removal of 1-2 cell layers of the fired tissue [27].

The second laser that have been proposed in this study is InGaAsP 940 nm, that has melanin and hemoglobin as chromophore. The laser bacterial reduction protocol for 940 nm laser is conducted on non-contact mode with a non-initiated tip to avoid any risk of damage of the implant surface. Dosage was calculated in order not to overheat the surrounding tissue. The fired laser of 940 nm wavelength has proven an efficient penetration in difficult anatomical area as furcations, denticule, and it is targeting all pigment bacteria that are in the laser is fired, with a penetration depth that my attend several microns up to 1 mm. Overheating is avoided by calculating the proper dosage and adding cooling water to the procedure.

It is important to figure out the best way to use lasers without causing harm to the implant and surrounding tissues. More research is needed to understand how lasers affect different types of implant surfaces [27].

The use of a diode laser as an additional treatment alongside conventional mechanical debridement was found to be effective in reducing inflammation in clinical studies [28]. However, there was no significant difference in terms of reducing pocket depth and bleeding on probing compared to mechanical debridement alone [29]. The efficacy of diode laser as an implant decontamination tool may have been influenced using different laser settings in the included studies. The frequency and timing of laser application varied: between 1 to 3 applications with different timing from 30 and 60 seconds [30]. It is believed that a single application may not be enough to maintain the anti-inflammatory effect. However, repeating the laser application three times did not result in significant improvements in periodontal parameters in another study [31].

The amount of published articles on decontaminating implant surface with laser mucositis and peri-implantitis laser treatment are using vary protocols and vary laser parameters from energy dose under the threshold of laser tissue efficient interaction up to dosages that overheat and lead to local thermal damage [32],[33],[34].

MATERIAL AND METHODS

The purpose of this research is to evaluate the potential of 2 complementary lasers in reducing bacterial charge and subsequently reducing inflammation signs around implants diagnosed with mucositis and to compare its efficiency to a widely accepted treatment as air powered abrasive using glycine powder and chlorhexidine.

A number of 40 patients (90 implants) (Table 1) were included in this research. Inclusion criteria: subjects within the age 30-

DOI : 10.62610/RJOR.2024.1.16.1

75 years, wearing one or more dental implants (Figure 1, Figure 4), both genders (Figure 2)

Table 1. Demographic and clinical characteristics of batches.

prosthetically loaded from more than 12 months that have exhibits bleeding on probing/ puss at a gentle probing around implants.

All the participants signed an informed consent before inclusion in the study. The study was conducted in accordance with the Declaration of Helsinki, and the study protocol was approved by the Ethics Committee of "Transylvania" University of Brasov and "Krondent" Dental Clinic (Project identification code 101E).

Variable/Implant		Lot C	Lot T	P
Age (years)Subjects		55±10.5	53.2±10	
Age I implants		7.1±2.8	7.7±3.5	
Implant	Y	16 (34%)	13 (26%)	
	O	31 (66%)	36 (74%)	
Gender Subjects	F	26 (61.9%)	24 (50%)	
	M	16 (38.1%)	24 (50%)	
Implant plaque score (initial)		0.1603±0.27	0.1585±0.235	0.972
KM/NKM	NKM	18 (38.3%)	32 (63%)	
	KM	29 (61.7%)	17 (37%)	
Implant topography	FS	3 (6.3%)	8 (16%)	
	LI	11 (23.40%)	28 (57%)	
	LS	33 (70.2%)	12 (24%)	
Smoking	No	30 (63.8%)	27 (55%)	
	Yes	17 (35.2%)	22 (45%)	
Periodontitis (history of)	No	18 (38.3%)	-	
	Yes	29 (61.7%)	49 (100%)	
RBL baseline		2.1434±1.138	1.3765±0.802	<0.001

They were allocated randomly in 2 groups.

Exclusion criteria: subjects (male and female) below 30 years and over 75 years, subjects that had been thru antibiotic therapy in the last 3 months, subjects with obesity, diabetes mellitus, tuberculosis, AIDS, any immune therapy, autoimmune disease conditions, oncologic disease, radiation therapy, psychiatric therapy.

Subjects have been randomly allocated in 2 groups following a computer randomisation list (Fig3) (Fig 5).

DOI : 10.62610/RJOR.2024.1.16.1

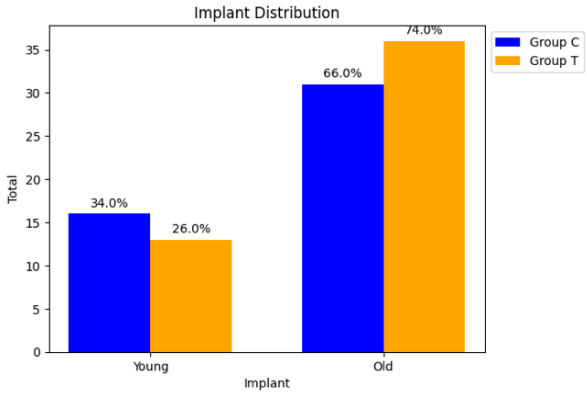

Figure 1. Graphic depicting the distribution of implant oldness (young or old) between the two groups + comparison.

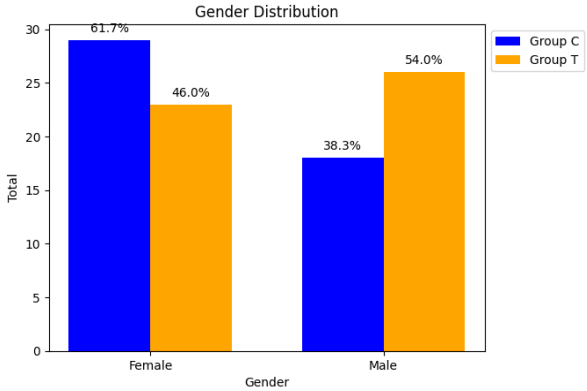

Figure 2. Graphic depicting the distribution of the patient's gender between the two groups + comparison.

Figure 3. Graphic depicting the distribution of keratinized mucosa/ nonkeratinized mucosa between the two groups + comparison.

DOI : 10.62610/RJOR.2024.1.16.1

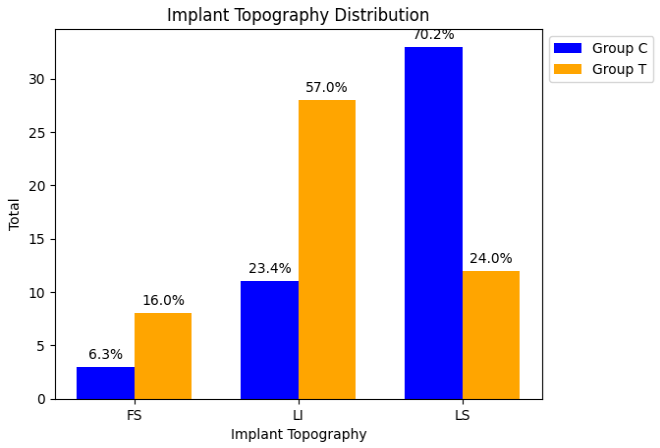

Figure 4. Graphic depicting the distribution of the implant's type between the two groups + comparison.

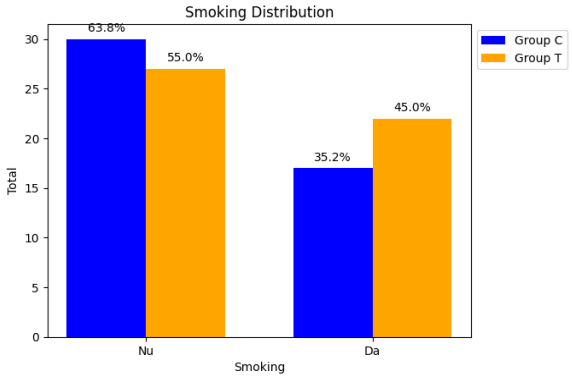

Figure 5. Graphic depicting the distribution smokers/non-smokers between the two groups + comparison.

All subjects underwent clinical examination, anamnesis, radiographic examination. Baseline parameters were recorded as follows: Probing depth around implants was performed in 6 points: mesio-buccal (MB), buccal(B), disto-buccal (DB), mesio-oral (MO), oral (O), disto-oral (DO) and the depth of the implant pocket was noted using Periodontal Probe 155mm Colombia (PCP). At radiographic examination was measured the level of marginal bone around implant shoulder (RBL). If the value exceeded 1.5 mm, accepted as bone remodelling after prosthetic delivery, the implant was excluded from this research.

Bleeding on probing was also noted at the same sites probing depth was measured. The amount of plaque around implants was also evaluated and all patients were instructed in performed a good oral hygiene.

In the second visit according to the randomisation subjects underwent clinical treatment as follows:

First group, second visit: *supragingival scaling* and supragingival air polishing.

Third visit: *laser bacterial reduction protocol* using 940 nm InGaAsP laser at 1.5 W, continuous wave (CW), 300 microns non initiated tip 9mm tip, for 30 seconds on the oral and 30 seconds on the buccal area. Laser tip was placed into the pocket and retracted 1mm from the bottom of the pocket, and slightly moved coronally with ovoidal drowning, at of the internal surface of the pocket to cover all area with the fired laser.

Water spray was used in the working area in order to avoid over heating of the tissue and initiation of the tip due to contact with blood. If by accident laser tip was initiated was immediately replaced with a new one. Er,Cr:YSGG laser was use afterwords for

DOI : 10.62610/RJOR.2024.1.16.1

curettage and cleaning inside the implant pocket was used as follows : 1.5W, 30 Hz, 60 microns pulse settings, RFTP (radial firing glass tip) at a length of 14 mm was used and SFT (SIDE FIRRING TIP glass fiber) was used to complete the treatment in the " blinds spots" by means underneath the implants threads.

Laser tip was placed into the sulcus of the implant and retracted 1 mm from the bottom. Laser was fired while ovoidal movement were performed at a speed of 2mm per second in order to draw all implant surface that was accessible due to the fact that laser tip can not be bended, all the internal side of the pocket either bone or soft tissue, oral and buccal, mesial and distal and the procedure was finished by a delicate deepithesation of the external side of the implant pocket in order to delay epithelial growth inside the implant pocket.

For the second group, *ultrasonic supragingival cleaning*, supragingival air polishing was performed also in the second visit.

In the third visit *Perioflow using glycine powder was performed* (EMS, Chemin de la Vuarpillière, Nyon). Chlorhexidine 0.2% was used vigorously during the curettage and at the end to finally clean the implant pocket and eliminate powder from the implant pocket and chlorhexidine gel (CHX) 1% gel Curasept (Curaden, Kriens, Switzerland) was applied.

All patients were instructed to keep a good oral hygiene.

After 3, 6 months, data were collected in 6 sites MB, B, DB, MO, O, DO.

All collected data were compared to the initials. Statistics was performed using SPSS program and T statistic test.

Enrolllement: Subject wearing implants that presented theirself to the clinic for 6 months check-up starting june 2021 were evaluated. If they were exhibiting bleeding on probing at the consultation or puss on probing they were invited to join the study.

Retroalveolar xray was performed at the first appointment in order to evaluate the bone loss around implants. Periimplant pocket depth was recorded, bleeding /puss on probing was recorded and the status of oral hygiene(ohi).

Subjects were devided in 2 groups according to a random allocation. Subjects that exhibit bone loss over the standard remodeling bone

The 2 groups were laser group and control group (antiseptic group)

Baseline parameters were recorded as: periimplant pocket depth in 6 points: mesiobuccal, buccal, distobuccal, mesiooral, oral, distooral using a periodontal probe in the same points bleeding on probing was recorded. Same parameters were recorded 3 months and 6 months later.

Treatment: In laser group supragingival scaling followed by air polishing was performed and oral hygiene instructions were reinforced follower by laser treatment as follows : laser bacterial reduction protocol using InGaAsP 940 nm laser (Biolase Epic X) 1.5W cw 30 sec vestibular 30 sec oral 300 microns non initiated tip (blue ferrule) 9 mm lenght, by drawing the inside wall of the periimplant pocket keeping carefully not to touch the surface of the implant or the abutment. The laser treatment was performed after washing out the blood inside the sulcus and drying the gingival margins around the implant. Care was taken not to overheat the implant surface and the sorrounding bone by calculating the proper dossage and using additionally waterspray for cooling and washing out additional bood that my eventually be present in the periimplant pocket. Next step was to performe complemetarry laser treatment using Er,Cr:YSGG laser Iplus (Biolase, Waterlase) 1.5W, 30 Hz, 60 microseconds pulse duration, air 40-55%, water 50-70% according to the depth of the periimplant pocket and location of implant. Radial firring tip 500 microns glass fiber RFTP 14

DOI : 10.62610/RJOR.2024.1.16.1

mm was used to performe the delicate curretage on the inside of the periiplant pocket, and cleaning/ conditioning the implant surface by using spiralar movements. Tip was introduced at the bottom of the pocket and retracted 1 mm then laser was fired. Care was taken to avoid contact between the top of the tip and the implant surface or the bone. Cleaning and conditioning the implant surface and the abuttment surface was completed using the SFT – side firring tip, using the same laser parameters in order to capture the underneath part of the implant theads.

In the Control group supragingival scaling was also performed folowed by air polishing and reinforcement of oral hygiene instructions for every patient. In this group perioflow (EMS – subgingival air polishing using small granulation powder was also used), then subgingival curetage around implants was performed using several titanium curetes (Hu-Friedy Manufacturing Co., Chicago, IL, USA) according tot the topography of each implant. Clorhexidine 0.2% Curasept (Curaden, Kriens, Switzerland) was used in a seringe with a bold needle was used to wash vigurously during manual curretage ant after it. After stopping the local bleeding by local compresion using sterile gause, clorhexidine gel was delivered with care inside the periimplant pocket using a seringe with a bold needle that was previously filled with clorhexidine gel Curasept (Curaden, Kriens, Switzerland).

RESULTS AND DISCUSSIONS

The focus of this research was to evaluate the potential of lasers in decreasing pocket, depth around implant and also in reducing local signs of inflammation as bleeding on probing, puss, redness and swallowing comparing to a widely commonly used method.

Patients underwent a complete consultation. Pocket depth around implant was measured in 6 points: MV, V, DV, MB, B, DB, also bleeding on probing was noted at the same points. Patients were instructed to keep a very strict oral hygiene, and the plaque score around implants was evaluated before the treatment was performed.

Radiographic evaluation of the bone loss around implants was also done.

After recording the initial parameters, patients underwent treatment for mucositis: ultrasound cleaning, air polishing and chlorhexidine 0.2% in the contol group and ultrasound cleaning, laser bacterial reduction protocol using 940 nm diode and curettage/ laser conditioning using Er,Cr: YSGG 2780 nm laser in the treatment group.

Patients were strongly advised to perform a good oral hygiene and plaque score around implant was checked before performing the treatment.

3 and 6 months after baseline implant pocket depth and bleeding on probing were recorded.

As results: values measured on pocket depth around implant were decreased in both groups. A higher mean value was found in second group. In the first group implant pocket depth diminished significantly, and a higher resolution in bleeding on probing (BOP) was found in the same group (Table 2).

DOI : 10.62610/RJOR.2024.1.16.1

Variable		Dif PDI initial - 6 month		Dif BOP initial - 6 month	
		Mean±DS	P	Mean±DS	P
Gender	f	1.4±1	0.08	0.5±0.3	0.1
	m	1.8±1		0.6±0.3	
Implant	Y	1.8±1	0.2	0.6±0.3	0.6
	O	1.5±1		0.5±0.3	
KM/NKM	N	1.7±1.1	0.1	0.6±0.3	0.01
	Y	1.4±1.1		0.4±03	
Topogaphy	FS	2.4±0.8	<0.001	0.8±0.1	<0.001
	LI	1.9±0.9		0.7±0.3	
	LS	1±0.8		0.3±0.3	
Smoking	Y	1.6±1	0.5	0.6±0.3	0.04
	N	1.5±1		0.5±0.4	
Periodontitis (in history)	Y	1.6±1	0.1	0.6±0.3	0.06
	N	0.9±0.7		0.3±0.2	

Tabel 2. Evolution of PD and BOP at 6 months.

Both variables as Pocket depth around implants (if diminished under 6 mm of depth) and the absence of clinical signs of inflammation by means the absence of measured bleeding on probing at 6 months after performing the treatment were evaluated together as parameters evaluating the success of the performed treatment, and significantly better results were observed in first group of subjects at their evaluation.

We determined the existence of a negative correlation, of weak power, statistically significant between the age of the patients and the difference of the initial BOP – 6 months (r=-0.243; p=0.02). We would not determine the existence of a significant correlation between implant age and the difference in the initial PDI – 6 months or the difference in the initial BOP – 6 months or between patients' age and the difference in the initial PDI – 6 months (Table 2).

The multivariate analysis showed that the treatment and localization of LS (Superior Lateral) are indepedently associated with the initial PDI difference at 6 months (p<0.001; repeatively p=0.02) (Table 3).

Variable	Unstandardized Coefficients		Standardized Coefficients	T	P
	B	Std. Error	Beta		
(Constant)	1.867	0.491		3.803	<0.001
Performed treatment	1.313	0.175	0.626	7.513	<0.001
Topography Upper Lateral	-0.391	0.175	-0.186	-2.237	0.02

Table 3. Multivariate analysis for initial PDI difference at 6 months.

Group Statistics					
	Lot	N	Mean	Std. Deviation	P-value
RBL I	C	42	2,1434	1,13807	0,000
	T	48	1,3765	,80235	
RBL 3	C	42	2,4396	1,29293	0,000

DOI : 10.62610/RJOR.2024.1.16.1

month	T	48	1,2918	,79924	
RBL 6 month	C	42	2,5425	1,15014	0,000
	T	48	1,2541	,80285	
RBL I – 3month	C	42	-,2962	,33596	0,000
	T	48	,0847	,22826	
RBL I - 6 month	C	42	-,3991	,24524	0,000
	T	48	,1224	,23959	
RBL 3 - 6 month	C	42	-,1028	,35874	0,008
	T	48	,0378	,07036	

Table 4 Evolution and group comparisons for clinical parameter RBL (osteo-implant-bone loss at implant shoulder)

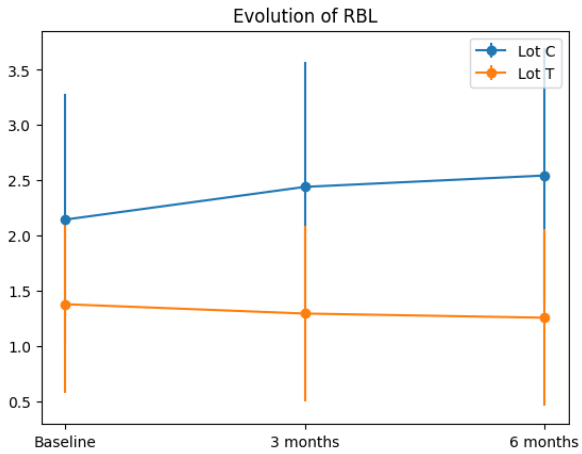

Figure 6. Comparison for RBL values throughout the study.

RBL I (Baseline): Radiographic Bone loss
The mean motor for group C (2.1434) is significantly higher than that for group T (1.3765) (Table 4). There is a highly statistically significant difference between the Control (C) and Treatment (T) groups at the 6-month assessment (P-value = 0.000) (Figure 6).

RBL 3 months:
The mean for the Control group (2.4396) is significantly higher than that for the Treatment group (1.2918).
There is a highly statistically significant difference between the Control (C) and Treatment (T) groups at the 6-month assessment (P-value = 0.000).

RBL 6 months:
There is a highly statistically significant difference between the Control (C) and Treatment (T) groups at the 6-month assessment (P-value = 0.000).
The mean for the Control group (2.5425) is significantly higher than that for the Treatment group (1.2541).

DOI : 10.62610/RJOR.2024.1.16.1

Group Statistics					
	Lot	N	Mean	Std. Deviation	P-value
PI I	C	52	,1603	,27008	0,972
	T	49	,1585	,23526	
PI 3 month	C	51	,1046	,19137	0.913
	T	48	,1007	,16030	
PI 6 month	C	51	,0915	,21425	0,707
	T	47	,0780	,12458	
PI I – 3month	C	51	,0588	,26630	0,964
	T	48	,0611	,24080	
PI I - 6 month	C	51	,0719	,19792	0,746
	T	47	,0872	,26681	
PI 3 - 6 month	C	51	,0131	,18512	0,749
	T	47	,0248	,17713	

Table 5. Evolution and group comparisons for clinical parameter PI (plaque index)

Overall, a small decrease in values (Table 5, Figure 7).

PI (IMPLANT PLAQUE SCORE) I:

The Control Group (C) and Treatment Group (T) have similar means (0.1603 vs. 0.1585), and the p-value of 0.972 suggests there's no significant difference between the groups.

PI 3 months:

Again, the Control and Treatment groups have comparable means (0.1046 vs. 0.1007), and the high p-value (0.913) indicates no statistically significant difference.

PI 6 months:

The means are 0.0915 (C) and 0.0780 (T), with a p-value of 0.707, suggesting no significant difference between the groups at the 6-month mark.

During all checkpoints for the study, group C and group T had similar values, as shown from the following figure.

Figure 7. Group comparison for PI values throughout the study.

PI I - 3 months:

Both groups have means of 0.0588 (C) and 0.0611 (T), and the p-value is 0.964, indicating no significant difference in the change from FMPS I to 3 months. The changes that happened during this time period are pretty similar, no group had a significantly bigger improvement that the other group.

PI I - 6 months:

Similarly to the previous comparisons, the means (0.0719 vs. 0.0872) and the p-value (0.746) suggest no significant difference in the change from FMPS I to 6 months.

PI 3 - 6 months:

DOI : 10.62610/RJOR.2024.1.16.1

The means for both groups are small (0.0131 vs. 0.0248), and the p-value of 0.749 indicates no significant difference in the change from 3 to 6 months.
With regard to BOP, it is generally observed that the values for both groups are decreased (Table 6, Figure 8):

Group Statistics					
	Lot	N	Mean	Std. Deviation	P-value
BOP I	C	53	,6415	,29670	0,930
	T	49	,6361	,33277	
BOP 3 month	C	53	,5126	,37389	0,354
	T	49	,4456	,35090	
BOP 6 month	C	53	,4057	,39698	0,006
	T	48	,2118	,27663	
BOP I – 3month	C	53	,1289	,43809	0,498
	T	49	,1905	,47507	
BOP I - 6 month	C	53	,2358	,41658	0,034
	T	48	,4306	,49206	
BOP 3 - 6 month	C	53	,1069	,31874	0,045
	T	48	,2431	,35557	

Table 6. Evolution and group comparisons for clinical parameter BOP (Bleeding On Probing)

BOP I (Baseline):

The mean motor for group C (0.6415) is significantly higher than that for group T (0.6361).

BOP 3 months:

The mean for the Control group (0. 5126) is significantly higher than that for the Treatment group (0. 4456).

BOP 6 months:

There is a highly statistically significant difference between the Control (C) and Treatment (T) groups at the 6-month assessment (P-value = 0.006).

The mean for the Control group (0.4057) is significantly higher than that for the Treatment group (0.2118).

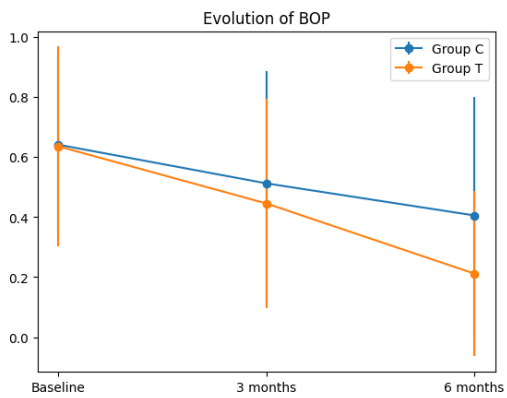

Figure 8. Group comparison for BOP values throughout the study.

BOP I - 3 Months:

Both groups C and T showed a decrease in values. The t-test indicates no significant difference between the groups at 3 months.

BOP I - 6 Months:

Both groups C and T showed a further decrease in values. Looking and the mean for this time, we can say that group T had significantly better improvements compared to Group C. The t-test indicates that there is a

DOI : 10.62610/RJOR.2024.1.16.1

significant difference between the groups at 6 months (P-value = 0,034).

BOP 3 - 6 Months

Both groups showed some improvements, with group T showing much more improvements. The t-test indicates that there is a significant difference between the groups at 6 months (P-value = 0,045) (Figure 8).

Group Statistics					
	Lot	N	Mean	Std. Deviation	P-value
PD I	C	53	4,9057	1,63577	0,021
	T	49	4,2823	,93554	
PD 3 month	C	53	4,3112	1,34603	0,013
	T	49	3,6803	1,14253	
PD 6 month	C	53	4,2830	1,21932	0,000
	T	49	3,5382	,74555	
PD I – 3month	C	53	,6918	1,42939	0,721
	T	49	,6020	1,05399	
PD I - 6 month	C	53	,6226	1,20014	0,547
	T	49	,7604	1,07898	
PD 3 - 6 month	C	53	-,0692	1,23189	0,371
	T	49	,1424	1,12357	

Table 7. Evolution and group comparisons for clinical parameter PD (Probing Poket Depth).

Overall: decrease in values for both groups (Table 7, Figure 9).

PD I (Baseline):

There is a statistically significant difference between the Control (C) and Treatment (T) groups at the initial assessment (P-value = 0.021).

The mean motor for the Control group (4.9057) is significantly higher than that for the Treatment group (4.2823).

PD 3 months:

There is a statistically significant difference between the Control (C) and Treatment (T) groups at the 3-month assessment (P-value = 0.013).

The mean for the Control group (4.3112) is significantly higher than that for the Treatment group (3.6803).

PD 6 months:

There is a highly statistically significant difference between the Control (C) and Treatment (T) groups at the 6-month assessment (P-value = 0.000).

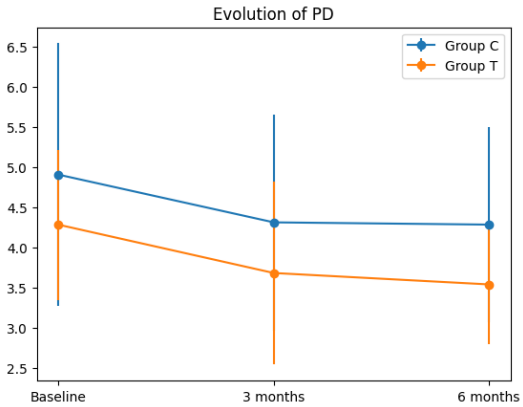

Figure 9. Group comparison for PD values.

DOI : 10.62610/RJOR.2024.1.16.1

The mean for the Control group (4.2830) is significantly higher than that for the Treatment group (3.5382).

PD I - 3 Months:

Both groups C and T showed a decrease in values.

The t-test indicates no significant difference between the groups at 3 months.

PD I - 6 Months:

Both groups C and T showed a further decrease in values.

Looking and the mean for this time, we can say that group T had significantly better improvements compared to Group C.

PD 3 - 6 Months:

Considering the means, group T had a slight improvement this time, however group C did not have any visible modifications, on the contrary it took a step back.

Despite the fact that nowadays implants have been shown a high survival rate, [35] and implant supported prothesis are a high survival rate comparing to traditional dental supported prosthesis, still a high prevalence of implant inflammatory complication are occurring [36]. Due to reduced vascularization and specific biological conditions peri-implant tissues are more susceptible to bacterial challenge that may lead to implant loose [37].

As treatment for peri-implant inflammatory complications despite the fact that several treatment protocols have been proposed, none of them have shown to achieve a complete resolution of the disease. Air-powered abrasive powder, citric acid, ultrasonic or manual titanium or plastic curettes, titanium brushes, antiseptics, antibiotics they are all studied [38],[39] but no treatment achieved a complete elimination of the bacteria from the implant site. Some of these methods ended by damaging the implant surface or charging the soft tissue with titanium particles [40].

Due to their special characteristics lasers appear to be the next big player on the scene. Each laser came to its own treatment benefits according to their special laser -tissue interaction according to the special wavelength and the specific dosage. Sometime combination of different lasers has been proposed to maximise the patient benefit from 2 complementary laser tissue interactions.

Er, Cr: YSGG laser (as part of the erbium lasers group) is known for a verry delicate curettage performed on the soft tissue, with a penetration depth up to 24 microns due to the concentration in water of the soft tissue, delicate and efficient curettage of the surrounding bone without damaging it, and more than that has proven an efficient cleaning, conditioning and decontaminating properties on the surface of the implant without damaging it. Implant surface that have been treated with Er,Cr: YSGG restore its wettability (by removing lipopolosacharrides, cell debrids and toxins from the implant threads, and offering better conditions for new cells derivate from blood clot to attach , (is free from all cell debrids, contaminates and toxins.) Er,Cr:YSGG is known for its antibacterial efficiency independent of the type of bacteria [33], due to the fact that its efficiency is related to the water content of living cells (by means bacteria but not exclusively). The antibacterial effect is extended to all human tissue that the laser is firing together with a delicate removal of 1-2 cell layers of the fired tissue.

The second laser that have been used in this protocol is InGaAsP, 940 nm, that has melanine and haemoglobin as chromophore. The laser bacterial reduction protocol for 940 nm is conducted in non-contact mode, with a non-initiated tip, to avoid any risk of damaging the implant surface. Dosage was calculated in order not to overheat the surrounding tissue. The fired laser with the wavelength of 940 nm has an efficient

DOI : 10.62610/RJOR.2024.1.16.1

penetration in difficult anatomical areas as furcations, denticule, etc and is targeting all pigmented bacteria in the area the laser is fired, with a penetration depth that might touch a millimetre in depth. Overheating was avoided by cooling the area with water spray during the procedure.

3 and 6 months after the treatment data were collected. At 3,6 months after treatment pocket depth were collected and compared with the initial values. Also bleeding on probing at each site was evaluated and compared with initial values. In laser group a higher resolution in bleeding on probing was observed. At the same time the decrease on preimplant pocket depth was noticed.

Statistically significant changes were found between initial pocket depth around implants in 6 months comparing to baseline in both groups.

Regarding bleeding on probing also significant changes were found between 6 months and initial measurements in both groups. The absence of keratinized mucosa around tested implants did not show to be an important factor in reducing inflammation signs despite the fact that is known that the absence of keratinized mucosa might have an impact in development of mucositis, but the reduced number of subject of implants showing nonkeratinized mucosa and the good oral might not influenced the final results Considering that reducing pocket depth around implants under 6 mm of depth and no bleeding on probing as the major elements that indicates diminution of the disease, we found a statistically significant difference between the laser group and the group treated with air polishing and chlorhexidine in favour of laser group. (79.4% of mucositis lesions around implants were proven reduced pocket depth measurements and no bleeding on probing at 6 months)

Considering from a different perspective this analysis none the age of the patient or the age of the implant or gender of the patient shown to make an impact on the results.

But a correlation medium power was, statistically significant was found between the age of the patient and the clinical results. That might be related also to the difficulties in keeping a good oral hygiene for older patients. The age of the implant did not seem to be significantly for the results.

We spited the evaluated patient's group in subgroups according to the topography of the diagnosed mucositis. There in an increased prevalence of mucositis in posterior superior area followed by posterior lower area, and these areas are the ones that responded less to the treatment performed.

We also evaluated the treatment performed considering also the age of the implant. As the prevalence of mucositis is higher in elder implants (over 5y presence in oral cavity) we evaluated if older implants are responding less each proposed treatment or not. According to the results of this research there is no significant difference in post treatment evolution between the elder group of implants (over 5 years) and the young group of implants as response to the same performed treatment.

The lack of keratinized tissue and smoking were also evaluated as secondary variables in this research.

CONCLUSIONS

1. The results of this research conducted that laser bacterial reduction treatment and laser curettage in the treatment of mucositis might be considered a reliable

DOI : 10.62610/RJOR.2024.1.16.1

alternative to air polishing and CHX 0.2% in the treatment of mucositis.

2. The current study showed the impact of pairing two lasers on the success of peri-implated mucitis treatment.
3. The novelty and the impact of our research on the treatment of peri-implantar mucositis consists in using the new technique that involves the simultaneity of the two lasers.The third conclusion.

Acknowledgements

The study was conducted in accordance with the Declaration of Helsinki and approved by the Ethics Committee of "Transylvania" University of Brasov and "Krondent" Dental Clinic (Project identification code 101E, date of approval 30.11.2015) for studies involving humans.

The authors would like to thank Prof. Gratiela Georgiana Noja for the support and constructive comments and also to the Alexandra Gruia and Alexandra-Maria Țugurlan for their help.

REFERENCES

1. Gupta R, Gupta N, Weber, DDS KK. Dental Implants. 2023 Aug 8. In: StatPearls [Internet]. Treasure Island (FL): StatPearls Publishing; 2023 Jan–. PMID: 29262027.
2. Montero J. A Review of the Major Prosthetic Factors Influencing the Prognosis of Implant Prosthodontics. J Clin Med. 2021 Feb 17;10(4):816. doi: 10.3390/jcm10040816. PMID: 33671394; PMCID: PMC7921991.
3. Araujo MG, Lindhe J. Peri-implant health. J Periodontol. 2018 Jun;89 Suppl 1:S249-S256. doi: 10.1002/JPER.16-0424. PMID: 29926949.
4. Heitz-Mayfield LJA, Salvi GE. Peri-implant mucositis. J Clin Periodontol. 2018 Jun;45 Suppl 20:S237-S245. doi: 10.1111/jcpe.12953. PMID: 29926488.
5. Johansson, Krister DDS; Jimbo, Ryo DDS, PhD†; Östlund, Pernilla PhD‡; Tranæus, Sofia DDS, PhD§; Becktor, Jonas P. DDS, PhD. Effects of Bacterial Contamination on Dental Implants During Surgery: A Systematic Review. Implant Dentistry 26(5):p 778-789, October 2017. | DOI: 10.1097/ID.0000000000000660
6. Barootchi S, Wang HL. Peri-implant diseases: Current understanding and management. Int J Oral Implantol (Berl). 2021 Aug 20;14(3):263-282. PMID: 34415128.
7. Lombardo G, Signoriello A, Marincola M, Nocini PF. Assessment of Peri-Implant Soft Tissues Conditions around Short and Ultra-Short Implant-Supported Single Crowns: A 3-Year Retrospective Study on Periodontally Healthy Patients and Patients with a History of Periodontal Disease. Int J Environ Res Public Health. 2020 Dec 14;17(24):9354. doi: 10.3390/ijerph17249354. PMID: 33327506; PMCID: PMC7764932.
8. Babay, N. & Alshehri, Fatimah & Rowis, R.. (2019). Majors highlights of the new 2017 classification of periodontal and peri-implant diseases and conditions. The Saudi Dental Journal. 31. 10.1016/j.sdentj.2019.04.006.
9. Naveau A, Shinmyouzu K, Moore C, Avivi-Arber L, Jokerst J, Koka S. Etiology and Measurement of Peri-Implant Crestal Bone Loss (CBL). J Clin Med. 2019 Feb 1;8(2):166. doi: 10.3390/jcm8020166. PMID: 30717189; PMCID: PMC6406263.
10. Monje A, Insua A, Wang HL. Understanding Peri-Implantitis as a Plaque-Associated and Site-Specific Entity: On the Local Predisposing Factors. J Clin Med. 2019 Feb 25;8(2):279. doi: 10.3390/jcm8020279. PMID: 30823574; PMCID: PMC6406659.
11. Corsalini M, Montagnani M, Charitos IA, Bottalico L, Barile G, Santacroce L. Non-Surgical Therapy and Oral Microbiota Features in Peri-Implant Complications: A Brief Narrative Review. Healthcare (Basel). 2023 Feb 23;11(5):652. doi: 10.3390/healthcare11050652. PMID: 36900657; PMCID: PMC10000417.

DOI : 10.62610/RJOR.2024.1.16.1

12. Renvert S, Hirooka H, Polyzois I, Kelekis-Cholakis A, Wang HL; Working Group 3. Diagnosis and non-surgical treatment of peri-implant diseases and maintenance care of patients with dental implants - Consensus report of working group 3. Int Dent J. 2019 Sep;69(Suppl 2):12-17. doi: 10.1111/idj.12490. PMID: 31478575; PMCID: PMC9379037.
13. Sanz M, Lang NP, Kinane DF, Berglundh T, Chapple I, Tonetti MS. Seventh European Workshop on Periodontology of the European Academy of Periodontology at the Parador at la Granja, Segovia, Spain. J Clin Periodontol. 2011 Mar;38 Suppl 11:1-2. doi: 10.1111/j.1600-051X.2010.01692.x. PMID: 21323697.
14. Rokaya D, Srimaneepong V, Wisitrasameewon W, Humagain M, Thunyakitpisal P. Peri-implantitis Update: Risk Indicators, Diagnosis, and Treatment. Eur J Dent. 2020 Oct; 14(4):672-682. doi: 10.1055/s-0040-1715779. Epub 2020 Sep 3. PMID: 32882741; PMCID:
15. Brookes ZLS, Bescos R, Belfield LA, Ali K, Roberts A. Current uses of chlorhexidine for management of oral disease: a narrative review. J Dent. 2020 Dec;103:103497. doi: 10.1016/j.jdent.2020.103497. Epub 2020 Oct 17. PMID: 33075450; PMCID: PMC7567658.
16. Krishnamoorthy G, Narayana A, Balkrishanan D. Chlorhexidine for the Treatment of Peri-Implantitis: Is it a Benison? J Long Term Eff Med Implants. 2022;32(1):19-23.
17. Carcuac O, Abrahamsson I, Charalampakis G, Berglundh T. The effect of the local use of chlorhexidine in surgical treatment of experimental peri-implantitis in dogs. J Clin Periodontol. 2015 Feb;42(2):196-203. doi: 10.1111/jcpe.12332. Epub 2015 Jan 20. PMID: 25385434.
18. Schwartzenberg AV, Liu CC, Sahrmann P, Schmidlin PR, Jung RE, Naenni N. Risk Characteristics of Peri-Implant Infections: A Retrospective Evaluation in a University Consultation Setting. Dent J (Basel). 2022 Aug 29;10(9):159. doi: 10.3390/dj10090159. PMID: 36135154; PMCID: PMC9497582.
19. Machtei EE, Romanos G, Kang P, Travan S, Schmidt S, Papathanasiou E, Tatarakis N, Tandlich M, Liberman LH, Horwitz J, Bassir SH, Myneni S, Shiau HJ, Shapira L, Donos N, Papas A, Meyle J, Giannobile WV, Papapanou PN, Kim DM. Repeated delivery of chlorhexidine chips for the treatment of peri-implantitis: A multicenter, randomized, comparative clinical trial. J Periodontol. 2021 Jan;92(1):11-20. doi: 10.1002/JPER.20-0353. Epub 2020 Nov 11. PMID: 33111988.
20. Liu S, Li M, Yu J. Does chlorhexidine improve outcomes in non-surgical management of peri-implant mucositis or peri-implantitis?: a systematic review and meta-analysis. Med Oral Patol Oral Cir Bucal. 2020 Sep 1;25(5):e608-e615. doi: 10.4317/medoral.23633. PMID: 32683389; PMCID: PMC7473444.
21. Toma, Selena & Lasserre, Jérôme & Taïeb, Johana & Brecx, Michel. (2014). Evaluation of an air-abrasive device with amino acid glycine-powder during surgical treatment of peri-implantitis. Quintessence international (Berlin, Germany : 1985). 45. 209-19. 10.3290/j.qi.a31205.
22. Romanos GE, Fischer GA, Delgado-Ruiz R. Titanium Wear of Dental Implants from Placement, under Loading and Maintenance Protocols. Int J Mol Sci. 2021 Jan 21;22(3):1067. doi: 10.3390/ijms22031067. PMID: 33494539; PMCID: PMC7865642.
23. Miller RJ. Treatment of the contaminated implant surface using the Er,Cr: YSGG laser. Implant Dent. 2004 Jun; 13(2):165-70. doi: 10.1097/01.id.0000127521.06443.0b. PMID: 15179093.
24. Asnaashari M, Zadsirjan S. Application of laser in oral surgery. J Lasers Med Sci. 2014 Summer;5(3):97-107. PMID: 25653807; PMCID: PMC4281997.
25. Fahlstedt P, Bunaes DF, Lie SA, Leknes KN. Dental implant surface temperatures following double wavelength (2780/940 nm) laser irradiation in vitro. Clin Exp Dent Res. 2021 Aug;7(4):512-521. doi: 10.1002/cre2.369. Epub 2020 Dec 4. PMID: 33274852; PMCID: PMC8404505.
26. Smeo, Khaled & Nasher, Riman & Gutknecht, Norbert. (2018). Antibacterial effect of Er,Cr:YSGG laser in the treatment of peri-implantitis and their effect on implant surfaces: a literature review. Lasers in Dental Science. 2. 1-9. 10.1007/s41547-018-0032-5
27. Gerasimenko AY, Morozova EA, Ryabkin DI, Fayzullin A, Tarasenko SV, Molodykh VV, Pyankov ES, Savelyev MS, Sorokina EA, Rogalsky AY, et al. Reconstruction of Soft Biological

DOI : 10.62610/RJOR.2024.1.16.1

Tissues Using Laser Soldering Technology with Temperature Control and Biopolymer Nanocomposites. *Bioengineering*. 2022; 9(6):238. https://doi.org/10.3390/bioengineering9060238.

28. Renvert S., Lindahl C., Jansäker A.M.R., Persson R.G. Treatment of peri-implantitis using an Er: YAG laser or an air-abrasive device: A randomized clinical trial. J. Clin. Periodontol. 2011;38:65-73. doi: 10.1111/j.1600-051X.2010.01646.x.
29. Aimetti M, Mariani GM, Ferrarotti F, Ercoli E, Liu CC, Romano F. Adjunctive efficacy of diode laser in the treatment of peri-implant mucositis with mechanical therapy: a randomized clinical trial. Clin Oral Implants Res. 2019;30:429-438.
30. Ashnagar S, Nowzari H, Nokhbatolfoghahaei H, Yaghoub Zadeh B, Chiniforush N, Choukhachi Zadeh N. Laser treatment of peri-implantitis: a literature review. J Lasers Med Sci. 2014 Fall;5(4):153-62. PMID: 25653815; PMCID: PMC4281989.
31. Atich MA, Fadhul 1, Shah M, Hannawi H, Alsabeeha NHM. Diode Laser as an Adjunctive Treatment for Peri-implant Mucositis: A Systematic Review and Meta-analysis. Int Dent J. 2022 Dec; 72(6):735-745. doi: 10.1016/j.identj.2022.06.026. Epub 2022 Aug 2. PMID: 35931559; PMCID: PMC9676556.
32. Bareatebi. Sbaxar & Wang, How-Lay. (2021). Peri-implant diseases: Current understanding and management. International journal of oral implantology (Berlin, Germany). 14. 263-282.
33. Martelli FS, Fanti E, Rosati C, Martelli M, Bacci G, Martelli ML, Medico E. Long-term efficacy of microbiology-driven periodontal laser-assisted therapy. Eur J Clin Microbiol Infect Dis. 2016 Mar;35(3):423-31. doi: 10.1007/s10096-015-2555-y. Epub 2016 Jan 6. PMID: 26740323.
34. Aoki A, Mizutani K, Schwarz F, Sculean A, Yukna RA, Takasaki AA, Romanos GE, Taniguchi Y, Sasaki KM, Zeredo JL, Koshy G, Coluzzi DJ, White JM, Abiko Y, Ishikawa I, Izumi Y. Periodontal and peri-implant wound healing following laser therapy. Periodontol 2000. 2015 Jun;68(1):217-69. doi: 10.1111/prd.12080. PMID: 25867988.
35. Beschnidt SM, Cacaci C, Dedeoglu K, Hildebrand D, Hulla H, Iglhaut G, Krennmair G, Schlee M, Sipos P, Stricker A, Ackermann KL. Implant success and survival rates in daily dental practice: 5-year results of a non-interventional study using CAMLOG SCREW-LINE implants with or without platform-switching abutments. Int J Implant Dent. 2018 Nov 2;4(1):33. doi: 10.1186/s40729-018-0145-3. PMID: 30386925; PMCID: PMC6212375.
36. Hanif A, Qureshi S, Sheikh Z, Rashid H. Complications in implant dentistry. Eur J Dent. 2017 Jan-Mar; 11(1): 135-140. doi: 10.4103/ejdejd_340_16. PMID: 28435381; PMCID: PMC5379828.
37. Ivanovski S, Lee R. Comparison of peri-implant and periodontal marginal soft tissues in health and disease. Periodontol 2000. 2018 Feb;76(1):116-130. doi: 10.1111/prd.12150. Epub 2017 Nov 30. PMID: 29193334.
38. Rokaya D, Srimaneepong V, Wisitrasameewon W, Humagain M, Thunyakitpisal P. Peri-implantitis Update: Risk Indicators, Diagnosis, and Treatment. Eur J Dent. 2020 Oct;14(4):672-682. doi: 10.1055/s-0040-1715779. Epub 2020 Sep 3. PMID: 32882741; PMCID:PMC7536094.
39. Alpaslan Yayli, N.Z., Talmac, A.C., Keskin Tunc, S. et al. Erbium, chromium-doped: yttrium, scandium, gallium, garnet and diode lasers in the treatment of peri-implantitis: clinical and biochemical outcomes in a randomized-controlled clinical trial. Lasers Med Sci 37, 665-674(2022). https://doi.org/10.1007/s10103-021-03436-5
40. Romanos GE, Fischer GA, Delgado-Ruiz R. Titanium Wear of Dental Implants from Placement, under Loading and Maintenance Protocols. Int J Mol Sci. 2021 Jan 21;22(3):1067. doi: 10.3390/ijms22031067. PMID: 33494539; PMCID: PMC7865642.

DOI : 10.62610/RJOR.2024.1.16.1