

## SURGICAL AND CBCT CORRELATION IN ACQUIRED CHOLESTEATOMA IN THE NORTH-EAST REGION OF ROMANIA

Ariadna Mocrei<sup>1</sup>, Diana-Andreea Ilinca<sup>1</sup>, Alexandru Nemtoi<sup>2</sup>, Danisia Haba<sup>1</sup>

<sup>1</sup>”Grigore T. Popa” University of Medicine and Pharmacy, Department of Surgery 1

<sup>2</sup> Faculty of Medicine and Biological Sciences, Stefan cel Mare University Suceava

Corresponding author: Diana-Andreea Ilinca email dianaandreeailinca@gmail.com

Alexandru Nemtoi email: alexandru.nemtoi@usm.ro,

### ABSTRACT

**Aim of the study** The aim of the study is to showcase the surgical and cone-beam computer-tomography (CBCT) aspects in patients with acquired cholesteatoma. **Material and methods** We retrospectively study 61 patients CBCT diagnosed with acquired cholesteatoma from January 2020 – December 2022. **Results** Our study showed that from 60 patients: 48 cholesteatomas were formed due to chronic middle ear infection, 7 from trauma and 5 had prior surgical manipulations. The pathology affected females more (54,1% of the lot) and was treated with closed technic. Cholesteatoma had a predilection for the right ear (45%) but in 13,3% of cases had bilateral involvement and in more than half of the cases (53,3%) involved both the atical and the atrium. 35 patients had complications such as ossicular lesions (osteolysis) to the incus (58,3%), to the incus and malleus (21,7%) or to all three (incus, malleus and stapes) (15%). A small percentage had extension into the facial canal (5,9%) or in sigmoid dural sinus (1,5%). **Conclusions** CBCT alongside surgical diagnostics significantly deepened our comprehension of the cholesteatoma’s extension into the structures of the middle ear.

**Key words:** acquired cholesteatoma; CBCT; middle ear; preoperative; postoperative; surgical;

### INTRODUCTION:

Middle ear cholesteatoma is one of the most fascinating and complex subjects in otology studies when it comes to its different in-depth aspects (de Aquino et al 2011). Cholesteatoma is a non-tumoral cystic lesion of the temporal bone that can provoke osseous resorption and have fatal complications (Hamed et al, 2016). In simpler terms, cholesteatoma refers to “skin in the wrong place” (Zaman S., et al, 2022).

Clinically, there are two types of chronic otitis media: the “safe type”, considered the one without cholesteatoma, and the “unsafe type”, where choleseatoma is present (Zaman S., et al, 2022). Acquired cholesteatoma is subdivided

into: primary (behind an apparently intact tympanic membrane (frequent) and secondary (less common) in association with a perforated tympanic membrane. In both cases patients have history of recurrent ear disease and it is uniquely located in the middle ear (Barath K., et al, 2011).

Other subtypes of cholesteatoma include: Mural Cholesteatoma – that are extensive lesions in the middle ear and mastoid, with continuous growth that can resemble a mastoidectomy cavity (without prior surgical interventions), hence also known as “automastoidectomy” – and “external auditory canal cholesteatoma” particularly seen in elderly population (has to be carefully

differentiated from squamous cell carcinoma) (Barath K, et al 2011).

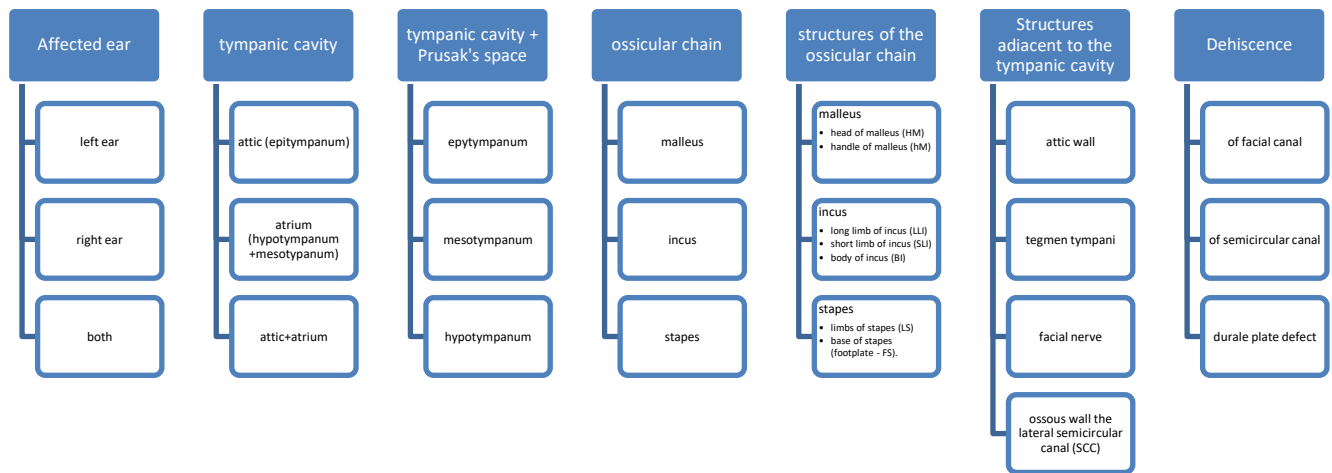
HRCT (high-resolution computed-tomography) and CBCT (cone-beam computed-tomography) are the imaging techniques of choice when cholesteatoma is suspected. Typical findings that are associated with the presents of cholesteatoma are expansive soft-tissue lesion with sharp margins, tympanic membrane retraction, scutum blunting and erosion to the tympanic tegmen and ossicles (Barath K., 2011).

In the context of limited studies providing epidemiological and statistical data on the prevalence, localization and extent of cholesteatoma, our study holds practical utility for clinicians and researchers exploring the field. It aims to elucidate the pathogenesis of cholesteatoma and the potential of recurrence prediction based on the degree of involvement of the middle ear structures. We also hypothesized that a delayed diagnosis is associated with extensive boney erosion and extension into the middle ear structures.

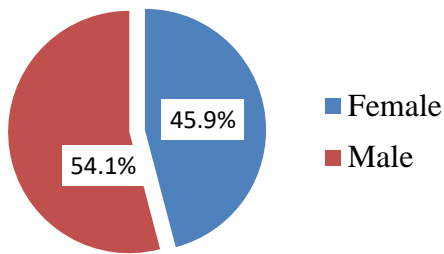
**MATERIALS AND METHODS:**

We retrospectively studied a lot of 63 patients that checked the inclusion criteria (chronic otitis media diagnostics, clinical presentation in association with cholesteatoma such as otorrhea with or without hearing loss or tinnitus). We excluded from our study 2 patients because of suboptimal imaging aspects due to motion artifacts or beam hardening artifacts determined by extensive dental work. The initial study was done on a lot of 61 patients (33 males, 28 females, with a mean age of diagnosis of 36,9) diagnosed with cholesteatoma after CBCT investigation, surgically treated with closed techniques (83,65%) or open techniques (16,4%) (Fig. 1, Table 2, Table 3).

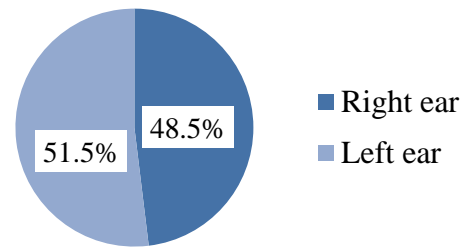
Descriptive statistics regarding the distribution of cholesteatoma concerning the various locations presented above (Table 1) were conducted based on the sample of 60 patients diagnosed with cholesteatoma and, repectively, at the level of the group of 68 ears diagnosed with cholesteatoma. (Fig. 2).



**Table 1.** Key points and ear structures studied



**Figure 1. Percentage based on gender distribution**



**Figure 2. Percentage based on the affected ear**

We excluded another patient from the study group due to evacuated cholesteatoma, ultimately reducing the study group to 60 patients.

Age – t-Student = -1.380, p = 0.173

Gender	N	Mean	Standard deviation	Standard error of the mean	Minimum	Maximum	Mean
F	33	40.03	18.358	3.196	9	86	39.00
M	28	33.21	20.194	3.816	7	87	27.00
Total	61	36.90	19.365	2.479	7	87	35.00

**Table 2. Descriptive statistics regarding the age**

Surgical technique	n	%
Open	10	16.4
Closed	50	82.0
Closed – evacuated cholesteatoma	1	1.6
Total	61	100.0

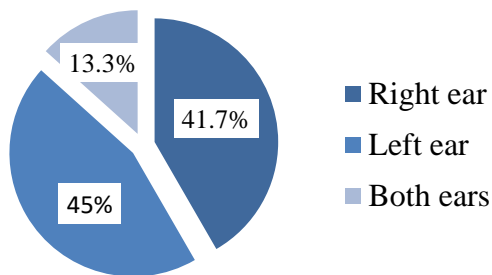
**Table 3a. Percentage distribution based on the surgical technique**

		CBCT				Total		Pearson Chi-square test
		Right ear		Left ear		N	%	
		N	%	N	%			
Surgical technique	open	4	12.1%	10	28.6%	14	20.6%	Chi <sup>2</sup> = 2.811 p = 0.094
	closed	29	87.9%	25	71.4%	54	79.4%	
Total		33	100.0%	35	100.0%	68	100.0%	

**Table 3b. Percentage distribution based on the surgical technique**

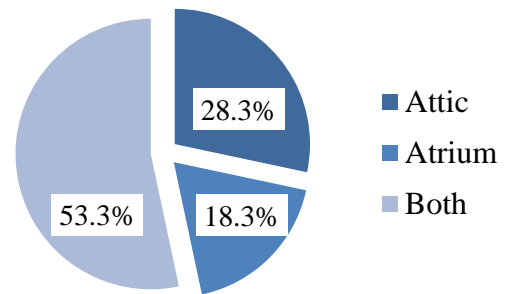
**RESULTS**

The CBCT acquisition were interpreted by a senior radiologist very experienced in ear diseases and a radiology resident for defining the bone erosion, the localization of cholesteatoma and its extend into adjacent structures. On CBCT exams, 25 patients had colesteatoma in the right ear (41.7%), 27 patients had colesteatoma in the left ear (45%) and 8 patients had bilateral cholesteatoma (13.3%). (Fig. 3)



**Figure 3. Location of the cholesteatoma (right/left ear)**

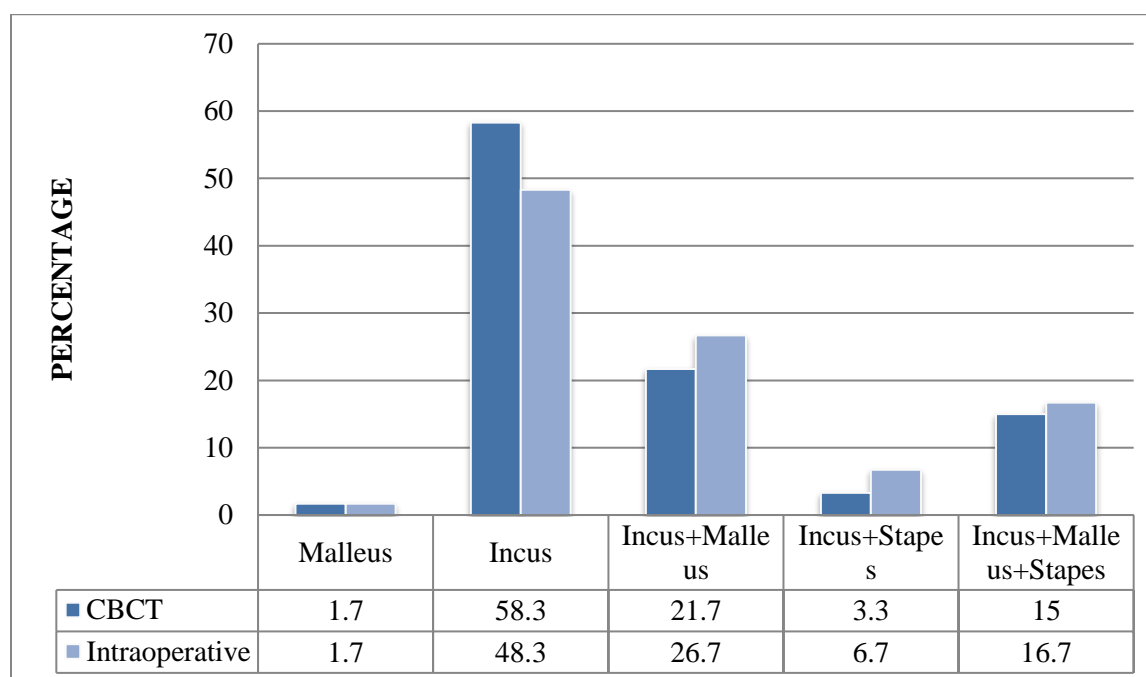
Regarding the location, 17 patients presented cholesteatoma in the attic region (28.3%), 11 patients at the level of the atrium (18.3%) and 32 patients had involvement of both regions (53.3%). (Fig. 4)



**Figure 4. Location of the cholesteatoma (attic/atrium)**

Extension	n	%
absent	30	50.0
Retrotympalum	7	11.7
Retrotympalum + Mastoid	1	1.7
Retrotympalum + Mastoid + EAC	1	1.7
Retrotympalum + EAC	1	1.7
Retrotympalum + Eustachian tube	1	1.7
Mastoid	13	21.7
Mastoid + EAC	1	1.7
Mastoid + Eustachian tube	1	1.7
EAC	3	5.0
Eustachian tube	1	1.7
Total	60	100.0

**Table 4. Prevalence and localization of the cholesteatoma**



**Figure 5. Prevalence of erosion to the ossicular chain (CBCT versus intraoperative findings)**

In regards of ossicular chain erosion due to the presents of cholesteatoma, we present the CBCT and intraoperative aspects (Fig. 5).

On CBCT 35 patients had erosions to the incus (58.3%), 13 patients to the incus and malleus (21.7%), 9 to incus, malleus and stapes (15%), 2 at the level of incus and

stapes (3.3%) and 1 patient only on malleus (1.7%). (Fig. 5)

Intraoperative findings showed that 29 patients had erosions on incus (48.3%), 16 patients with incus and malleus erosions (26.7%), 10 patients with incus, malleus and stapes lesions (16.7%), 4 patients with incus and stapes erosions

(6.7%) and one with isolated malleus implications (1.7%).

Ossicular chain erosion	CBCT		INTRAOPERATIVE	
	n	%	n	%
	Malleus			
HM	18	30.0	22	36.7
HM, hM	5	8.3	5	8.3
Incus				
LLI	23	38.3	22	36.7
SLI	2	3.3	2	3.3
BI	2	3.3	4	6.7
LLI, BI	27	45.0	25	41.7
LLI, SLI	1	1.7	2	3.3
SLI, BI	2	3.3	2	3.3
LLI, SLI, BI	2	3.3	2	3.3
STAPES				
LS	2	3.3	2	3.3
FS	6	10.0	10	16.7
LS, FS	3	5.0	2	3.3

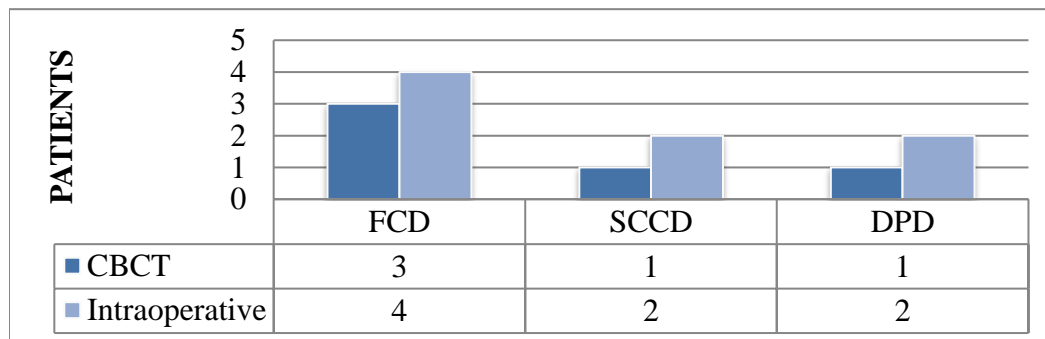
**Table 5. Prevalence of erosion to the components of the ossicular chain (CBCT versus intraoperative findings)**

Regarding the erosion to the components of the ossicular chain on CBCT, from 23 patients with erosion at the level of malleus, 18 (30%) had erosion to the HM and 5 (8.3%) to the hM.

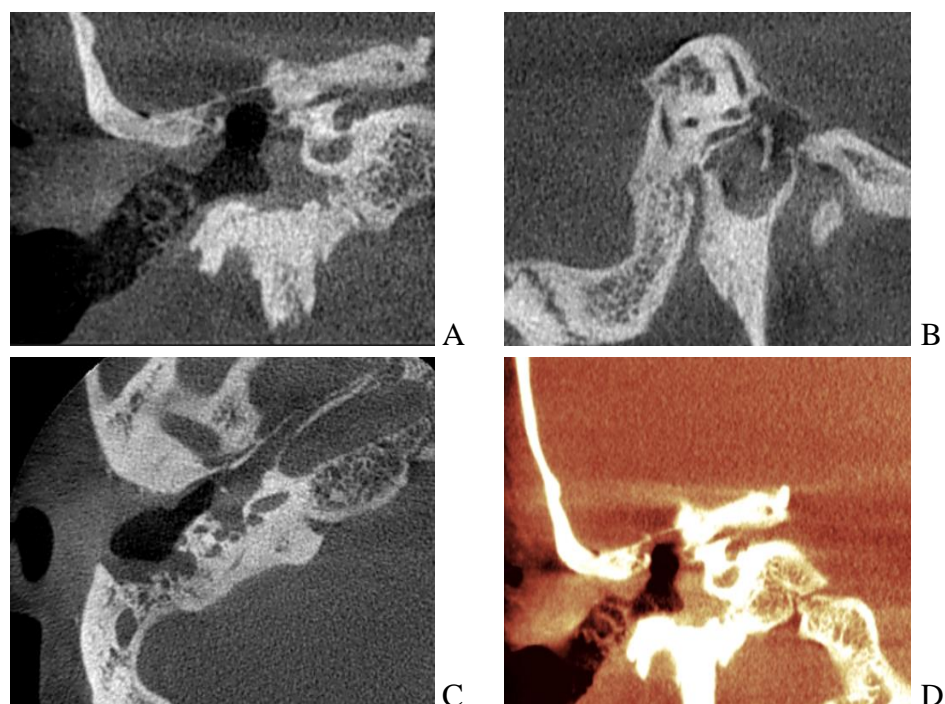
From 53 patients with implication of the incus, 23 patients (38.3%) had erosions to the LLI, 2 patients had erosions to the SLI and 2 at the level of the BI, 27 patients had implications of the LLI and BI (45%), 1 patient to both of the limbs of the incus (1.7%), 2 patients – SLI and BI (3.3%) and 2 to SLI, LLI and BI (3.3%).

From 11 patients with CBCT erosion of the stapes, 2 patients (3.3%) had both limbs involved, 6 patients (10%) had erosion to the footplate, 3 patients (5%) to the limbs and footplate.

Intraoperative findings regarding the erosion to the components of the ossicular chain from 27 patients with erosion at the level of malleus, 22 had erosion to the HM and 5 (8.3%) to the hM.



**Figure 6. Prevalence of FCD, SCCD, DPD (CBCT versus intraoperative findings).**



**Figure 7. CBCT findings (A – sagittal recon; B – coronal recon; C – axial recon; D – 3D recon) in a 23 years old patient with history of head trauma with mandibular fracture (5 years ago) presenting for hearing loss and otorrhea from the right ear. Note the expansive soft-tissue mass in the mesotympanum and hypotympanum, associated with attic lytic lesions and scutum blunting and thinning of the tegmen tympani.**

In our study we found a total of 7 acquired cholesteatoma due to head trauma (representing a total of 11.6% from all cases in our study lot) (Fig.7).

## DISCUSSIONS

Regarding the prevalence of cholesteatoma in patients with chronic otitis media, Rosito et al (2017) reported that among patients with chronic otitis media, 419 (24.5%) had cholesteatoma, within a patient group with an average age of 34.49 years (53.5% female, 46.5% male; 63.8% adults, 36.2% patients aged < 16 years). In our study,

the average age of investigated patients was 36.9 years, a value close to that reported by Rosito et al (2017). However, the distribution of patients by gender was 54% male and 46% female. One of the earliest studies on cholesteatoma, conducted by Sade et al in 1982, reported a predominance of male patients (55.7%) compared to female patients (44.3%).

The surgical approach includes closed and open techniques. In our study, 20.6% of cholesteatomas were managed through open surgical techniques, while 79.4% of cases utilized closed surgical techniques. Rosito et

al (2017) reported the use of closed techniques (closed tympanomastoidectomy) in 16.8% of diagnosed cholesteatoma patients, while open tympanomastoidectomy was performed in 75.2% of patients.

Through CBCT examination, we diagnosed 25 patients with cholesteatoma in the right ear (41.7%) and 27 patients in the left ear (45%). Bilateral cholesteatoma was found in 8 patients (13%) out of the 60 investigated with cholesteatoma. Rosito et al (2017) reported bilateral cholesteatoma in 17.1% of diagnosed cholesteatoma patients. Bilateral cholesteatoma is encountered in 19.6% of cases in patient cohorts diagnosed intraoperatively with cholesteatoma (Aquino, 2007).

Our personal study conducted on 60 patients (68 ears) diagnosed with cholesteatoma investigated the extension and degree of involvement of middle ear structures using CBCT and intraoperative examination. All patients were diagnosed with cholesteatoma through CBCT, although CBCT examination was associated with intraoperative assessment to determine the degree of extension and involvement of middle ear structures.

Heikkinen et al (2023) demonstrated the possibility of excellent visualization of middle ear structures by optimizing imaging parameters using a recent CBCT device (planmed XFI, Planmed Oy, Finland). The purpose of this ex vivo study was to optimize the imaging parameters of the new CBCT device to achieve the optimal contrast-to-noise ratio (CNR) with a low effective dose and to optimize its clinical use.

Through CBCT examination, the extension of the cholesteatoma at the level of

the tympanic cavity compartments was evaluated: 35% of patients presented cholesteatoma at the level of the hypotympanum, 65% at the level of the mesotympanum, 56.7% at the level of Prusak's space, and 70% at the level of the epitympanum. It's observed that the epitympanum is the most frequently affected, followed by the mesotympanum and Prusak's space. The percentages are similar when referring to the number of ears affected by cholesteatoma, with 66.2% of ears showing extension of the cholesteatoma at the level of the epitympanum, 64.7% at the level of the mesotympanum, 54.4% at the level of Prusak's space, and only 35.3% at the level of the hypotympanum.

Within the investigated group by Rosito et al (2017) the posterior epitympanic was involved in a percentage of 32.9%.

In our personal study, we investigated the presence of osteolysis at the level of the ossicular chain components. Through the CBCT examination, we found the most frequent involvement of the incus, present in 97.1% of cases, followed by malleus involvement in 36.8% of cases, and stapes involvement in 17.6% of the investigated ears. Intraoperatively, malleus involvement was present in 26.5% of cases, incus involvement in 97.1% of cases, and stapes involvement in 26.5% of cases. It's observed that while the percentage of ears with incus involvement is similar between the two examination categories, in the intraoperative examination, an additional percentage of 8.9% of ears with stapes involvement was diagnosed, while the CBCT examination gave a false-positive diagnosis for 10.3% of

ears diagnosed through CBCT with malleus involvement.

The destruction of the ossicular chain is the most frequent complication of cholesteatomas; the type of damage depends on the initial location and the expansion of the cholesteatoma (Waidyasekara et al, 2015; Young et al, 2017). Cholesteatomas in tension areas have an erosion rate of 90% (Schwarz et al, 1984). The ossicular chain was intact in only 26% of cholesteatomas located in the attic cavity (Schwarz et al, 1984). According to some authors, the most affected area of the ossicular chain is the incus (Sade et al, 1982; Schwarz et al, 1984; Palomar et al, 1989), with the long process of the incus being the most affected, followed by the body of the incus and the malleus head (Schwarz et al, 1984). According to other authors, ossicular chain erosion was observed most frequently at the level of the malleus (40%), followed by the incus (33%) and stapes (27%) (Barati & Barati, 2023). Ossicular chain lesions have been evaluated in various studies. The prevalence of osteolysis at the level of the ossicular chain has been reported from 82% (75% observed at the level of the malleus) to 94% (86.1% at the level of the malleus, 66% at the level of the stapes, and 43% at the level of the incus) (Mohammadi et al, 2012; Albera et al, 2012).

Barati & Barati (2023), in a study investigating the clinical and surgical characteristics of acquired cholesteatomas, reported that out of 1790 patients with chronic otitis media, 449 (25.0%) were diagnosed with cholesteatoma. The average age of patients with cholesteatoma was  $32.2 \pm 16.1$  years, with a predominance of male patients (62.8%). Erosion of the facial nerve

canal was observed in 33.1% of patients, erosion of the dural plate in 4.8% of cases, and labyrinthine fistula in 10.3% of patients. In cases of cholesteatomas leading to ossicular chain erosion, this was most frequently observed at the level of the malleus (40%), followed by the incus (33%) and stapes (27%). In our study, intraoperative detection revealed facial canal osteolysis in 5.9% of cases, semicircular canal osteolysis in 2.9% of cases, and dural plate defect in 2.9% of cases. Investigation of these areas via CBCT examination led to a false-negative diagnosis of facial nerve canal dehiscence in 1.5% of ears, false-negative diagnosis of semicircular canal dehiscence in 1.5% of ears, and false-negative diagnosis of dural plate defect in 1.5% of ears.

In our study, the extension of osteolysis into the stapes was recorded by CBCT examination in 17.6% of cases and in 26.5% of cases diagnosed intraoperatively. In our personal study, we found cholesteatoma extension in 27.9% of cases.

The localization and extension of cholesteatoma directly influence the prognosis and recurrence rate, with a recurrence rate ranging from 5 to 13%, primarily within the first 5 years (Silvola et al, 2000). Wang et al (2022), in a study conducted on 118 patients (123 ears) with cholesteatoma, reported that the degree of ossicular chain component destruction (involvement of the stapes) and extension of the cholesteatoma into the sinus tympani are predictive factors for increased recurrence risk. Considering that the extent of cholesteatoma can be used to predict recurrence, Eggink et al (2021, 2022) and van der Toom et al (2020) evaluated the

prognostic value of ChOLE, STAMCO, JOS, EAONO-JOS classifications in predicting acquired cholesteatoma severity. The studies concluded that these classifications have limited prognostic value in predicting cholesteatoma recurrence. The follow-up period, type of surgical intervention, and patient age are confounding factors challenging the development of a universal classification. In this context, no correlations were found between cholesteatoma staging and the occurrence of residual or recurrent pathology. Eggink et al (2022) reported that cholesteatoma extension into the sinus tympani or extensive extension into the mastoid, as well as absence of stapes superstructure, were predictive for residual cholesteatoma. Sclerotic mastoids had a lower risk of residual disease, while poorly ventilated and poorly pneumatized mastoids were associated with an increased risk of recurrence. These conclusions demonstrate the importance of determining cholesteatoma

extension for selecting patients who will be closely monitored postoperatively, identifying these risk factors for recurrence.

Study limitations include the retrospective nature (the risk of incomplete patient records) and the relatively small number of subjects included in the cohort.

## CONCLUSIONS

CBTC can be used not only in dentistry but also in ENT surgery preoperatively in the analysis of cholesteatomas with complex extension patterns and potential complications. It allows assessment of bone destruction, erosion of the facial nerve canal and lateral semicircular canal which present significant challenges in diagnosis and surgical management. The complexity of cholesteatoma location and extent directly influences prognosis, recurrence rates, and the need for vigilant and tailored monitoring after surgery.

## REFERENCES

1. Aquino JE, Cruz Filho NA, de Aquino JN. Epidemiology of middle ear and mastoid cholesteatomas: study of 1146 cases. *Braz J Otorhinolaryngol*. 2011 Jun;77(3):341-7.
2. Aquino JEP. Epidemiologia do colesteatoma. Conferência proferida no II Curso de Otologia do Hospital Beneficência Portuguesa.; São Paulo: 2007.
3. Barati B, Asadi M. Clinical and Surgical Features of Acquired Middle Ear Cholesteatoma: A 10 Years Population-based Study. *Shiraz E-Med J*. 2023;24(5):e133899.
4. Eggink MC, de Wolf MJF, Ebbens FA, Dijkers FG, van Spronsen E. Assessing the Prognostic Value of the ChOLE Classification in Predicting the Severity of Acquired Cholesteatoma. *Otol Neurotol*. 2022 Apr 1;43(4):472-480.
5. Eggink MC, de Wolf MJF, Ebbens FA, Dijkers FG, van Spronsen E. Evaluation of Long-term Cholesteatoma Recidivism: Using the JOS, EAONO-JOS, and STAMCO Cholesteatoma Staging Systems. *Otol Neurotol*. 2021 Aug 1;42(7):1031-1038.
6. Heikkinen AK, Rissanen V, Aarnisalo AA, Nyman K, Sinkkonen ST, Koivisto J. Assessment of subjective image quality, contrast to noise ratio and modulation transfer function in the middle ear using a novel full body cone beam computed tomography device. *BMC Med Imaging*. 2023 Apr 10;23(1):51.

7. Hamed MA, Nakata S, Sayed RH, Ueda H, Badawy BS, Nishimura Y, Kojima T, Iwata N, Ahmed AR, Dahy K, Kondo N, Suzuki K. Pathogenesis and Bone Resorption in Acquired Cholesteatoma: Current Knowledge and Future Prospectives. *Clin Exp Otorhinolaryngol*. 2016 Dec;9(4):298-308.
8. Mohammadi G, Naderpour M, Mousaviagdas M. Ossicular erosion in patients requiring surgery for cholesteatoma. *Iran J Otorhinolaryngol*. 2012;24(68):125-8.
9. Palomar V, Fortuny JC. Données statistiques du cholestéatoma. *Cahiers ORL*. 1989;6(15):439-443.
10. Rosito LPS, Canali I, Teixeira A, Silva MN, Selaimen F, Costa SSD. Cholesteatoma labyrinthine fistula: prevalence and impact. *Braz J Otorhinolaryngol*. 2019 Mar-Apr;85(2):222-227.
11. Sadé J, Konak S, Hinchcliffe R. Proceedings of 2nd International Conference. Kugler Publications; Tel-Aviv, Israel: 1982. Cholesteatoma and Mastoid Surgery; p. 640.
12. Silvola J, Palva T. One-stage revision surgery for pediatric cholesteatoma: long-term results and comparison with primary surgery. *Int J Pediatr Otorhinolaryngol*. 2000;56(2):135-9.
13. Uz Zaman S, Rangankar V, Muralinath K, Shah V, K G, Pawar R. Temporal Bone Cholesteatoma: Typical Findings and Evaluation of Diagnostic Utility on High Resolution Computed Tomography. *Cureus*. 2022 Mar 1;14(3):e22730. doi: 10.7759/cureus.22730.
14. van der Toom H, van der Schroeff MP, Janssen J, Westzaan AM, Pauw RJ. A Retrospective Analysis and Comparison of the STAM and STAMCO Classification and EAONO/JOS Cholesteatoma Staging System in Predicting Surgical Treatment Outcomes of Middle Ear Cholesteatoma. *Otol Neurotol*. 2020 Apr;41(4):e468-e474.
15. Waidyasekara P, Dowthwaite SA, Stephenson E, Bhuta S, McMonagle B. Massive temporal lobe cholesteatoma. *Case Rep Otolaryngol*. 2015;2015:121028.
16. Wang X, Guo J, Liu W, Chen M, Shao J, Zhang X, Ma N, Li Y, Peng Y, Zhang J. Comparison of the EAONO/JOS, STAMCO and ChOLE cholesteatoma staging systems in the prognostic evaluation of acquired middle ear cholesteatoma in children. *Eur Arch Otorhinolaryngol*. 2022 Dec;279(12):5583-5590.