

CORRELATIONS BETWEEN VITAMIN D LEVEL AND THE PRESENCE OF LARGE CHRONIC PERIAPICAL LESIONS IN PATIENTS UNDERGOING COMPLEX ORAL REHABILITATION TREATMENT

Liana Aminov⁺¹, Maria Antonela Beldiman², Eugeniu Mihalas⁺³, Irina Gradinaru²⁺, Magdalena Cuciureanu⁴⁺, Bogdan Constantin Mihaila²⁺, Ovidiu Stamatina²⁺, Laura Elisabeta Checheriță¹

1. University of Medicine and Pharmacy "Grigore T. Popa" Iasi, Faculty of Dental Medicine, Department of Odontology-Periodontology- Fixed Restorations

2. University of Medicine and Pharmacy "Grigore T. Popa" Iasi, Faculty of Dental Medicine, Department of Oral Implantology

3. University of Medicine and Pharmacy "Grigore T. Popa" Iasi, Faculty of Dental Medicine, Department of Preventive Medicine

4. University of Medicine and Pharmacy "Grigore T. Popa" Iasi, Faculty of General Medicine Pharmacology department, Clinical pharmacology and algesiology.

*Corresponding authors e-mail:

- Maria Antonela Beldiman, DMD, PhD - Department of Oral Implantology Faculty of Dental Medicine, UMF Iasi, Romania e-mail: mariabeldiman@yahoo.com

- Eugeniu Mihalas, DMD, PhD - Department of Preventive Medicine, Faculty of Dental Medicine, UMF Iasi, Romania e-mail: emihalas@yahoo.com

⁺All authors have the same scientific contribution.

Abstract

Chronic apical periodontitis (CAP) is considered to be a dynamic defence response against micro-organisms invasion into periradicular tissues, resulting in a destruction of surrounding periapical bone. Among other important regulatory functions, vitamin D demonstrated to have a role in modulating the inflammatory process of periradicular tissues, in calcium and bone homeostasis and apoptosis. This retrospective study aimed to assess the relationship between vitamin D (VitD) levels and the incidence of large periapical rarefactions in dental patients that further undergo complex prosthetic rehabilitation.

In this regard, a number of 28 patients, 54,8% men (n=16) and 45,2% women (n=12) with a complete medical and dental history, in the age range of 18–50 years were taken under observation. They were examined radiographically and clinically to diagnose the presence of CAP, presence and quality of root canal fillings, quality of restoration and periapical status. Another group of 28 patients in the same age range and gender-matched individuals without any history of systemic disease or presence of CAP lesions were included in the study as the control group. Serum VitD levels were analyzed for all patients. The prevalence of teeth with large chronic periapical lesions was 85,7% in the analyzed group. The results showed significantly different values of Vitamin D levels in individuals with CAP compared with control patients (P =0,003). The presence or absence of root canal fillings in affected teeth didn't correlate with the lesion dimension or severity of the evolution.

Key words: chronic apical periodontitis (CAP), Vitamin D, root canal filling, complex oral rehabilitation.

Introduction

In general, efficient endodontic therapy and good reconstructing of the teeth after endodontic completes therapy are required for a successful prosthetic

restoration or rehabilitation of variable clinic type of pulpitis or apical periodontitis lesion. It has been claimed that teeth that have had endodontic treatment are more brittle and susceptible to fracture than normal teeth.

After receiving endodontic treatment, it has been suggested that the tooth must be fortified or reinforced by inserting an intraradicular post in the root canal. Posts do not strengthen teeth, however, and post space preparation and post cementation can weaken the root, potentially resulting in its fracture, according to various studies.

After the root canal therapy is finished, a variety of prosthetic treatment options are available. The majority of them either involve direct restorations like resin composites, amalgam, or cements or crowns[1-4].

Recent meta-analysis has shown that more than half of the adult population worldwide have at least one tooth with apical periodontitis [5]. Post-treatment apical periodontitis has usually a residual root infection as an etiological causative factor [6]. The treatment of apical periodontitis consists of eliminating infection from the root canal and preventing re-infection by a hydraulic seal of the root canal space. However, the endodontic treatment can fail for various reasons[7].

It is known that microflora generally invades extraradicular tissues during expanding and exacerbating phases of the disease process. However, many of these lesions that have started previous to the endodontic treatment heal after a correct root canal filling .The explanation could be that although the organisms may not all survive post-treatment, it is more likely that the bacteria may be present in quantities and virulence that may be sub-critical to sustain the inflammation of the periapex [8].

Vitamin D (VitD) is a fat-soluble vitamin, mainly obtained from sunlight and diet, that

modulates multiple biological processes and functions of the body and acts as a hormone. It stimulates intestinal calcium absorption and is important in maintaining adequate phosphate levels for bone mineralization, bone growth, and remodelling. The normal range of vitamin D is measured as nanograms per milliliter (ng/mL, Table I). Many experts recommend a level between 20 and 40 ng/mL. Others recommend a level between 30 and 50 ng/mL[9].

The 25-hydroxy Vit D test is the most accurate way to measure how much vitamin D is in the body. Recently, the role of vitamin D in periodontal disease pathogenesis has been established as affecting bone mineral density and bone resorption [10]. The immunoregulatory and anti-inflammatory roles of VitD have been also reported. It is mentioned that there is an increased prevalence of VitD deficiency in patients with aggressive periodontitis, suggesting that decreased VitD level could be a risk factor, and screening is recommended where deficiency is suspected[11].

Although the right or “healthy” amount of Vit D in the blood is still a subject of argument, the estimated VitD level of 20 ng/mL or higher was considered adequate for good bone health and subsequently a level below 20 was considered a vitamin D deficiency [12]. Even if there was fair evidence from previous studies of an association between circulating 25(OH)D concentrations with some bone health outcomes (established rickets, osteomalacia, bone mineral density changes), the evidence for an association was inconsistent for other outcomes [13],[14].

Table I
25 hidroxyVitamin D levels

30 ng / ml	Considered adequate and healthy
20 ng / ml- 30 ng / ml	Considered VitD sufficient
< 20 ng / ml	VitD deficient
> 80 ng / ml	Associated with toxic effects

Table I. The reference ranges for vitamin D blood levels according to the NIH’s Office of Dietary Supplements and the Institute of Medicine (IOM)

Materials and methods

In this regard, the present study tries to find out if there is a correlation between the blood levels of vitamin D and the presence of large chronic periapical lesions in dental patients seeking complex oral rehabilitation at the Clinical Base of Dentistry, University of Medicine and Pharmacy of Iasi, Romania. The study on these patients was conducted after obtaining their informed consent and under the ethical principles for medical research involving human subjects (WMA Declaration of Helsinki) [15].

28 patients, 57,14% men (n=16) and 42,86% women (n=12) with a complete medical and dental history, in the age range of 18–50 years were taken under observation. They were examined radiographically and clinically to diagnose the presence of chronic apical periodontitis (CAP), presence and quality of root canal fillings, quality of restoration and periapical status.

Another group of 28 patients in the same age range and gender-matched individuals without any history of systemic disease or presence of CAP lesions were included in the study as the control group. Serum VitD levels were analyzed for all patients. Subjects with fewer than 12 teeth present or with other bone-associated general pathologies, pregnant and postmenopausal women and previous VitD supplementation were excluded.

All orthopantomography was taken with the same device and computer software, PaX-i3D Smart PHT-30FLO. Means and standard deviations of radiographic bone lesions, VitD, and age were calculated. The serum VitD was measured from 10-mL venous blood samples, collected and analyzed in the same laboratory using a

Maglumi 600 standardized device. VitD levels of the patients were divided in three groups (<20, 20-30, and > 30 ng/mL) and the results compared with the size of bone lesions. The radiographs were analyzed by three different examiners and were taken into study only those on which everyone agreed. Those with a diameter greater than 5mm were considered large lesions.

The patients who needed further prosthetic rehabilitation received post and chore restoration after the endodontic treatment in 11 cases, followed by ceramic fused to metal crowns (7 patients) and integral ceramic crowns (4 patients). In 4 cases, the patients needed rehabilitation with ceramic fused to metal bridges. The study was carried out over two years and all the information was statistically analyzed after.

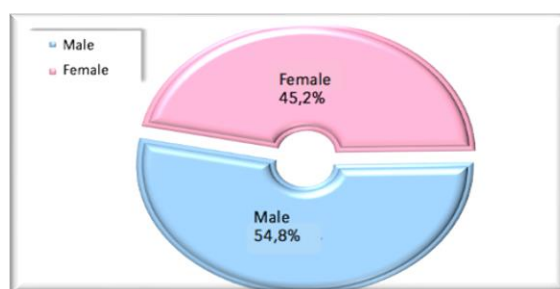
Results

The total number of nonvital untreated teeth was 18 and of endodontically treated teeth was 34. There were found 11 large periapical lesions associated with nonvital untreated teeth, 4 in the maxilla and 7 in the mandible and 14 large periapical lesions associated with endodontically treated teeth, 4 maxillary and 10 mandibular, from a total of 34 treated. 11

The results of the blood tests for the Vit D levels in the study group were: 18 patients < 20 ng/ml, 10 patients between 20-30 ng/ml and no patient >30 ng/ml. In the control group, there was 1 patient with Vit D level < 20ng, 20 patients between 20-30 ng/ml and 7 patients >30 ng/ml. From the patients with Vit D deficiency (32), in 27 periapical lesions surrounded nonvital untreated teeth, and in 5 patients the lesions were around endodontically treated teeth.

Table I. *Distribution of cases according to patients gender*

	Cases	%
Female	12	45.2%
Male	16	54.8%
Total	28	100%



Cases distribution according to the radiological result in untreated nonvital teeth

Radiological result	Cases	%
Nonvital untreated teeth with PAL	11	61,1%
maxilla	4	22,2%
mandible	7	38,8%
Total nonvital untreated teeth	18	100%

Cases distribution according to the radiological result in endodontically treated teeth

Radiological result	Cases	%
Endodontically treated teeth with PAL	14	41,1%
maxilla	4	11,7%
mandible	10	29,4%
Total endodontically treated teeth	34	100%

The study group consisted of 56 subjects, 33 women (58.9%) and 23 men (41.1%) with an average age of 42.017 ± 10.79 years (min. 18, max. 58). 75% of the subjects were from the urban environment (Table 1).

Table I. Distribution of cases according to demographic characteristics

	No	%
Age	42.017 ± 10.79 years (min.18, max.58)	
Gender	Female	33
	Male	23
Residence	Urban	42
	Rural	14

The distribution of subjects regarding the level of vitamin D in the blood between the two groups was equal to avoid possible biases in the statistical analysis (table 2).

Table 2. Distribution of subjects according to serum level of vitamin D / group

			Groups	
			group control	group case
Serum level of vitamin D	Sufficient level of vitD(20 ng / ml- 30 ng / ml)	Count	18	18
		% within Serum level of vitamin D	50.0%	50.0%
	Deficient level of vitD(< 20 ng / ml)	Count	10	10
		% within Serum level of vitamin D	50.0%	50.0%

Among the 56 selected subjects, 45 presented periapical lesions (80.4%), most lesions being recorded in the case group (27 subjects, 60%) compared to the control group (40%). What is important to point out is the fact that the difference between the 2 groups is statistically significant ($p=0.003$) (table 4).

Table 4. Distribution of selected subjects according to periapical lesion / group

Periapical lesion		Total	group		p
			group control	group case	
Present	No	45	18	27	0.003
	%	80.4%	40.0%	60.0%	
Absent	No	11	10	1	
	%	19.65	90.9%	9.1%	

In relation to the level of vitamin D in the blood, the statistical analysis shows that those in the case group have more periapical lesions in the case of subjects with a deficient level of vit.D (< 20 ng / ml) compared to subjects who have a sufficient level of vit.D (20 ng / ml- 30 ng / ml) but also between groups.

Discussions

Although several treatment modalities have been proposed for endodontically treated teeth with persistent apical periodontitis, there is a general need for less invasive methods with more predictable outcomes. In most of the cases, after a correct endodontic treatment, the success rate is generally high. [16]. However,

there are still some systemic diseases or status which may affect the outcome of endodontic treatment.

Animal studies have indicated that rodents with defected autoimmune conditions have a higher risk of the spread of endodontic infections and evolve greater periapical lesions stressing on the effect of vitamin D on the immune system and inflammation [17],[18]. Another recent research found a significantly higher rate of periapical abscess presence in vitamin D deficient patients compared to patients without vitamin D deficiency [19-22].

Related to these aspects, in this study we found particularly interesting the case of a 39 years old patient, with no significant general health history, who came for a 'swelling' on his lower right jaw, which

created a discomfort both in talking and mastication. To palpation, it was a fluctuant, soft formation under the jugal mucosa adjacent to the horizontal mandibular ramus, between the two premolars. The patient was referred for a histopathological examination, CBCT and blood analyzes. The histological diagnosis was central giant cell granuloma and clinical tests were further done, in order to exclude a hyperparathyroidism. The

radiological image showed a large, radiolucent lesion in the right side of the mandible, extended from the first lower molar region, to the frontal region on that side. (fig). The blood analyzes showed normal values, including the parathormone and serum Ca, Mg and PO4. The specific investigation for the VitD revealed an insufficient 25 hydroxyVitamin D level (Fig)

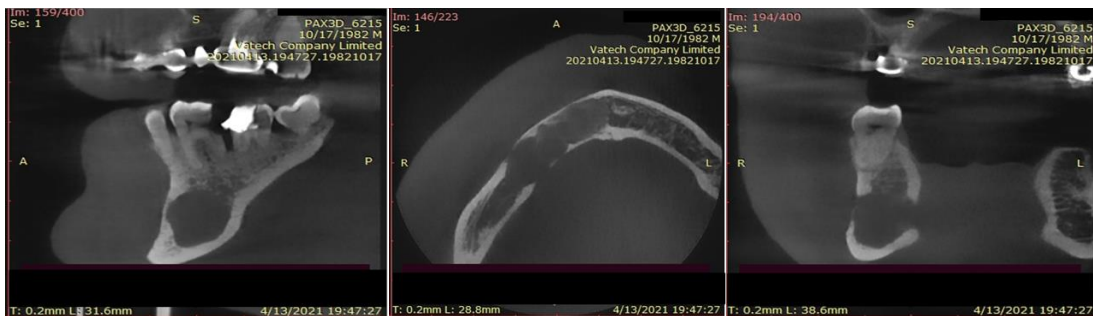

Fig. 1 Sagittal, axial and coronal CBCT incidences for the lower right mandible, showing the extent of the radiolucent lesion.

VAL.BIOL.REF.		
25-hidroxi-vitamina D...	25,8 µg/L	(>= 30)
INTERPRETARE:		
Carenta: <= 20 µg/L		
Nivel insuficient: 21 - 29 µg/L		
Nivel optim: >= 30 µg/L		
Nivel toxic posibil: > 100 µg/L		
Intoxicatia cu vitamina D se observa de obicei la valori serice ale 25-OH vitaminei D >150 µg/L.		
Limita minima de detectie: 3,5 µg/L.		
(ser, CMA)®		
Parathormon intact (PTH)...	37,0 pg/mL	(15,0 - 65,0)
	3,92 pmol/L	(1,59 - 6,89)
(ser, ECLIA)		
Calciu ionic seric...	1,26 mmol/L	(1,12 - 1,32)
(ser, ISE)		
Calciu total seric...	9,4 mg/dL	(8,4 - 10,2)
	2,35 mmol/L	(2,10 - 2,55)
Limita minima de detectie: 2,0 mg/dL.		
(ser, Spectrofotometrie)		
Magneziu seric...	2,32 mg/dL	(1,60 - 2,60)
	0,95 mmol/L	(0,66 - 1,07)
Limita minima de detectie: 0,60 mg/dL.		
(ser, Spectrofotometrie)		
PO4 seric...	3,4 mg/dL	(2,3 - 4,7)
	1,10 mmol/L	(0,74 - 1,52)
(ser, Spectrofotometrie)		

Fig. 2. The blood analysis showing normal values for the serum Ca, Mg and PO4 and low level of Vit D

Following investigations, the treatment plan was decided, including the surgical intervention for the large bone lesion. The first right lower molar, nonvital and damaged was also extracted. All the vital teeth adjacent to the lesion, from the second lower right molar to the lower right central incisor were devitalized and endodontically filled previous to the surgical treatment. Due to the pandemic situation, the surgical intervention was postponed. Meanwhile, the

patient constantly took VitD 2000UI a day, for six months. The radiograph taken after this period of time showed a clear resolution of the bone lesion, with the trabecular and compact alveolar bone being close to a normal appearance (Fig 3). The patient received in the end a prosthetic restorations for the edentulous spaces consisting in a ceramic fused to metal bridge in the fourth quadrant and a dental implant in the third quadrant.

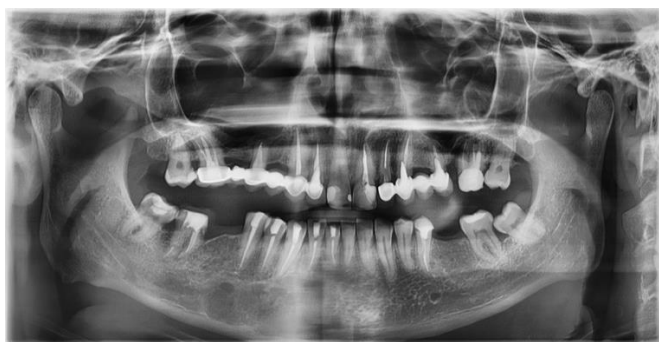

Fig. 3 The radiological image after six months shows the endodontic fillings of all the teeth adjacent to the previous lesion and the improved aspect of the bone in the lower right mandible.

Conclusions

Regarding the high prevalence of dental infections in the patients studied and periradicular lesions found, the actions of vitamin D on anti-inflammation and alveolar bone formation suggest its potential role in infection control in periradicular tissue repair. It can be speculated that adequate vitamin D status acts on the healing of endodontic diseases.

In this regard, the question arises of what type and what dose of vitamin D supplementation would provide the best clinical results.

Most probably, future studies will focus on the mechanism of action of vitamin D at the molecular level and try to establish an acceptable, safe and efficient supplementation method. The results of future studies will define the clinical role of vitamin D as a potential therapeutic intervention on the endodontic patients that further need more complex oral and prosthetic rehabilitation.

References

1. Forna NC (2011). *Protetică Dentară*, Vol. I si II, Ed. Enciclopedică, Iași.
2. Forna Norina Consuela, Checheriță Laura Elisabeta (2018). *Muscular rehabilitation for the patiens with algodysfunctional syndrome vol I, II*, publisher Grigore T. Popa, UMF Iași, ISBN: 978-606544-496-
3. Checheriță L.E., et all, *Dysfunctional Syndrome Of Stomatognathic System At Prosthetical And Endodontics Practitioners And The Therapeutical Approach-*

- BalneoPhysiotherapy,Romanian Journal Of Oral Rehabilitation,2019, Vol. 11, No. 3, July -September p:47-55
4. Walton TR. A 10-year longitudinal study of fixed prosthodontics: clinical characteristics and outcome of single-unit metal-ceramic crowns. *Int J Prosthodont.* 1999;12:519–526.
 5. Tibúrcio-Machado, CS, Michelon, C, Zanatta, FB, Gomes, MS, Marin, JA, Bier, CA. The global prevalence of apical periodontitis: a systematic review and meta-analysis. *International Endodontic Journal*, 54, 712– 735, 2021.
 6. Nair PNR. Pathogenesis of Apical Periodontitis and the Causes of Endodontic Failures. *Critical Reviews in Oral Biology & Medicine.* 2004;15(6):348-381. doi:10.1177/154411130401500604
 7. Sjögren U, Figdor D, Persson S, Sundqvist G. Influence of infection at the time of root filling on the outcome of endodontic treatment of teeth with apical periodontitis. *Int Endod J.* 1997 Sep;30(5):297-306. doi: 10.1046/j.1365-2591.1997.00092.x. Erratum in: *Int Endod J* 1998 Mar;31(2):148. PMID: 9477818.
 8. Nair PN, Henry S, Cano V, Vera J. Microbial status of apical root canal system of human mandibular first molars with primary apical periodontitis after "one-visit" endodontic treatment. *Oral Surg Oral Med Oral Pathol Oral Radiol Endod.* 2005 Feb;99(2):231-52. doi: 10.1016/j.tripleo.2004.10.005. PMID: 15660098.
 9. Medical Advisory Secretariat. Clinical utility of vitamin d testing: an evidence-based analysis. *Ont Health Technol Assess Ser.* 2010;10(2):1-93. Epub 2010 Feb 1. PMID: 23074397; PMCID: PMC3377517.
 10. Laky M., Bertl K., Haririan H., Andrukhov O., Seemann R., Volf I., Assinger A., Gruber R., Moritz A., Rausch-Fan X. Serum levels of 25-hydroxyvitamin D are associated with periodontal disease. *Clin. Oral Investig.* 2017;21:1553–1558.
 11. Wimalawansa SJ, Razzaque MS, Al-Daghri NM. Calcium and vitamin D in human health: Hype or real? *J Steroid Biochem Mol Biol.* 2018 Jun;180:4-14. doi: 10.1016/j.jsbmb.2017.12.009. Epub 2017 Dec 16. PMID: 29258769.
 12. Cranney A, Horsley T, O'Donnell S, Weiler H, Puil L, Ooi D, Atkinson S, Ward L, Moher D, Hanley D, Fang M, Yazdi F, Garritty C, Sampson M, Barrowman N, Tsertsvadze A, Mamaladze V. Effectiveness and safety of vitamin D in relation to bone health. *Evid Rep Technol Assess (Full Rep).* 2007 Aug;(158):1-235. PMID: 18088161; PMCID: PMC4781354.
 13. Newberry SJ, Chung M, Shekelle PG, Booth MS, Liu JL, Maher AR, Motala A, Cui M, Perry T, Shanman R, Balk EM. Vitamin D and Calcium: A Systematic Review of Health Outcomes (Update). *Evid Rep Technol Assess (Full Rep).* 2014 Sep;(217):1-929. doi: 10.23970/AHRQEPERTA217. PMID: 30313003.
 14. WMA-declaration-of-helsinki-ethical-principles-for-medical-research-involving-human-subjects.pdf
 15. S. Kalfsa, D. Figdor, G. Sundqvist A new bacterial species associated with failed endodontic treatment: identification and description of *Actinomyces radicidentis* *Oral Surg Oral Med Oral Pathol Oral Radiol Endod*, 92 (2) (2001), pp. 208-214
 16. A. Fouad, J. Barry, J. Russo, J. Radolf, Q.Zhu Periapical lesion progression with controlled microbial inoculation in a type 1 diabetic mouse model *JEndod*, 28 (1) (2002), pp. 8-16
 17. M.D. Srivastava, J.L. Ambrus Effect of 1.25(OH)₂ vitamin D analogs on differentiation induction and cytokine modulation in blasts from acute myeloid leukemia patients *Leuk Lymphoma*, 45 (10) (2004), pp. 2119-2126
 18. I. Rotstein, J. Katz, Prevalence of periapical abscesses in vitamin D deficient patients, *American Journal of Dentistry*, Volume 34, Issue 3, Pages 163 - 165 June 2021

19. Kakehashi S, Stanley HR, Fitzgerald RJ. The effects of surgical exposures of dental pulps in germ-free and conventional laboratory rats. *Oral Surg Oral Med Oral Pathol.* 1965;20:340–9.
20. Becconsall-Ryan K, Tong D, Love RM. Radiolucent inflammatory jaw lesions:a twenty-year analysis. *Int Endod J.* 2010;43(10):859–65.
21. Hiremath V., Rao C., Naiak V., Prasad K.V.V. Anti-inflammatory effect of vitamin D on gingivitis: a dose response randomised controlled trial. *Indian J. Public Health.* 2013;57:29–32.
22. Sheetal A, Hiremath VK, Patil AG, Sajjanetty S, Kumar SR. Malnutrition and its oral outcome - a review. *J Clin Diagn Res.* 2013 Jan;7(1):178-80. doi: 10.7860/JCDR/2012/5104.2702. Epub 2013 Jan 1. PMID: 23449967; PMCID: PMC3576783.