

THERATOGEN EFFECT OF ANTICONCEPTIONS ASSOCIATED WITH THE MAXIL MAXILO FACIAL ANOMALS

Alina Mihaela Calin¹, Ana Magdalena Bratu^{2*}, Razvan Leata¹, Cristian Budacu^{3*}, Mariana Ilie¹, Ramona Feier⁴

1 Faculty of Medicine and Pharmacy, University "Dunarea de Jos" Galati, Romania.

2 Carol Davila University of Medicine and Pharmacy, Bucuresti, Romania.

3 Faculty of Dental Medicine, "Grigore T. Popa" University of Medicine and Pharmacy, 700115 Iasi, Romania;

4 Dimitrie Cantemir University, Faculty of Medicine, Tg. Mures

* Corresponding authors: Ana Magdalena Bratu: anaconstm@gmail.com

Cristian Budacu : cristian.budacu@umfiasi.ro

+ All authors have the same scientific contribution and equal rights .

ABSTRACT

It is important to note that any changes in the treatments or medicines you use should be forwarded to your dentist during regular visits. Certain medications may interact with dental health in an unexpected way, so it is good to inform your dentist about all aspects of your health or changes. Nd: YAG laser (neodymium-yag) can be used in gingival hyperplasia therapy to treat and reduce excessive growth of gingival tissue. It is important to mention that achieving the success of Nd: YAG laser treatment may vary depending on the individual case and the medical qualifications dentist performing the procedure. Before deciding on any therapy, it is recommended to talk to your dentist for information on treatment options, benefits, and risks.

KEY WORDS: contraceptives, Nd Laser: YAG, gingival hyperplasia

INTRODUCTION

It is important to consult with your dentist and mention that you are using hormonal contraceptives. Your dentist can help monitor for any changes in oral health and give you advice on proper tooth and gum care. [1-3]

Hormonal contraceptives can have some side effects in the oral cavity for some women. It is important to understand that each person may react differently to medications, and not everyone will have the same symptoms or side effects. Some potential effects of hormonal contraceptives in the oral cavity include:

Gingivitis and gingival inflammation: Some women may develop a slight inflammation of the gums in response to hormonal changes induced by oral contraceptives. This can lead to gingivitis, which is characterized by gingival bleeding, swelling, and redness. [1-3]

Increased gum sensitivity: Some women may notice an increase in the sensitivity of hot, and cold gums or tooth brushing while using hormonal contraceptives.

Oral lesions: Some women may have small lesions or ulcers in the oral cavity in response to hormonal changes induced by the hormonal contraceptive. [1-3]

Xerostomy (mouth dryness): In rare cases, certain types of hormonal contraceptives may contribute to decreased saliva production, which can lead to dry mouth. Non-hormonal contraceptives, such as intrauterine devices (DIU) with copper and diaphragm, usually do not have a significant direct impact on the health of the oral cavity. These methods of contraception do not contain hormones and should therefore not directly affect oral health. [1-3]

Nd: YAG laser (neodymium-yag) is a type of neodymium laser doped with itrium-

aluminum-garnet (Nd: YAG), which emits in close infrared, with a wavelength of approximately 1064 nanometers. This type of laser has various applications in medicine and especially in dentistry for the treatment of the oral cavity. [4-8]

Historically, the Nd: YAG laser was first used in dentistry in the 1980s. Over time, it has gained popularity due to its ability to treat or wide range of oral conditions with fewer trauma and pain for patients. [4-6]

Possibilities of using the Nd: YAG laser (neodymium-yag) in the oral cavity:

Treatment of periodontitis: The Nd: YAG laser can be used to treat periodontitis, an inflammatory condition of the gingival and alveolar tissue that supports the teeth. It can remove bacteria and infected tissue around the teeth, helping to reduce inflammation and heal affected tissues. [6-9]

Oral surgery: The Nd: YAG laser can be used to remove lesions or abnormal tissues from the oral cavity, such as cysts or benign tumors. It can also be used to help with tooth extraction or to create precise incisions in cases of complex oral surgery. [4-6]

Treatment of canker sores and ulcers:

This type of laser can accelerate the healing of canker sores and ulcers in the oral cavity by reducing inflammation and stimulating local blood circulation.

Radical cyst treatment: The Nd: YAG laser can be used to treat root cysts, which are cavities filled with fluid around the roots of the teeth. The laser can help clean the cyst and sterilize the area to prevent recurrence. [9-14]

Gingivectomy: The Nd: YAG laser can be used to remove excess gingival tissue in the case of gingivectomy, a procedure used to correct gingivitis or to create a smile aesthetic. [10-14]

MATERIALS AND METHOD

The patient presented herself in the surgery service, with aesthetic discomfort regarding severe gingival hypertrophy, with an

impediment to what home hygiene maneuvers mean.

A periodontal diagnostic procedure followed which placed it in stage IV of grade c periodontitis. The 50-year-old patient is in therapy with enalapril - atenolol - serein-Norvasc.

Treatment was provided for non-surgical periodontal ultrasound instrumentation for removal of the subgingival tartar and neodimio-yag laser treatment with nanosecond pulses of the subgingival medium under irrigation with alternative betadine with hydrogen peroxide with parameters set at 20 Hz, 1.5 watts for 90 seconds each settler below hydrogen-betadine betadine-peroxide irrigation.

The control photo was a girl After 30 days, at home, it was recommended to apply ozone alternated with peribiom musse.

RESULTS AND DISCUSSIONS

It is important to mention that achieving the success of Nd: YAG laser treatment may vary depending on the individual case and the medical qualifications dentist performing the procedure. Before deciding on any therapy, it is recommended to talk to your dentist for information on treatment options, benefits, and risks.

Nd laser: YAG (neodymium-yag) is a type of laser used in dental treatments and especially in gingival hyperplasia therapy. Gingival hyperplasia refers to excessive growth of gingival tissue, which can lead to swelling and inflammation of the gums. Nd: YAG laser can be used to treat this condition through techniques to reduce excessive gingival tissue.

Here's how Nd: YAG laser treatment works in gingival hyperplasia therapy:

Preparation: Before starting treatment, the dentist will assess the condition of the gums and determine if Nd: YAG laser therapy is suitable for the patient. It is important to talk about your expectations and the procedure itself.

Anesthesia: Local anesthesia is usually used to ensure patient comfort during laser treatment.

Laser use: The Nd: YAG laser emits a high-energy light that can be directed to the affected gum tissues. It can have multiple beneficial effects:

Tissue vaporization: The laser can vaporize excessive or inflamed gingival tissue in a controlled way without causing significant bleeding or pain.

Coagulation of blood vessels: The laser can clot the blood vessels as it acts, minimizing bleeding during and after the procedure.

Curing Stimulation: Laser radiation can stimulate the healing and regeneration processes in treated tissues.

Post-treatment: After treatment, the gums may be less sensitive and may have temporary swelling. Your doctor will give you instructions for post-treatment care, which may include avoiding hard food and hot drinks for a lifetime.

Follow-up visits: Depending on the severity of gingival hyperplasia and response to treatment, follow-up visits may be required to monitor developments and ensure the success of procedures.

Image 1. Nd: YAG laser, its use is safe in oral pathology - gingival hyperplasia



Nd: YAG laser (neodymium-yag) can be used in gingival hyperplasia therapy to treat and reduce excessive growth of gingival tissue. This procedure has some benefits and potential side effects, which should be considered:

Benefits of Nd: YAG laser therapy in gingival hyperplasia:

Accuracy: The Nd: YAG laser can be precisely directed to the affected area without affecting the surrounding healthy tissues.

Minimizing bleeding: The laser has the ability to clot the blood vessels as it treats the tissue, which can lead to reduced bleeding during and after the procedure.

Discomfort reduction: In many cases, patients report less discomfort during and after laser treatment compared to traditional surgical techniques.

Faster healing: Laser tissue stimulation can help speed up the healing and regeneration process.

Potential side effects or complications:

Temporary sensitivity and pain: After laser treatment, the gums may become temporarily sensitive and may cause mild pain or discomfort. These symptoms usually improve in a few days.

Temporary swelling: Some swelling and inflammation may occur after treatment, but they usually resolve on their own shortly.

Darker temporary gum color: In the first days after treatment, a darker shade of the gums may occur, but this will gradually fade.

Recurrence: In severe forms of gingival hyperplasia, cases of recurrence may occur, where excess gingival tissue may recur over time.

Rare infections or complications: Although rare, there is a low risk of infections or other complications, as is the case in any medical procedure.

Figure 2. In the initial case, the frontal norm

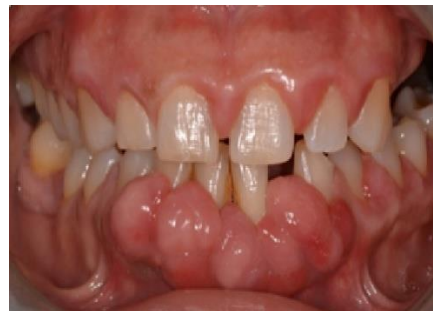

Figure 3. In the initial case, the lateral norm page

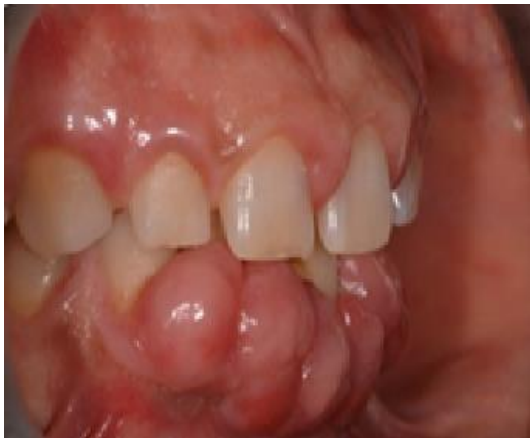

Figure 4. Rx retroalveolar mandibular radiographs

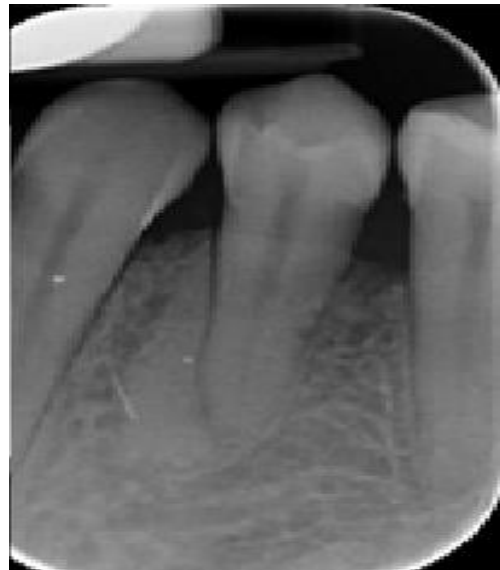

Figure 7. In the final case after laser treatment, the front-time page

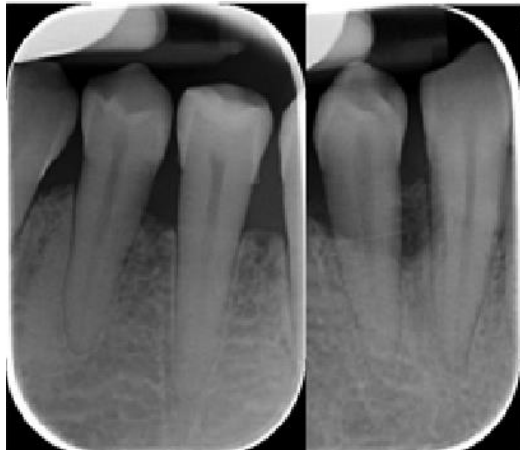

Figure 5. Rx retroalveolar mandibular radiographs

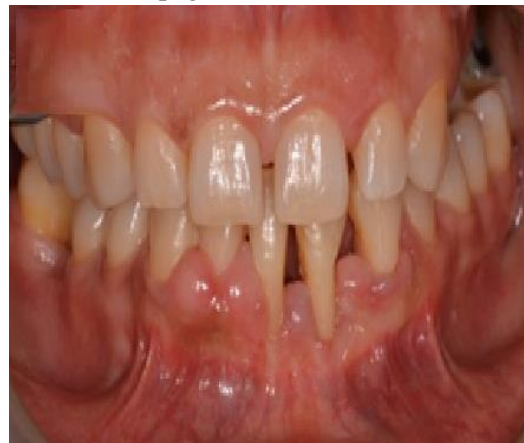

Figure 8. In the final case after laser treatment, the lateral norm page

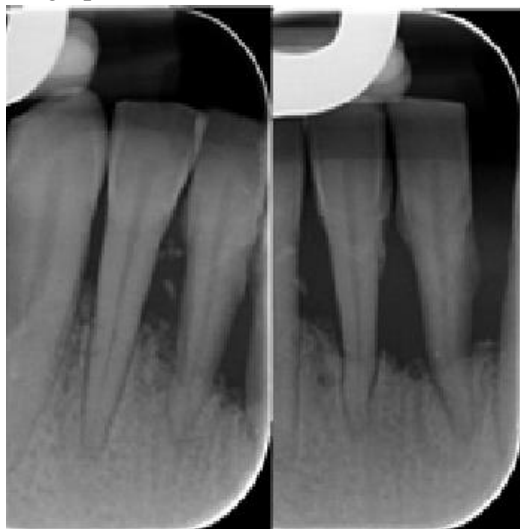
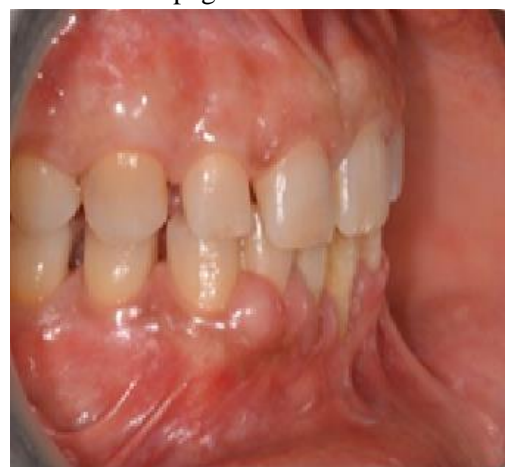

Figure 6. Rx retroalveolar mandibular radiographs



About oral health in general, it is important to continue to follow good oral hygiene practices:

Dental brushing: Dental brushing is a fundamental principle of oral hygiene and plays a key role in maintaining dental health. Performed regularly and correctly, thus helping to remove the bacterial plaque, preventing tooth decay, gum disease, and other dental conditions. Here is some important information about dental brushing and the right techniques:

Dental brushing frequency: It is recommended to brush your teeth at least twice a day: in the morning and the evening, after meals. [13-16]

After-dinner brushing is especially important, as leftover food can ferment at night and lead to the development of cavities. **Correct brushing technique:** Choosing the right tool: Use a toothbrush with soft or medium hairs. If you have been advised by a dentist, you can also choose a smaller toothbrush to reach the hard-to-reach areas more easily. [13-16]

Using fluoride toothpaste: Choose a toothpaste with a suitable fluoride content. Apply a small amount (the size of a pea) on the toothbrush. **Brushing technique:** Brush positioning: Maintain the toothbrush at an angle of approximately 45 degrees to the gingival line. [13-16]

Delicate movements: Use light and circular movements to clean the outer and inner surfaces of the teeth. Do not press too hard to avoid damage to the enamel and gums.

Language cleaning: After brushing, you can also clean your tongue with a tongue toothbrush or the back of your toothbrush.

Muscat surface cleaning (occlusal): For rear teeth (molars and premolars), use forward and backward movements to clean their biting surface. **Using dental floss:** To clean the spaces between your teeth, floss. Wrap the thread around the middle fingers and use delicate sliding movements between the teeth. Be sure to touch each tooth and do not force the thread into space to avoid damage to the gums. [13-16]

Brushing time: The brushing should take at least two minutes to effectively clean all dental surfaces. [13-16]

Toothbrush change: Replace the toothbrush every 3-4 months or when the hair is damaged. Even if rigorous oral hygiene is considered to be achieved, it is important to have scheduled regular visits to your dentist for professional examinations and cleansing.

Regular visits to the dentist: These regular visits to the dentist for routine dental examinations and professional cleansing can help prevent or treat any dental problems at an early stage. The evaluation of the general condition is equally important. [15-23]

Healthy eating: A balanced diet, rich in vegetables, fruits, and lean proteins, contributes to oral health. **Avoid harmful habits:** Avoid smoking and excessive alcohol consumption, as these habits can affect dental and oral health. It is indicated the continual of specialized surgical and periodontal treatments so that oral and tissue regeneration can be achieved. The importance of the need for a strong patient character and perseverance can bear fruit in the work of the dentist. [24-29]

CONCLUSIONS

Hormonal contraceptives can have some side effects in the oral cavity for some women. It is important to understand that each person may react differently to medications, and not everyone will have the same symptoms or side effects.

Nd: YAG laser can be precisely directed to the affected area without affecting the surrounding healthy tissues.

Nd: YAG laser can clot blood vessels as it treats tissue, which can lead to reduced bleeding during and after the procedure.

The results depend on the regularity and perseverance of the patient, so the need to maintain good rigorous oral hygiene through regular brushing, the use of dental floss, and regular visits to the dentist are necessary.

REFERENCES

1. Colquitt CW, Martin TS. Contraceptive methods. *J Pharm Pract.* 2017;30(1):130–5. PMID: 26033795 DOI: [10.1177/0897190015585751](https://doi.org/10.1177/0897190015585751)
2. Uhm S, Perriera L. Hormonal contraception as treatment for heavy menstrual bleeding: a systematic review. *Clin Obstet Gynecol.* 2014;57(4):694–717. PMID: 25314086 DOI: [10.1097/GRF.0000000000000061](https://doi.org/10.1097/GRF.0000000000000061)
3. Rivera R, Yacobson I, Grimes D. The mechanism of action of hormonal contraceptives and intrauterine contraceptive devices. *Am J Obstet Gynecol.* 1999;181(5 Pt 1):1263–9. PMID: 10561657 DOI: [10.1016/s0002-9378\(99\)70120-1](https://doi.org/10.1016/s0002-9378(99)70120-1)
4. Paul F. Bradley. A review of the use of the neodymium YAG laser in oral and maxillofacial surgery martie 1997, *British Journal of Oral and Maxillofacial Surgery* 35(1):26-35 DOI: [10.1016/S0266-4356\(97\)90005-X](https://doi.org/10.1016/S0266-4356(97)90005-X)
5. Abhishek Shrikant Soni, Shoeb Mujawar, Prasad Musale, Iqbal Musani . Use of Nd: YAG laser in the treatment of ankyloglossia for pediatric patient. January 2012 *Journal of Dental Lasers* 6(1):33, DOI:[10.4103/0976-2868.100989](https://doi.org/10.4103/0976-2868.100989)
6. Shraavan Renapurkar, Robert A. Strauss Lasers in Oral and Maxillofacial Surgery License [CC BY 4.0](https://creativecommons.org/licenses/by/4.0/) In book: *Oral and Maxillofacial Surgery for the Clinician* (pp.817-830) February 2021 DOI:[10.1007/978-981-15-1346-6_39](https://doi.org/10.1007/978-981-15-1346-6_39)
7. DS Park, HJ Lee, HM Yoo, Tae Seok Oh. Effect of Nd:YAG laser irradiation on the apical leakage of obturated root canals: An electrochemical study. July 2001, *International Endodontic Journal* 34(4):318-21 DOI:[10.1046/j.1365-2591.2001.00397.x](https://doi.org/10.1046/j.1365-2591.2001.00397.x)
8. F J H W Depraet, Mieke A A De Bruyne, Roeland De Moor. The sealing ability of an epoxy resin root canal sealer after Nd:YAG laser irradiation of the root canal. June 2005. *International Endodontic Journal* 38(5):302-9. DOI:[10.1111/j.1365-2591.2005.00948.x](https://doi.org/10.1111/j.1365-2591.2005.00948.x)
9. Hughes R., Lacour J.P., Passeron T. Pigmentary sequelae of AIDS-related cutaneous Kaposi sarcoma: Successful treatment by Q-switched 755-nm alexandrite and 532-nm Nd:YAG lasers. *Arch. Dermatol.* 2011;147:779–781. doi: [10.1001/archdermatol.2011.153](https://doi.org/10.1001/archdermatol.2011.153).
10. Olimpia Dumitriu Buzia, Ana Maria Păduraru, Claudia Simona Stefan, Monica Dinu Dorin Ioan Cocos, Lawrence Chukwudi Nwabudike and Alin Laurentiu Tatu, Strategies for Improving Transdermal Administration: New Approaches to Controlled Drug Release, *Pharmaceutics*, april 2023, 15(4):1183. <https://doi.org/10.3390/pharmaceutics15041183>
11. Sorana Maria Bucur, Cristina Raffanini Chiarati , Paola Avino, Ilaria Migliorino, Dorin Ioan Cocos, Eugen Silviu Bud, Anamaria Bud, Alexandru Vlasi. Retrospective study regarding the status of the superficial marginal periodontium in adult patients wearing orthodontic retainers *Romanian Journal of Oral Rehabilitation* Vol. 13, No. 2, April – June 2021
12. Sorana Maria Bucur, Laszlo Barna Iantovics, Anamaria Bud, Eugen Silviu Bud, Dorin Ioan Cocos, and Alexandru Vlasi Retrospective Study Regarding Orthodontic Retention Complications in Clinical Practice *MDPI Appl. Sci.* 2022, 12, 273. <https://doi.org/10.3390/app12010273>
13. Nasca M.R., Luppino I., Micali G. Kaposi's Sarcoma-Related Lymphedema Treated by a Nd:YAG Laser. *Dermatol. Surg.* 2021;47:1139–1140. doi: [10.1097/DSS.0000000000002904](https://doi.org/10.1097/DSS.0000000000002904).
14. Greve, B., Raulin, C. Der Nd:YAG-Laser im Wandel der (Impuls-) Zeiten – Einsatzgebiete in der Dermatologie. *Hautarzt* **51** , 152–158 (2000). <https://doi.org/10.1007/s001050051096>
15. Puisoru, M., Forna, N., Fatu, A.M. Fatu, R., Fatu, C. , Analysis of mandibular variability in humans of different geographic areas, *Annals of anatomy-anatomischer anzeiger*, Volume 188, Issue 6, 2006, Page. 547-554
16. Iordache C, Antohe M-E, Chiriac R, Ancuța E, Țănculescu O, Ancuța C. Volumetric Cone Beam Computed Tomography for the Assessment of Oral Manifestations in Systemic Sclerosis: Data from an EUSTAR Cohort. *Journal of Clinical Medicine.* 2019; 8(10):1620. <https://doi.org/10.3390/jcm8101620>

17. Gurau, G., Dinu, C.A., Earar, K. Voicu, D.C., Botezatu, D., Diagnostic Value of Chemical and Hematological Markers in Children Acute Abdominal Pain, Mar 2016, Revista De Chimie 67 (3), pp.507-511
18. Ancuta, C., Ancuta, E., Chirieac, R., Antohe, M., Iordache, C., Anti-Tumor Necrosis Factor Alpha Therapy and Periodontal Inflammation in Rheumatoid Arthritis A clinical and biochemical approach, Feb 2017, Revista De Chimie 68 (2), pp.369-372
19. Alexandru Vlasa, Eugen Silviu Bud, Mariana Păcurar, Luminița Lazăr, Laura Streiche, Sorana Maria Bucur, Dorin Ioan Cocoș and Anamaria Bud Effects of Composite Resin on the Enamel after Debonding: An In Vitro Study—Metal Brackets vs. Ceramic Brackets, MDPI. Appl. Sci. 2021, 11, 7353. <https://doi.org/10.3390/app11167353>
20. Croitoru, I.C., Craitoiu, S., Petcu, C.M., Mihailescu, O.A., Pascu, R.M., Bobic, A.G., Fornă, D.A., Craitoiu, M.M., Clinical, imagistic and histopathological study of chronic apical periodontitis, 2016, Romanian Journal Of Morphology And Embryology 57 (2), pp.719-728
21. Ciurcanu, O.E., Fornă, D.A., Popa, C., Scutariu, M.M., Implementation of methods of loco-regional anesthesia in dental surgery, Oct-dec 2017, Romanian journal of oral rehabilitation 9 (4), pp.120-127
22. Taranu, T., Constantin, M.M., Toader, M.P., Esanu, I., Mocanu, M., The Benefits of Using the Iodine Solution in the Treatment of Acne at Pregnant Women, Sep 2018, Revista de chimie 69 (9), pp.2343-2345
23. Balan, A., Savin, C., Balan, G.G., Zetu, I., Health Protection and International Relations. A Postmodernist Approach, Jun 2014, Revista De Cercetare Si Interventie Sociala 45, pp.160-174
23. Bolat, M., Nicolae, B.D., Baci, E.R., Fornă, D.A., Bosinceanu, D.G., Fornă, N.C., Partial dentures-successes and failures, Romanian Journal Of Oral Rehabilitation, Volume 9, Issue 4, 2017, Page 93-96
24. Martina Silvestri, Alessandra Latini, Ilaria Lesnoni La Parola, Claudia Messina, Steven Paul Nisticò and Norma Cameli. Effectiveness and Safety of Treatment with Neodymium:YAG Laser 1064 nm in Patients with Classic and Epidemic Kaposi Sarcoma. Bioengineering (Basel). 2022 Mar; 9(3): 106. doi: [10.3390/bioengineering9030106](https://doi.org/10.3390/bioengineering9030106)
25. Vasluianu, R., Fornă, D.A., Zaltariu, M., Murariu, A., In vitro Study Using ATR-FTIR Methode for Analyze the Effects of the Carbamide Peroxide on the Dental Structure, Dec 2016, Revista de chimie 67 (12), pp.2475-2478
26. Strauss RA, Coleman M. Lasers in major oral and maxillofacial surgery. In: Convissar R, editor. Principles and practice of laser dentistry. 2nd ed: Elsevier Health Sciences; 2016. p. 234–50.
27. Budacu, C.C., Ioanid, N., Romanec, C., Balan, M., Pavel, L.L., Pacurar, M., Rosu, S., Dental Inclusion of Canine and Wisdom Tooth in Orthodontics Chemical Necroses, Aug 2018, Revista de Chimie, 69 (8), pp.2191-2196
28. Anil Patel. Chapter 40 - Anesthesia for Laser Airway Surgery. Benumof and Hagberg's Airway Management (Third Edition) 2013, Pages 824-858.e4. <https://doi.org/10.1016/B978-1-4377-2764-7.00040-3>