

OPTIMIZING WOUND CARE: THE IMPORTANCE OF NEGATIVE PRESSURE WOUND THERAPY FOR VARIOUS ETIOLOGIES AND LOCALIZATIONS

Madalina Cristina Fotea¹, Dorin Sumanaru¹, Dan Cristian Moraru^{1,2}, Stefana Luca^{1,2},
Oxana Madalina Grosu^{1,2}, Alexandru Tomac¹, Teodor Rosca¹, Laura Bozomitu²,
Alexandru Amarandei¹, Mihaela Pertea^{1,2}

¹ Department of Plastic Surgery and Reconstructive Microsurgery, "Sf. Spiridon" Emergency County Hospital, Iasi, Romania

² "Grigore T. Popa" University of Medicine and Pharmacy Iasi, Romania

Corresponding author; Stefana Luca, e-mail: stefana.luca@d.umfiasi.ro

ABSTRACT

Aim of the study This study aims to investigate the efficacy of Negative Pressure Wound Therapy (NPWT) in optimizing wound care across a diverse range of etiologies and localizations. **Material and methods** A study of 97 patients with various wound etiologies and localizations was conducted. NPWT was meticulously applied according to established protocols, with treatment parameters being methodically documented. **Results** NPWT exhibited substantial efficacy in promoting wound healing across varied etiologies and localizations. Acute wounds demonstrated reduced dimensions alongside enhanced granulation tissue formation. In parallel, chronic wounds exhibited improved wound bed preparation and diminished bacterial colonization. **Conclusions** NPWT proves to be a versatile and effective treatment modality for optimizing wound care across different etiologies and localizations. Its ability to improve wound healing outcomes, by enhancing tissue perfusion, reducing edema, and modulating inflammation, positions NPWT as a valuable tool in comprehensive wound management strategies. Its ability to enhance tissue perfusion, mitigate edema, and modulate inflammation underscores its value as a pivotal tool within comprehensive wound management strategies.

Key words: wound care, NPWT, healing

INTRODUCTION

Negative Pressure Wound Therapy (NPWT) stands as a pivotal advancement in contemporary wound care, constituting a non-invasive technique that uses subatmospheric pressure to facilitate wound healing. This therapeutic approach, generating pressures ranging from 50 to 150 mm Hg through continuous or intermittent application facilitates drainage of wound secretions and enhances tissue perfusion (1). The skin's structure is made up of an intricate network which serves as the body's initial barrier against pathogens, UV light, and chemicals, and mechanical injury (2). Wound healing is a

natural physiological reaction to tissue injury. However, wound healing is not a simple phenomenon (3). Although often difficult to treat, an understanding of the underlying pathophysiology can often lead to successful healing (4). NPWT holds the potential to stimulate wound contraction and promote the proliferation of granulation tissue, thus orchestrating a comprehensive mechanism for expedited tissue repair (5, 6). The overall success of negative pressure wound therapy has led to a multitude of clinical applications (7, 8, 9, 10).

The evolution of NPWT has its roots dating back to the early centuries; however, it was in

1997 that a significant leap occurred in the advancement of NPWT when Louis Argenta and Michael Morykwas shared their extensive research. Their pioneering work encompassed a diverse range of wounds, including 175 chronic wounds, 94 subacute wounds, and 31 acute wounds, spanning over a remarkable 9-year period (11).

This pivotal contribution by Argenta and Morykwas laid a solid foundation for NPWT's clinical integration and further research, generating a transformative era in wound care practices.

The clinical significance of NPWT transcends its origin, evolving into a versatile modality applicable to diverse etiologies and wound types. The evidence that supports the benefits of NPWT in improving healing, as an adjunctive therapy, in the management of difficult open wounds, has been widely described in literature (12,13,14,15). Its diverse applications extend across a variety of surgical specialties, including vascular, digestive, thoracic, and spinal surgeries, as well as addressing burns, infections and even maxillofacial surgery. Acknowledging the range of its clinical utility, the European Wound Management Association (EWMA) highlights a substantial number of publications evidencing its effectiveness across various contexts (16).

The aim of this study is to comprehensively assess the role of NPWT in the management of wounds originating from varied etiologies, encompassing both acute and chronic manifestations. By meticulously investigating 97 patients presenting with a spectrum of wound types, we aim to elucidate the efficacy, parameters, and outcomes associated with NPWT application.

MATERIAL AND METHODS

The study group included 97 patients, 65 males and 32 females, who underwent treatment between January 2018 and January

2023 (Table 1). Informed consent was obtained from all patients in the study group. The study inclusion criteria included individuals aged 18 years and above, presenting with diverse acute and chronic wound types. Patients presenting with acute lesions underwent an initial surgical intervention involving primary surgical debridement and subsequent reconstruction of affected structures. All acute patients underwent surgical interventions, under general or loco-regional anesthesia. These procedures included debridement, necrectomy of devitalized tissues, and escharectomy. In instances of highly contaminated wounds, a multi-stage surgical cleaning was performed. In all cases, bacterial samples were collected for examination, and patients subsequently received antibiotic treatment based on the antibiogram results. This encompassed osteosynthesis procedures for injuries affecting the lower limb and hand bones, while tenorrhaphies and myorrhaphies were performed for upper limb trauma cases. In instances of severe infections, an incision was carried out to evacuate purulent collections, followed by daily lavage. Similarly, catheter-related thrombophlebitis cases underwent necrectomy and lavage procedures. For patients with chronic lesions, surgical intervention was carried out under general anesthesia with orotracheal intubation. A preceding wound debridement and lavage regimen was conducted, accompanied by controlled bleeding of the area designated for NPWT application. The lavage procedure for NPWT site preparation involved sequential application of hydrogen peroxide, betadine, and physiological saline solution. Application of NPWT was conducted utilizing continuous suction. The subatmospheric pressure settings were individually adjusted, considering the anatomical region and patient tolerance, within the range of -90 mm Hg to -120 mm Hg.

Dressing changes were performed at intervals of 3 to 4 days. In all cases, polyurethane foam was utilized as the wound filler material. Instances involving the presence of microbial flora during NPWT application prompted concurrent implementation of targeted systemic antibiotic therapy. Patient evaluation and monitoring encompassed comprehensive laboratory investigations, including blood and wound secretion analyses. Furthermore, the appearance and dimensions of wounds were meticulously documented during each dressing change, involving photographic documentation, direct measurements, and microbiological evaluation of secretions

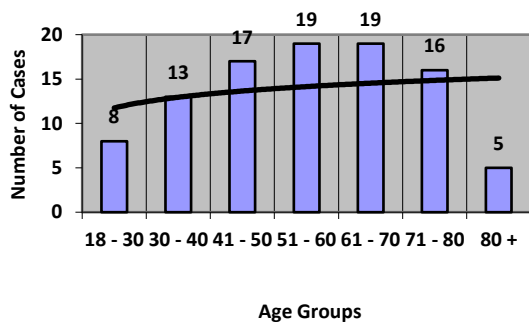


Figure 1. Age Distribution

obtained from the wounds.

RESULTS AND DISCUSSIONS

The current study comprised a group of 97 patients, including 65 males and 32 females, all presenting with soft tissue defects of varying etiologies and localizations.

Age distribution

The average age of the patients was approximately 51.82 years, ranging from 26 to 86 years (Fig. 1).

Gender distribution

The gender distribution revealed a predominance of male patients, accounting for around 67.03% of the study, resulting in a male-to-female ratio of about 2.03125 (Fig. 2).

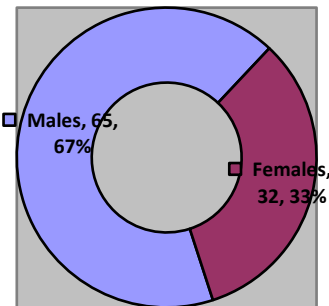


Figure 2. Gender Distribution

Wound etiologies

Patients were systematically categorized into distinct diagnostic groups, characterized by both acute and chronic conditions (Table 1). Within the subset of acute cases (n=62), the largest subgroup consisted of trauma-related cases, constituting roughly 67.74% of the study. This subgroup included bite wounds (17.74%), crush injuries (19.35%), compartment syndrome (11.29%), and open fractures (19.35%). Infections were responsible for 8.06% of acute cases, with specific conditions including fasciitis (3.23%) and catheter-related thrombophlebitis

(4.84%). Additionally, burns constituted 24.19% of the acute cases. Conversely, the subset of chronic cases (n=35) comprised about 42.86% of ulcers. Vascular ulcers constituted 20%, neuropathic ulcers contributed 5.71%, and pressure ulcers (Fig. 3) were observed in 17.14% of cases. Notably, post-excision tumors represented a significant proportion, accounting for 57.14% of the chronic cases. The inclusion of various acute and chronic cases demonstrates the utility of NPWT across a diverse spectrum of wound etiologies.

Table 1. Patient data

	Type	Diagnostic	No of Cases	Mean Age	Localization
Acute Cases 62 cases	Trauma 42 cases	Bite Wounds	7 M 4 F	36	Upper & Lower Limb
		Crush Injuries	9 M 3 F	39	
		Compartment Syndrome	5 M 2 F	42	
		Open Fractures	9 M 3 F	38	
	Infection 5 cases	Fasciitis	1 M 1 F	58	Upper & Lower Limb
		Catheter-related Thrombophlebitis	2 M 1 F	62	
Burns 15 cases			12 M 3 F	48	Upper & Lower Limb, Thorax
Chronic Cases 35 cases	Ulcers 15 cases	Vascular	3 M 5 F	67	Upper & Lower Limb, Ischial Tuberosity, Sacrum
		Neuropathic	1 M 1 F	62	
		Pressure	4 M 1 F	69	
	Tumor Excision 20 cases		12 M 8 F	49	

Associated medical conditions

In this study, the patient group exhibited the subsequent associated medical conditions: arterial hypertension (38 cases), diabetes mellitus (12 cases), chronic heart diseases (8 cases), obesity (12 cases), alcohol or tobacco utilization (73 cases), and other conditions, specifically liver disease (9 cases). Out of the total 97 patients examined, 79.56% presented associated medical conditions, which included both specific diseases or instances of alcohol or tobacco usage. Within this subset, 75.26% of patients engaged in alcohol or tobacco use.

Furthermore, 39.18% of patients displayed arterial hypertension. These observations demonstrate the diverse range of associated conditions within the study, highlighting the multifaceted medical considerations that warrant comprehensive assessment in clinical contexts.

Surgical management

The distribution of treatments among the patients in our study, totalling 97 cases, was as follows. Acute cases (62 cases) (fig. 3) and ulcers (fig. 4) (15 cases) underwent primary surgical care and debridement (79 cases, 81.44%), while necrectomy was performed in 47 cases. Osteosynthesis was conducted in 25 cases (25.77%) and tenorrhaphies were carried out in 29 cases (29.90%). All patients diagnosed with tumor-like lesions underwent complete removal of the tumor, while adhering to established protocols for safe margins removal.

The wound defects were managed through various techniques: 40 cases were covered with split-thickness skin graft (STSG), constituting around 41.24% of the patients, 27 cases underwent flap procedures, representing approximately 27.84% of the patients, and the remaining cases followed

secondary intention wound healing.

NPWT application

The average duration of Negative Pressure Wound Therapy (NPWT) utilization was 6.9 average duration was 6.5 days. Dressing changes were most commonly performed every 3 days (80% of cases), with a mean frequency of 3.01 days. The applied negative

days, with a range of 3 to 15 days (Fig. 5). For cases involving NPWT after free split-thickness skin grafts, the

pressure level averaged at -110.43 mmHg, ranging from -90 mmHg to -120 mmHg. The mean length of hospital stay was 17.37 days, ranging from 7 to 42 days (Fig. 6).

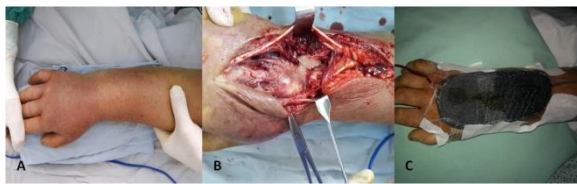


Figure 3. Septic arthritis of the wrist. A. Preoperative aspects B. Intraoperative aspects C. Negative Pressure Wound Therapy

Complications

Patient-reported pain during NPWT device installation and subsequent dressing changes emerged as the primary complication, affecting approximately 45% of the participants. While this discomfort was transient and generally tolerable, it emphasized the significance of addressing patient comfort. Interestingly, a considerable majority, about 82% of the patients, reported minimal to no pain during the NPWT treatment period, indicating that the overall benefits of wound healing often outweighed this temporary inconvenience. It's crucial to note that adherence to established NPWT guidelines played a pivotal role in maintaining low complication rates. Instances of wound infection were observed in only 7% of the cases, underscoring the importance of aseptic techniques during device application and management. Furthermore, bleeding was noted in a

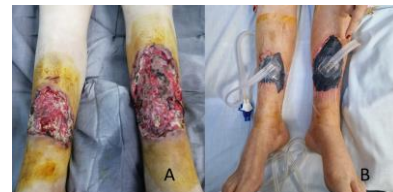

Figure 4. Bilateral leg ulcers. A. Preoperative aspects B. Negative Pressure Wound Therapy

relatively low proportion of cases, occurring in less than 10% of the patients. This incidence demonstrated the importance of careful wound assessment prior to NPWT initiation, as well as the need for regular monitoring during treatment to promptly address any signs of bleeding. Our findings unequivocally demonstrate that when NPWT is implemented judiciously, it can be a potent tool in wound healing. Nonetheless, it is imperative upon healthcare practitioners to exercise prudence in patient selection, adhere to application protocols, and diligently monitor for any adverse effects.

Data analyse

We conducted ANOVA Regression analyses for various combinations of variables our dataset of n=97 patients. For the relationship between the duration of NPWT utilization and the level of applied negative pressure, the obtained correlation coefficient was approximately 0.1689, indicating a weak correlation. The associated p-value was 0.065

(significance $F = 0.065$), just missing the conventional threshold for statistical significance ($\alpha = 0.05$).

Table 2. NPWT application

Variables	Mean	Min.	Max.
Length of use (days)	6.9	3	15
Frequency of NPWT change (days)	3.01	1	4
Value of negative pressure (mm Hg)	-110.43	-90	-120
Hospitalization (days)	17.37	7	42

When examining the interplay between patient age and the duration of NPWT, a correlation coefficient of about 0.2363 (weak to moderate correlation) was observed. The corresponding p-value was 0.006 (significance $F = 0.006$), which achieved statistical significance.

Furthermore, analyzing the relationship between age and the level of applied negative pressure yielded a correlation coefficient of approximately 0.1761 (weak correlation). The associated p-value was 0.05 (significance $F = 0.05$), again approaching the boundary of statistical significance.

In terms of the correlation between age and the length of hospital stay, a correlation coefficient of around 0.2245 (weak to moderate correlation) was identified. The corresponding p-value was 0.043 (significance $F = 0.043$), indicating a statistically significant relationship.

The comprehensive examination of the collected data reinforces the significant efficacy of NPWT in assisting wound healing across a diverse spectrum of etiologies and anatomical locations. The study's group of 97

patients encompassed a wide range of etiologies, including acute and chronic wounds. Notably, the average duration of NPWT utilization was 6.9 days, with a range spanning from 3 to 15 days. This variation in treatment duration points towards the adaptability of NPWT to different wound types and healing trajectories. Acute wounds showcased a distinct evolution of reduced wound dimensions. This was coupled with the notable development of granulation tissue, as evidenced between the 5th and 8th day, reflecting enhanced tissue formation. This suggests that NPWT fosters a conducive environment for acute wound healing, promoting both tissue regeneration and reduced wound dimensions. Meanwhile, chronic wounds exhibited substantial improvements in wound bed preparation. This pivotal aspect of wound healing was further supported by the values corresponding to NPWT application duration. These findings demonstrate NPWT's ability to create a favorable environment for wound bed preparation, thereby aiding in covering

techniques. Remarkably, the application of NPWT also contributed to a reduction in bacterial colonization within chronic wounds, as indicated by the data points associated with dressing change frequency. This reduction in bacterial colonization could be linked to the improved healing conditions facilitated by NPWT. Collectively, these findings highlight the multifaceted benefits of NPWT, as

observed in both acute and chronic wound scenarios. Our data demonstrates its role in expediting wound healing by promoting granulation tissue formation, minimizing wound dimensions, and improving wound bed conditions. This demonstrates NPWT's significance as an effective strategy in the management of various wound etiologies and anatomical localizations.

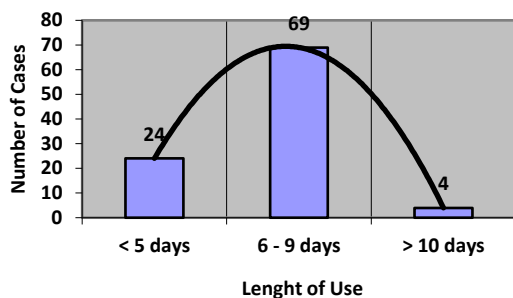


Figure 5. NPWT Length of use

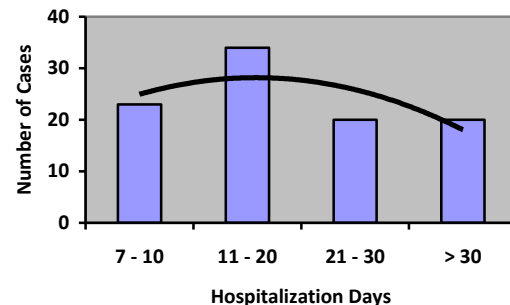


Figure 6. Hospitalization days

CONCLUSIONS

Negative Pressure Wound Therapy (NPWT) offers multiple advantages that contribute to enhanced patient comfort and efficient wound management (17, 18). One notable benefit is the reduced frequency of dressing changes, which alleviates the associated pain often experienced by patients. This approach also minimizes the need for repeated surgical interventions, leading to decreased procedural complexity. Notably, NPWT holds promise in cases where the general health condition of the patient precludes extensive reconstructive procedures, potentially offering an alternative to limb amputation. Recent advancements in NPWT

technology have further enhanced patient experience. Compact, single-use devices have gained prominence, underscoring the commitment to patient comfort and convenience (19). Although some discomfort may arise during device installation and subsequent dressing changes, overall complications are rare when adhering to established usage guidelines (20). The efficacy of NPWT extends beyond wound care, finding applications in various medical domains (21, 22, 23, 24, 25). Its effectiveness has been noted in conservative therapy for conditions like gastrointestinal fistulas, broadening its scope beyond wound healing (26). In the comprehensive assessment of NPWT, it is

imperative to consider the potential influence of concomitant diseases and patient conditions. Negative Pressure Wound Therapy (NPWT) has emerged as a highly effective and versatile approach in the wound healing process across various etiologies. This innovative technique, known for its ability to accelerate tissue repair, reduce infection risk, and enhance overall patient outcomes, has found its place in the treatment of wounds stemming from different causes. Innovative approaches and novel tools continue to reshape our understanding and treatment paradigms in various medical fields (27, 28, 29, 30). While

NPWT is a dedicated wound care approach, its overarching principles of healing, infection control, and tissue regeneration align with the broader trends in medical research (30). This synergistic evolution between wound care and other medical disciplines reinforces the notion that advancements in one area can have far-reaching implications for overall healthcare. As we look forward, we anticipate further breakthroughs. Overall, the integration of NPWT into diverse medical fields signifies its immense potential for advancing patient care and improving health outcomes across a spectrum of clinical scenarios.

Acknowledgements

REFERENCES

1. Webster J, Liu Z, Norman G, Dumville JC, Chiverton L, Scuffham P, Stankiewicz M, Chaboyer WP. Negative pressure wound therapy for surgical wounds healing by primary closure. *Cochrane Database Syst Rev.* 2019 Mar 26;3(3):CD009261. doi: 10.1002/14651858.CD009261.pub4. Update in: *Cochrane Database Syst Rev.* 2020 May 1;5:CD009261. PMID: 30912582; PMCID: PMC6434581.
2. Yousef H, Alhajj M, Sharma S. StatPearls [Internet]. StatPearls Publishing; Treasure Island (FL): Nov 14, 2022. Anatomy, Skin (Integument), Epidermis.
3. Wallace HA, Basehore BM, Zito PM. StatPearls [Internet]. StatPearls Publishing; Treasure Island (FL): Mar 7, 2023. Wound Healing Phases.
4. Frykberg RG, Banks J. Challenges in the Treatment of Chronic Wounds. *Adv Wound Care (New Rochelle).* 2015 Sep 01;4(9):560-582
5. Zaver V, Kankanalu P. Negative Pressure Wound Therapy. 2022 Sep 9. In: StatPearls [Internet]. Treasure Island (FL): StatPearls Publishing; 2023 Jan-. PMID: 35015413.
6. Huang C, Leavitt T, Bayer LR, Orgill DP. Effect of negative pressure wound therapy on wound healing. *Curr Probl Surg.* 2014 Jul;51(7):301-31.
7. Thompson JT, Marks MW. Negative pressure wound therapy. *Clin Plast Surg.* 2007 Oct;34(4):673-84.
8. Meloni M, Izzo V, Vainieri E, Giurato L, Ruotolo V, Uccioli L. Management of negative pressure wound therapy in the treatment of diabetic foot ulcers. *World J Orthop.* 2015 May 18;6(4):387-93
9. Mitrea M, Al Hage WE, Saveanu CI, Hurjui LL, Niculescu S. Review of literature concern reconstruction of the mandible and the maxilla-past, present and future *Romanian Journal of Oral Rehabilitation* 2020, 12(3):115-123.
10. Cai SS, Gowda AU, Alexander RH, Silverman RP, Goldberg NH, Rasko YM. Use of negative pressure wound therapy on malignant wounds - a case report and review of literature. *Int Wound J.* 2017 Aug;14(4):661-665.
11. Argenta L.C., Morykwas M.J. Vacuum-assisted closure: a new method for wound control and treatment: clinical experience. *Ann Plast Surg.* 1997;38:563-576.
12. Bovill E, Banwell PE, Teot L, Eriksson E, Song C, Mahoney J, Gustafsson R, Horch R, Deva A,

- Whitworth I, International Advisory Panel on Topical Negative Pressure . Topical negative pressure wound therapy: a review of its role and guidelines for its use in the management of acute wounds. *Int Wound J* 2008;5:511–29
13. Agarwal P, Kukrele R, Sharma D. Vacuum assisted closure (VAC)/negative pressure wound therapy (NPWT) for difficult wounds: A review. *J Clin Orthop Trauma*. 2019 Sep-Oct;10(5):845-848. doi: 10.1016/j.jcot.2019.06.015. Epub 2019 Jun 20. PMID: 31528055; PMCID: PMC6739293.
 14. Caro A, Olona C, Jiménez A, Vadillo J, Feliu F, Vicente V. Treatment of the open abdomen with topical negative pressure therapy: a retrospective study of 46 cases. *Int Wound J* 2011;8:274–9
 15. Scalise A, Calamita R, Tartaglione C, Pierangeli M, Bolletta E, Gioacchini M, Gesuita R, Di Benedetto G. Improving wound healing and preventing surgical site complications of closed surgical incisions: a possible role of Incisional Negative Pressure Wound Therapy. A systematic review of the literature. *Int Wound J*. 2016 Dec;13(6):1260-1281. doi: 10.1111/iwj.12492. Epub 2015 Oct 1. PMID: 26424609; PMCID: PMC7950088.
 16. Apelqvist J, Willy C, Fagerdahl AM, Fraccalvieri M, Malmjö M, Piaggese A, Probst A, Vowden P. EWMA Document: Negative Pressure Wound Therapy. *J Wound Care*. 2017 Mar 1;26(Sup3):S1-S154. doi: 10.12968/jowc.2017.26.Sup3.S1. Erratum in: *J Wound Care*. 2018 Apr 2;27(4):253. PMID: 28345371.
 17. Sîrbu, P.D.; Petreus, T.; Munteanu, F.; Perteau, M.; Lunca, S.; Poroach, V.; Botez, P. Clinical Experience with a Macroporous Synthetic Bone Substitute (Eurocer) in the Treatment of the Patients with Bone Defects. In Proceedings of the International Conference on Advancements of Medicine and Health Care through Technology IFMBE Proceedings 2011, Cluj-Napoca, Romania, 29 August–2 September 2011; Volume 36, pp. 358–368.
 18. Chiriac A, Grosu OM, Terinte C, Perteau M. Calcific uremic arteriolopathy (calciphylaxis) calls into question the validity of guidelines of diagnosis and treatment. *J Dermatolog Treat*. (2020) 31:545–8.
 19. Payne C, Edwards D. Application of the Single Use Negative Pressure Wound Therapy Device (PICO) on a Heterogeneous Group of Surgical and Traumatic Wounds. *Eplasty*. 2014 Apr 28;14:e20. PMID: 24917894; PMCID: PMC4006427.
 20. Norman G, Goh EL, Dumville JC, Shi C, Liu Z, Chiverton L, Stankiewicz M, Reid A. Negative pressure wound therapy for surgical wounds healing by primary closure. *Cochrane Database Syst Rev*. 2020 Jun 15;6(6):CD009261.
 21. Coroaba, A.; Chiriac, A.E.; Sacarescu, L.; Pinteala, T.; Minea, B.; Ibanescu, S.A.; Perteau, M.; Moraru, A.; Esanu, I.; Maier, S.S.; et al. New insights into human hair: SAXS, SEM, TEM and EDX for Alopecia Areata investigations. *PeerJ* 2020, 8, e8376.
 22. Negative Pressure Wound Therapy With Instillation: Review of Evidence and Recommendations. Kim PJ, Attinger CE, Crist BD, Gabriel A, Galiano RD, Gupta S, Lantis II JC, Lavery L, Lipsky BA, Teot L. *Wounds*. 2015 Dec;27(12):S2-S19.
 23. Perteau M, Velenciuc N, Grosu O, Veliceasa B, Poroach V, Lunca S. Reconstruction of heel soft tissue defects using sensate medial plantar flap. *J Mind Med Sci*. 2018; 5(2): 250-254.
 24. Mitrea M, Al Hage WE, Saveanu CI, Hurjui LL, Niculescu S. Review of literature concern reconstruction of the mandible and the maxilla-past, present and future *Romanian Journal of Oral Rehabilitation* 2020, 12(3):115-123.
 25. Anghel N, Melinte V, Spiridon I, Perteau M. Antioxidant, antimicrobial, and kinetic studies of B-cyclodextrin crosslinked with lignin for drug delivery. *Pharmaceutics*. 2022;14(11):2260. DOI:10.3390/pharmaceutics141122
 26. Grecu C, Grecu A, Serban IL, Hurjui I, Delianu C, Maranduca MA, Popovici D, Gradinaru I, Mitrea M, Hurjui, LL. Prevalence of nasal carriage of staphylococcus aureus with special reference to number of methicilin resistance and antimicrobial evaluation among apparently people with good health status. *Medical-Surgical Journal-Revista Medico-Chirurgicala* 2018, 122(4): 819-825.
 27. Huang C, Leavitt T, Bayer LR, Orgill DP. Effect of negative pressure wound therapy on

- wound healing. *Curr Probl Surg.* 2014 Jul;51(7):301-31.
28. Pertea M, Velenciuc N, Poroch V, Ciobanu P, Boanca M, Grosu OM, Lunca S. Efficacy of Negative Pressure Therapy (NPWT) in the Management of Wounds of Different Etiologies *REV.CHIM.(Bucharest)*, 69, No. 8, 2018
 29. Biermann N, Geissler EK, Brix E, Schiltz D, Muehle C, Prantl L, Taeger CD. Pressure distribution and flow characteristics during negative pressure wound therapy. *J Tissue Viability.* 2020 Feb;29(1):32-36.
 30. Paolini G, Sorotos M, Firmani G, Gravili G, Ceci D di Pompeo F. , Santanelli
Low-vacuum negative pressure wound therapy protocol for complex wounds with exposed vessels. *J Wound Care.* 2022 Jan 2;31(1):78-85.