

EFFECTS OF INSULIN PUMPS ON DIABETIC RETINOPATHY: A REVIEW

Geanina Totolici^{1,2}, Șerban Cristina³, Carmen Tiutiuca^{1,3}, Kamel Earar⁵, Dana Tutunaru^{4,5}

¹ Ophthalmology Department, County Emergency Clinical Hospital Saint Apostol Andrei, 800578 Galati, Romania

² University Assistant at "Dunarea de Jos" University, Faculty of Medicine and Pharmacy, Surgical Department, 800010, Galati, Romania

³ Professor at "Dunarea de Jos" University, Faculty of Medicine and Pharmacy, Surgical Department, 800010, Galati, Romania

⁴ Laboratory Medicine Department, County Emergency Clinical Hospital Saint Apostol Andrei, 800578 Galati, Romania

⁵ Professor at "Dunarea de Jos" University, Faculty of Medicine and Pharmacy, Pharmaceutical Sciences Department, 800010 Galati, Romania

Corresponding authors: Kamel Earar, E-mail: cristinagl86@yahoo.com
Carmen Tiutiuca, E-mail: tiutiuca_carmen@yahoo.com

ABSTRACT

With a global prevalence of 9,3% in 2019, diabetes causes eye damage, known as diabetic retinopathy, a microvascular complication and one of the leading causes of decreased visual acuity or blindness worldwide. The development of a new technology in the management of diabetes, either insulin pumps, continuous glucose monitoring devices (CGM) or augmented sensor pump therapy (SAP), has the advantage of reducing the variability in blood sugar levels, reducing of glycosylated hemoglobin levels and the episodes of severe hypoglycemia, thus increasing protection against complications such as diabetic retinopathy.

Despite such important benefits, medical devices for diabetes also presents adverse effects like allergic contact dermatitis (ACD), the most important allergens being isobornyl acrylate (IBOA), rosin, ethyl cyanoacrylate and N, N-dimethylacrylamide.

This review is focused on the beneficial effects of insulin pumps on diabetic retinopathy, but also on the negative effects of plastics that are part of medical devices for diabetes.

Keywords: insulin pump, diabetic retinopathy, isobornyl acrylate, allergic contact dermatitis

INTRODUCTION

Due to the growing number of patients with diabetes (DM), it has become a global public health problem.

Statistics from the World Health Organization (WHO) and the American Diabetes Association (ADA) show an increase in the number of patients with diabetes from 108 million in 1980 to 422 million in 2014[1]. The global prevalence of diabetes in 2019 was 9.3% (463 million

cases) and it is estimated to increase around 10.2% (578 million) by 2030 and 10.9% (700 million) by 2045 [1,2].

Diabetes over time leads to macrovascular complications such as coronary heart disease, peripheral arterial disease and stroke, but also to microvascular complications such as nephropathy, neuropathy and diabetic retinopathy. Thus, diabetes becomes a major cause of mortality and morbidity [3].

Diabetic retinopathy (RD) is a microvascular complication of diabetes and one of the leading causes of decreased visual acuity or blindness worldwide, having a major impact on the patient's quality of life on the one hand and for society on the other [3, 4].

Diabetic retinopathy is classified according to the International Clinical Disease Severity Scale (ICDSS) into five stages: no signs of diabetic retinopathy, non-proliferative diabetic retinopathy mild, moderate, severe and proliferative diabetic retinopathy. Diabetic macular oedema is a separate entity that can occur at any stage of diabetic retinopathy. Once established, diabetic macular ischemia causes an irreversible decrease in visual acuity, leading to blindness [5,6].

Epidemiological studies have shown that one in three patients diagnosed with any form of diabetes has diabetic retinopathy. Of the total number of patients with diabetes, 35% have some form of diabetic retinopathy, 7% have proliferative diabetic retinopathy, 7% have diabetic macular edema and 10% are in stages that threaten the irreversible loss of visual acuity. Worrying is the fact that about half of patients with diabetes remain for various reasons undiagnosed with RD [7].

Diabetic retinopathy is a microvascular complication and also one of the main causes of blindness worldwide, but which can be prevented by applying appropriate treatment of the underlying disease. Effective treatment of diabetes can prevent 90% of severe vision loss [8].

While certain risk factors for the development of RD, such as the period time since the onset of diabetes cannot be adjusted, controlling other modifiable risk factors such as glycemic status (blood sugar, glycosylated hemoglobin), hypertension, and

hyperlipidemia, is effective and essential for reducing blindness related to RD [9].

The discovery of insulin in 1922 was revolutionary for the treatment of diabetes. In recent years, new technologies such as continuous blood glucose monitoring systems (CGM) and insulin pumps (CSII) have improved the diagnosis, evolution and treatment of diabetes [10, 11].

The purpose of this review is to describe both the positive and negative effects of medical devices specially created for patients with diabetes, which have been identified in specialized clinical trials.

MATERIALS AND METHODS

This review is based on the study of specialized literature available in databases such as PubMed and Google Scholar using medical terms such as: “diabetic retinopathy”, “insulin pumps”, “angio-OCT”, “isobornyl acrylate”.

INSULIN PUMPS AND DIABETIC RETINOPATHY

The pathogenic mechanism involved in the development of diabetes mellitus is the deficiency of insulin secretion by the pancreas in the case of type I diabetes, or the insulin resistance of the body in the case of type II diabetes [12]

The treatment of diabetes was revolutionized with the discovery of insulin over 100 years ago. Insulin therapy is essential for type I diabetes and indispensable in many cases of type II diabetes. Today, there are approximately 8.3 million patients worldwide who inject insulin daily to regulate diabetes [10, 13].

Diabetic retinopathy is a microvascular complication of diabetes and one of the leading causes of significant decrease in visual acuity or even blindness

worldwide. Both experimental and clinical studies have shown the essential role of hyperglycaemia in the onset and evolution of RD [14].

Strict blood glucose control, along with regulating blood pressure and lipid levels, reduce the risk of developing and progressing RD. Therefore, cooperation between diabetologist and ophthalmologist is essential for the prevention and success of RD treatment [14]. Recognition by specialists in the field that maintaining blood sugar levels as close as possible to normal reduces the risk of long-term complications, has led to the development of several ways to administrate insulin and monitor blood sugar [15].

Thus, in recent years new technologies such as continuous subcutaneous insulin infusion pumps (CSII or insulin pumps) and devices with continuous glucose monitoring sensor (CGM) have been introduced for better management of DM [15].

Insulin pumps consist of a needle that is inserted subcutaneously and fixed with an adhesive patch, the needle being connected to a pump or a plastic cannula. They appeared in the late 1970s in order to improve the glycemic values of patients with type I diabetes [16].

Vision-threatening diabetic retinopathy is known to be rare in patients with type 1 diabetes within the first five years of diabetes onset. Instead, the occurrence of diabetic retinopathy was demonstrated in almost all patients with type I diabetes after twenty years of evolution. The growing number of patients with type 1 diabetes, which in 2020 reached about half a billion people, has led to the increase in the use of insulin pumps [17].

Although they were originally designed for patients with type I diabetes, in

recent years the use of CSII has increased among patients with type II diabetes. There are studies with positive results for this category of patients as well [10,18]. The Opt2mise study is the only randomized, large-scale study that demonstrated the superior efficacy of insulin pumps compared to MDI in people with poorly controlled type II diabetes [19].

Continuous glucose monitoring devices appeared in 1999 and in 2006 the FDA approved the first CSII integrated with a CGM sensor device. The integration of CSII with real-time CGM in a single device has led to the creation of a hybrid system with automated insulin delivery technology, known as augmented pump therapy with sensors (SAP) [10,20,21].

Although the first clinical manifestations of RD are the appearance of microaneurysms and intraretinal hemorrhages, microvascular lesions appear before clinical signs.

There are currently several technologies that can be used to detect preclinical signs of DR. Fluorescein angiography can highlight capillary leakage and areas of non-perfusion. Since it is an invasive method, it is not recommended in the screening of patients who do not show signs of DR on ophthalmoscopic examination [22]

Optical coherence tomography angiography (angio-OCT) is a modern, non-invasive method that can highlight the preclinical signs of RD [23].

Early diagnosis of RD and prompt treatment are essential measures to minimize the visual acuity loss. Hyperglycemia and long history of diabetes are the main risk factors for microvascular complications such as RD. If we cannot interfere on the duration of the disease, hyperglycemia is a modifiable factor. The Diabetes Complications Control Study (DCCT) demonstrated that the

development of microvascular complications can be prevented by intensive glycemic control [24].

In this study, it was shown that maintaining a glycosylated hemoglobin level less than 7% was associated with a reduced risk of developing RD, with this benefit being maintained up to 20 years of disease progression. The Diabetes Control and Complications Trial (DCCT) has established that proper long-term blood glucose management reduces the risk of developing RD. There are concerns about the phenomenon called "metabolic memory" which causes transient worsening of RD when it is a rapid improvement in blood sugar, which is why the guidelines recommend controlled reductions in blood sugar, with frequent monitoring of retinopathy, when treatment is changed [24]

The most common mode of administration for both type I and type II DM patients is multiple daily injections. Due to all its benefits insulin pumps are used more and more often [5].

Compared to traditional methods of treatment with insulin administered by multiple daily injections (MDI), treatment with insulin pumps or SAP allows the regulation of insulin according to the requirements and daily needs of patients (exercise, diet), thus reducing 24-hour glycemic variability and glycosylated

hemoglobin level. Thus, by improving glycemic control, episodes of severe hypoglycemia are reduced without increasing those of diabetic ketoacidosis, ultimately leading to an increase in the quality life of patients with diabetes [15, 21, 25].

Because of all these benefits, recent studies indicate the important role of insulin pumps in reducing the macro and microvascular complications of diabetes. In a longitudinal study of 989 adolescents with type I diabetes, the use of CSII for at least one year resulted in a reduction in early microvascular complications such as diabetic retinopathy and peripheral nerve damage compared to MDI [26].

Although the long-term effects of insulin pump use are not yet fully known, numerous studies have reported a lower incidence of micro- and macrovascular complications. In the case of diabetic patients treated with insulin pumps, a lower incidence of RD and a slower progression of it was found [5].

Angio-OCT is a non-invasive, fast and side-effect-free imaging method that can be used for RD screening. The clinical signs that can be detected with angio-OCT are: irregular edges of the foveal avascular zone (FAZ), the presence of microaneurysms that could not be observed by ophthalmoscopic examination and the decrease of superficial vascular density (SVD) [5, 27]. (Figure 1)

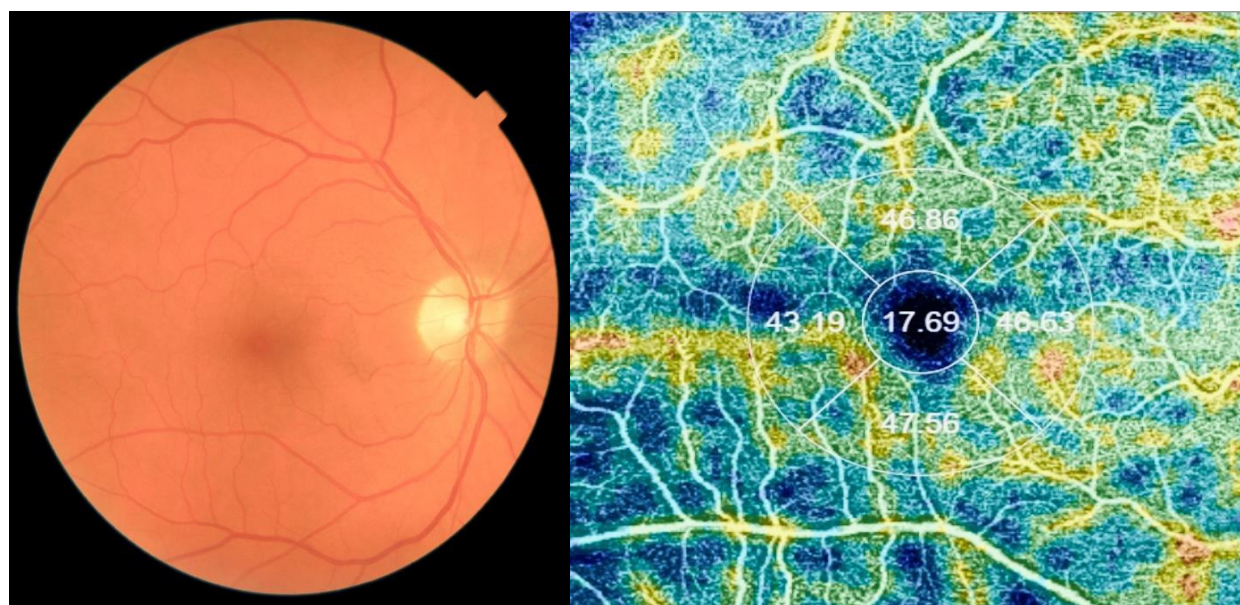


Figure 1 Patient without signs of DR on the fundus examination but who on angio-OCT shows a decrease in SVD and irregular edges of the FAZ. (personal archive)

In a study performed in 2021, patients with CSII had better glycemic control compared to the group that used MDI by maintaining lower HbA1c values and at the same time presented higher SVD values, thus suggesting the beneficial role of metabolic control at the level retinal microvasculature [5].

Decreased SVD is a preclinical parameter that has been associated with the occurrence of DR. This study concluded that the use of CSII could be associated with the reduction of retinal microvascular lesions thus leading to a decrease in the incidence of RD and a delay in its onset. The results are promising but the long-term benefits of CSII will be demonstrated by further studies [28, 29].

In a randomized controlled trial that included 211 children (106 using CSII and 105 MDI), no statistically significant difference in HbA1c values was found between the two groups, instead a statistically significant reduction in fear of hypoglycemia

was demonstrated both of the patient and his family, thus improving the quality of life [30]

Karges et al. followed over 19,000 patients with type I DM for 4 years and showed a decrease in the rate of diabetic ketoacidosis (DKA) and episodes of severe hypoglycemia in CSII patients compared with those using MDIs [31].

Linket to RD, Downie et al. in the study performed on 1604 adolescents with type I diabetes, they showed a reduction in the risk of developing RD in patients treated with CSII compared those treated with MDI, the prevalence of RD continuing to decrease as the management of glycemic values intensified [32].

Also, Charles et al. showed that improved glycemic variability through the use of insulin pumps led to a lower incidence of diabetic retinopathy, the most significant reduction being proliferative diabetic redinopathy [33].

Although sometimes following intensive insulin treatment RD can worsen,

especially in the first two years, a good control of glycemic values improves the long-term prognosis in patients with DM type I [34]

The study by Misso et al. in 2010 compared the retinal changes in type I DM patients treated with CSII and MDI. This study confirms the improvement of glycemic control by reducing HbA1c values in patients using CSII for DM management compared to those treated with MDIs. [35]

The results of the study showed, however, an increase in the central thickness of the retina in the group of patients treated with CSII, without the appearance of macular edema and without changing other retinal parameters [35].

Regarding retinal oxygenation in patients with DM, the studies performed were cross-sectional. Venous dilatation was observed to be a risk factor for the onset and progression of RD, but which did not change with the intensification of glycemic control by CSII. [36]

Diabetic retinopathy may cause changes in retinal function even before retinal microvascular lesions become visible ophthalmoscopically. The results of electroretinography and scotopic adaptometry can be considered biomarkers of subclinical diabetic retinopathy. Thus, Holfort et al. have resulted in increased ERG amplitude in scotopic conditions and increased adaptability to darkness in patients who a year ago switched to MDI with CSII [37, 38].

Meta-analyses of observational studies and randomized studies have shown that the use of CSII compared to MDI causes lower blood glucose variability, reduces glycosylated hemoglobin levels and episodes of severe hypoglycemia, thus increasing protection against complications such as RD [39, 40].

Comparative study by Laura Reid et al. evaluated the progression of RD in patients using CSII and those administering MDI. The results showed a lower progression of RD over a 3-year follow-up in adults with type I DM who use CSII, compared with those on MDI therapy (18.6% in those with CSII vs. 26.5% in those with MDI, $p = 0.0097$). Although the reduction in glycosylated hemoglobin levels was significantly higher for the CSII group (reduction of 6mmol/mol (0.5%)) compared to the MDI group (reduction of 1mmol/mol (0.1%)) there was no evidence of aggravation transitional RD [41].

The complete etiopathogenesis of diabetic retinopathy and atherosclerosis is still incompletely elucidated. Recent evidence has shown the role of inflammation and endothelial dysfunction in their pathophysiological process. Inflammatory biomarkers such as pro-inflammatory cytokines, cell adhesion molecules, C-reactive protein are the new key elements for micro- and macro-angiopathy [42]

Impairment of endothelial function in children is a sign that precedes the formation of atheromatous plaque. Ultrasound analysis of carotid artery intima-media thickness and brachial artery flow-mediated dilatation revealed less advanced early atherosclerotic changes in children using CSII compared with those treated with MDI. Research was not conducted in patients who transitioned from MDI to CSII, but only in those who resumed CSII as first therapy. And this study hypothesizes that insulin intensification by CSII is beneficial on micro- and macrovascular changes in type I DM patients [42, 43].

Sohaib A. et al. performed a review and meta-analysis that included randomized clinical trials and contemporary studies and demonstrated that CSII therapy significantly reduces the incidence and progression of DR.

Unlike the Diabetes Control and Complications Study (DCCS) conducted and completed more than 20 years ago, this study included modern generations of insulin analogues [44].

CSII consists of connecting the insulin pump through a catheter placed subcutaneously.

New models of insulin pumps calculate insulin requirements based on the patient's carbohydrate intake and blood glucose level. By accessing the information stored in the software, you can find out an accurate history of insulin use [45]

The use of insulin pumps was associated with higher initial costs due to the costs of the pump acquisition, the necessary consumables but also for educating patients. However, long-term studies have shown that these costs are offset by reducing the costs of treating complications caused by DM [41].

The use of insulin pumps has grown exponentially with the introduction of SAP hybrid systems, diabetes market in the United States being evaluated at \$ 23 billion [46, 47].

With this increase in CSII use, new medical studies will appear that will analyze the beneficial effects of insulin pumps on the progression of diabetic retinopathy and other macro and microvascular complications of diabetes.

EFFECTS OF PLASTIC MATERIALS ON DIABETES MEDICAL DEVICES

Over the past decade, new medical devices (MD) such as insulin pumps, flash

glucose monitoring (FGM) and continuous glucose monitoring have helped patients with DM to achieve good glycemic control and reduce macro and microvascular complications [11].

In addition to all these positive effects, the use of medical devices for diabetes has been associated with a number of adverse events. The most common complication is due to mechanical failure of insulin pumps. The second most common adverse effect which has a negative impact on the patient's quality of life, is allergic contact dermatitis [15, 58-63].

ACD is caused by a type IV skin hypersensitivity immune reaction, which occurs against allergens in contact with the patient's skin. The most common contact allergens are the acrylate and methacrylate of adhesives and plastics used to create medical devices, including insulin pumps [48].

Acrylates and methacrylates are synthetic thermoplastic resins, esters of acrylic and methacrylic acids that polymerize either spontaneously or when exposed to ultraviolet light forming products used in the medical field, in plastics and textiles [49, 50].

Acrylates are classified according to their chemical structure into mono (meth) acrylates, di / tri acrylates and cyano acrylates [48].

With the widespread use of MD for diabetes, the incidence of ACD among this group of patients has increased. The most common allergens involved in the occurrence of ACD were isobornyl acrylate (IBOA), ethyl cyanoacrylate (ECA) and N, N-dimethylacrylamide. (Table 1)[11].

Table 1. Allergens identified in medical devices for diabetics implicated in development of ACD reported in specialty literature

Authors	Type of medical device for diabetics	Allergens identified in the device
Busschots et al(1995)	Cliniset Disetronic	PEEA IBOA BCA Benzonylcyclohexanol
Peeters et al (2017)	Platinum G4	ECA
Aschenbeck et al(2017)	Platinum G4	Cyanoacrilate
Oppel et al (2018)	Omnipod Freestyle Libre	IBOA
Herman et al (2017)	FreeStyle Libre	IBOA
Raison-Peyron et al (2018)	Omnipod	IBOA
Passanisi et al (2018)	Enlite sensor Omnipod	Colophonium

Abbreviations: BCA – β – carboxyethyl acrylate; ECA - ethyl cyanoacrylate; IBOA - isobornyl acrylat; PEEA – phenoxy poly(ethylenoxy) ethylacrylate.

The first case of acrylate allergy was reported by Stevenson in 1941, in a patient who developed an allergy to methyl methacrylate (MMA). Since then, acrylate allergy has been well documented [51].

IBOA is a new generation acrylate, being a low molecular weight acrylic monomer that is part of the adhesives and plastics of medical devices, including those for diabetes [52].

Herman et al. in 2017, and Pyl et al. in 2020, set a frequency of contact dermatitis at IBOA of 3.8% among patients using the FreeStyle Libre glucose sensor [53, 54].

IBOA was also identified by test patch, as well as by chemical analysis as the main factor in the occurrence of ACD in 4 of 5 patients using the Enlite glucose sensor and

the Paradigm MiniMed Quick-set insulin infusion set [55, 56].

Rayson-Peyron reports the occurrence of contact dermatitis caused by IBOA at the Omnipod insulin pump [57].

Up to 81% of patients with MD who used FreeStyle Libre or Enlite systems and who developed ACD had a positive reaction to the IBOA test package [48].

Frequent reports have given the isobornyl acrylate (IBOA) the title given by the American Dermatology Association of - Contact Allergen 2020 [48, 52].

CONCLUSION

The development of high-tech medical devices has revolutionized the

methods of diagnosis and treatment of multiple diseases.

In the field of diabetes, insulin pumps, continuous glucose monitoring systems and hybrid systems (SAP) have significantly improved blood glucose control, reducing the rate of complications such as diabetic retinopathy, severe hypoglycemia and ketoacidosis.

Due to the similarity with the physiological process of insulin release, insulin pumps are increasingly used for the management of both type I and type II diabetes.

Most of the studies that analyzed retinal parameters and intensive glycemic control were generally carried out over a period of 12 months or even less, but RD specific changes generally appear after several years of evolution. That is why long-term studies are needed to demonstrate the beneficial effects of using CSII.

CSII allows a release of insulin in accordance with food intake and changes in physical activity, which leads to greater flexibility for diabetic people, thus increasing their quality of life.

Due to allergic contact dermatitis caused specifically by IBOA, some patients are forced to return to traditional methods of glucose monitoring and insulin administration by MDI, thus decreasing the patient's quality life.

All these positive and negative effects of medical devices for diabetes should

be a motivating factor for the whole medical world and especially for manufacturers to look for new solutions to improve these devices and to constantly increase the quality life of patients.

Abbreviations

DM – diabetes mellitus, CGM – continuous glucose monitoring devices, SAP – augmented sensor pump therapy, ACD – allergic contact dermatitis, IBOA – isobornyl acrylate, WHO – World Health Organization, ADA – American Diabetes Association, RD – diabetic retinopathy, ICDSS – International Clinical Disease Severity Scale, CSII – continuous subcutaneous insulin infusion pumps, angio-OCT – optical coherence tomography angiography, DCCT – Diabetes Control and Complication Trial, MDI – multiple daily injections, FAZ – foveal avascular zone, SVD – superficial vascular density, HbA1c – glicated haemoglobin, DKA – diabetic ketoacidosis, MD – medical devices, FGM – flash glucose monitoring, ECA – ethylcyanoacrylate, PEEA – phenoxypoly(ethylenoxy)ethylacrylate, MMA – methylmethacrylate.

Conflict of interest

The authors declare that they have no conflict of interest.

References

1. World Health Organization. Diabetes key facts. Available from: <https://www.who.int/news-room/fact-sheets/detail/diabetes>; 2020.
2. Saedi P, Petersohn I, Salpea P, Malanda B, Karuranga S, Unwin N, et al. Global and regional diabetes prevalence estimates for 2019 and projections for 2030 and 2045: results from the international diabetes federation diabetes atlas. In: Diabetes Research and clinical practice. ninth ed.vol. 157; 2019. p. 107843.

3. Cole JB, Florez JC. Genetics of diabetes mellitus and diabetes complications. *Nat Rev Nephrol.* 2020 Jul;16(7):377-390.
4. Popa S, Moța M, Popa A, Moța E, Serafinceanu C, Guja C, et al. Prevalence of overweight/obesity, abdominal obesity and metabolic syndrome and atypical cardiometabolic phenotypes in the adult Romanian population: PREDATORR study. *J Endocrinol Invest.* 2016;39(9):1045-53
5. de Oliveira Loureiro T, Cardoso JN, Lopes CDPL, Carreira AR, Rodrigues-Barros S, Vide-Escada A, Campos NP. The effect of insulin pump therapy in retinal vasculature in type 1 diabetic patients. *Eur J Ophthalmol.* 2021 Nov;31(6):3142-3148.
6. Wilkinson CP, Ferris FL, Klein RE, et al. Proposed inter-national clinical diabetic retinopathy and diabetic macular edema disease severity scales. *Ophthalmology* 2003; 110(9): 1677–1682.
7. Cheloni, R., Gandolfi, S. A., Signorelli, C., Odone, A. (2019). Global prevalence of diabetic retinopathy: protocol for a systematic review and meta-analysis. *BMJ Open*, 9(3), e022188.
8. Ferris FL. How effective are treatments for diabetic retinopathy? *JAMA* 1993; 269: 1290–1291.
9. Wat N, Wong RL, Wong IY. Associations between diabetic retinopathy and systemic risk factors. *Hong Kong Med J.* 2016 Dec;22(6):589-99.
10. Patel B, Priefer R. Infections associated with diabetic-care devices. *Diabetes Metab Syndr.* 2021 Mar-Apr;15(2):519-524.
11. Herman A, de Montjoye L, Tromme I, Goossens A, Baeck M. Allergic contact dermatitis caused by medical devices for diabetes patients: A review. *Contact Dermatitis.* 2018 Dec;79(6):331-335.
12. Stumvoll M, Goldstein BJ, van Haeften TW. Type 2 diabetes: principles of pathogenesis and therapy. *Lancet.* 2005 Apr 9-15;365(9467):1333-46.
13. Hayes T, Soto I, Holtz-Eakin D, Bosch D. In: Research: understanding the insulin market. *American Action Forum*; 2020. Available from:<https://www.americanactionforum.org/research/understanding-the-insulin-market/>.
14. Raczyńska D, Zorena K, Urban B, Zalewski D, Skorek A, Malukiewicz G, Sikorski BL. Current trends in the monitoring and treatment of diabetic retinopathy in young adults. *Mediators Inflamm.* 2014;2014:492926.
15. Nimri R, Nir J, Phillip M. Insulin Pump Therapy. *Am J Ther.* 2020 Jan/Feb;27(1):e30-e41.
16. Steineck I, Cederholm J, Eliasson B, Rawshani A, Eeg-Olofsson K, Svensson AM, Zethelius B, Avdic T, Landin-Olsson M, Jendle J, Gudbjörnsdóttir S; Swedish National Diabetes Register. Insulin pump therapy, multiple daily injections, and cardiovascular mortality in 18,168 people with type 1 diabetes: observational study. *BMJ.* 2015 Jun 22;350:h3234.
17. G, Buck S, Waldenmaier D, Kulzer B, Schnell O, Gelchsheimer U, Ziegler R, Heinemann L. Insulin Pump Therapy for Patients With Type 2 Diabetes Mellitus: Evidence, Current Barriers, and New Technologies. *J Diabetes Sci Technol.* 2021 Jul;15(4):901-915. doi: 10.1177/1932296820928100. Epub 2020 Jun 1. Erratum in: *J Diabetes Sci Technol.* 2021 Jun 16;:19322968211027984. PMID: 32476471; PMCID: PMC8258526.
18. Fong DS, Aiello LP, Ferris FL, et al. Diabetic retinopathy. *Diabetes Care* 2004; 27: 2540–2553.
19. Reznik Y, Cohen O, Aronson R, et al. Insulin pump treatment compared with multiple daily injections for treatment of type 2 diabetes (OpT2mise): a randomised open-label controlled trial. *Lancet.* 2014;384(9950):1265-1272.
20. Apablaza P, Soto N, Codner E. De la bomba de insulina y el monitoreo continuo de glucosa al páncreas artificial [From insulin pump and continuous glucose monitoring to the artificial pancreas]. *Rev Med Chil.* 2017 May;145(5):630-640. Spanish. doi: 10.4067/S0034-98872017000500011. PMID: 28898340.
21. Fong DS, Aiello LP, Ferris FL, et al. Diabetic retinopathy. *Diabetes Care* 2004; 27: 2540–2553.
22. Mustafi D, Saraf SS, Shang Q, Olmos de Koo LC. New developments in angiography for the diagnosis and management of diabetic retinopathy. *Diabetes Res Clin Pract.* 2020 Sep;167:108361.

23. Cao D, Yang D, Huang Z, et al. Optical coherence tomography angiography discerns preclinical diabetic retinopathy in eyes of patients with type 2 diabetes without clinical diabetic retinopathy. *Acta Diabetol* 2018; 55(5): 469–477
24. Nathan DM (2014) The Diabetes Control and Complications Trial/ Epidemiology of Diabetes Interventions and Complications Study at 30 Years: Overview. *Diabetes Care* 37:9–16
25. Tumminia A, Sciacca L, Frittitta L, Squatrito S, Vigneri R, Le Moli R, Tomaselli L. Integrated insulin pump therapy with continuous glucose monitoring for improved adherence: technology update. *Patient Prefer Adherence*. 2015 Sep 7;9:1263-70.
26. Tołwińska J, Głowińska-Olszewska B, Bossowski A. Insulin therapy with personal insulin pumps and early angiopathy in children with type 1 diabetes mellitus. *Mediators Inflamm*. 2013;2013:791283
27. Pahl DA, Green NS, Bhatia M, et al. Optical coherence tomography angiography and ultra-widefield fluorescein angiography for early detection of adolescent sickle retinopathy. *Am J Ophthalmol* 2017; 183: 91–98.
28. Escobar-Villado SL, Lima-Gómez V. Regional parafoveal vessel density changes in diabetic patients without retinopathy. *Gac Med Mex*. 2021;157(4):338-342.
29. Lavia C, Couturier A, Erginay A, et al. Reduced vessel density in the superficial and deep plexuses in diabetic retinopathy is associated with structural changes in corresponding retinal layers. *PLoS One* 2019; 14(7): e0219164
30. Ross LJ, Neville KA. Continuous subcutaneous insulin infusion versus multiple daily injections for type 1 diabetes. *J Paediatr Child Health*. 2019 Jun;55(6):718-722.
31. Karges B, Schwandt A, Heidtmann B et al. Association of insulin pump therapy vs insulin injection therapy with severe hypoglycaemic, ketoacidosis, and glycaemic control among children, adolescents and young adults with type 1 diabetes. *JAMA* 2017; 318: 1358–66.
32. E. Downie, M. E. Craig, S. Hing, J. Cusumano, A. K. F. Chan, and K. C. Donaghue, “Continued reduction in the prevalence of retinopathy in adolescents with type 1 diabetes: role of insulin therapy and glycemic control,” *Diabetes Care*, vol. 34, no. 11, pp. 2368–2373, 2011.
33. M. St Charles, P. Lynch, C. Graham, and M. E. Minshall, “A cost-effectiveness analysis of continuous subcutaneous insulin injection versus multiple daily injections in type 1 diabetes patients: a third-party payer perspective,” *Value in Health*, vol. 12, no. 5, pp. 674–686, 2009.
34. Klefter ON, Hommel E, Munch IC, Nørgaard K, Madsbad S, Larsen M. Retinal characteristics during 1 year of insulin pump therapy in type 1 diabetes: a prospective, controlled, observational study. *Acta Ophthalmol*. 2016 Sep;94(6):540-7.
35. Misso ML, Egberts KJ, Page M, O'Connor D & Shaw J (2010): Continuous subcutaneous insulin infusion (CSII) versus multiple insulin injections for type 1 diabetes mellitus. *Cochrane Database Syst Rev*: CD005103.
36. Hardarson SH & Stefansson E (2012): Retinal oxygen saturation is altered in diabetic retinopathy. *Br J Ophthalmol* 96: 560–563.
37. Klefter ON, Holfort SK, Larsen M. Baseline haemoglobin A1c influences retinal function after long-term insulin pump therapy. *Graefes Arch Clin Exp Ophthalmol*. 2016 Mar;254(3):467-73.
38. Holfort SK, Norgaard K, Jackson GR, Hommel E, Madsbad S, Munch IC, Klemp K, Sander B, Larsen M (2011) Retinal function in relation to improved glycaemic control in type 1 diabetes. *Diabetologia* 54:1853–1861
39. Yeh HC, Brown TT, Maruthur N, Ranasinghe P, Berger Z, Suh YD, Wilson LM, Haberl EB, Brick J, Bass EB, Golden SH. Comparative effectiveness and safety of methods of insulin delivery and glucose monitoring for diabetes mellitus: a systematic review and meta-analysis. *Ann Intern Med*. 2012 Sep 4;157(5):336-47
40. Misso ML, Egberts KJ, Page M, O'Connor D, Shaw J. Continuous subcutaneous insulin infusion (CSII) versus multiple insulin injections for type 1 diabetes mellitus. *Cochrane Database Syst Rev*. 2010 Jan 20;(1):CD005103.

41. Reid LJ, Gibb FW, Colhoun H, Wild SH, Strachan MWJ, Madill K, Dhillon B, Forbes S. Continuous subcutaneous insulin infusion therapy is associated with reduced retinopathy progression compared with multiple daily injections of insulin. *Diabetologia*. 2021 Aug;64(8):1725-1736.
42. Tołwińska J, Głowińska-Olszewska B, Bossowski A. Insulin therapy with personal insulin pumps and early angiopathy in children with type 1 diabetes mellitus. *Mediators Inflamm*. 2013;2013:791283.
43. H. Tamura, T. Suzue, F. Jitsunari, and T. Hirao, "Evaluation of carotid arterial intima-media thickness (IMT) and its relation to clinical parameters in Japanese children," *Acta Medica Okayama*, vol. 65, no. 1, pp. 21–26, 2011.
44. Virk SA, Donaghue KC, Wong TY, Craig ME. Interventions for Diabetic Retinopathy in Type 1 Diabetes: Systematic Review and Meta-Analysis. *Am J Ophthalmol*. 2015 Nov;160(5):1055-1064.e4.
45. Martu, M.A. , Solomon, S.M. , Toma, V. , Maftai, G.A. , Iovan, A., Gamen, A., Hurjui, L , Rezus, E. , Foia, L. , Fornu, N.C. , The importance of cytokines in periodontal disease and rheumatoid arthritis. review, *Romanian Journal Of Oral Rehabilitation*, Volume 11, Issue 1 , 2019, Page 230-240
46. Steineck I, Cederholm J, Eliasson B, Rawshani A, Eeg-Olofsson K, Svensson AM, Zethelius B, Avdic T, Landin-Olsson M, Jendle J, Gudbjörnsdóttir S; Swedish National Diabetes Register. Insulin pump therapy, multiple daily injections, and cardiovascular mortality in 18,168 people with type 1 diabetes: observational study. *BMJ*. 2015 Jun 22;350:h3234.
47. Digital diabetes management market size, share & trends analysis report. Grand view research. Report ID: GVR-3-68038-689-9.
48. Hirsch IB, Battelino T, Peters AL, Chamberlain JJ, Aleppo G, Bergenstal RM. Introduction: history of glucose monitoring. In: *Role of continuous glucose monitoring in diabetes treatment*. Arlington, Va: American Diabetes Association; 2018.
49. Gardeen S, Hylwa S. A review of acrylates: Super glue, nail adhesives, and diabetic pump adhesives increasing sensitization risk in women and children. *Int J Womens Dermatol*. 2020 Apr 23;6(4):263-267.
50. Ancuta, C., Pomirleanu, C., Iordache, C., Antohe, M.E. , Chirieac, R. , Ancuta, E. , Luchian, D. , Esanu, I.M. , Serum Lipid Profile in Diffuse versus Limited Systemic Sclerosis Data from the SASS cohort, *Revista de chimie*, Volume 69, Issue 2, 2018, Page 403-406
51. Muttardi K, White IR, Banerjee P. The burden of allergic contact dermatitis caused by acrylates. *Contact Dermatitis*. 2016 Sep;75(3):180-4.
52. Ramos L, Cabral R, Gonçalo M. Allergic contact dermatitis caused by acrylates and methacrylates--a 7-year study. *Contact Dermatitis*. 2014 Aug;71(2):102-7.
53. Stevenson WJ. Methyl methacrylate dermatitis. *Contact Point*. 1941;18:171
54. Voller LM, Warshaw EM. Acrylates: new sources and new allergens. *Clin Exp Dermatol*. 2020 Apr;45(3):277-283.
55. Ancuța C, Chirieac R, Ancuța E, Țănculescu O, Solomon SM, Fătu AM, Doloca A, Iordache C. Exploring the Role of Interleukin-6 Receptor Inhibitor Tocilizumab in Patients with Active Rheumatoid Arthritis and Periodontal Disease. *Journal of Clinical Medicine*. 2021;
56. Stoian, A., Earar, K., Budacu, C., Voidazan, S., Crauciuc, A, Stoian, M, Bica, C.I., Banescu, C., No Association Between Antioxidant Enzyme Gene Polymorphism and Albuminuria in Type 2 Diabetes Mellitus Cases, *Revista de chimie*, 67 (11), 2016, pp.2355-2359
57. Herman A, Aerts O, Baeck M, Bruze M, De Block C, Goossens A, et al. Allergic contact dermatitis caused by isobornyl acrylate in Freestyle_Libre, a newly introduced glucose sensor. *Contact Dermatitis* 2017;77:367–73.
58. Pyl J, Dendooven E, Van Eekelen I, den Brinker M, Dotremont H, France A, et al. Prevalence and prevention of contact dermatitis caused by FreeStyle Libre: a monocentric experience. *Diabetes Care* 2020;43(4):918–20.

59. Solomon, S.M.; Stafie, C.S.; Sufaru, I.-G.; Teslaru, S.; Ghiciuc, C.M.; Petrariu, F.D.; Tanculescu, O. Curcumin as a Natural Approach of Periodontal Adjunctive Treatment and Its Immunological Implications: A Narrative Review. *Pharmaceutics* 2022, 14, 982.
60. Kamann S, Aerts O, Heinemann L. Further evidence of severe allergic contact dermatitis from isobornyl acrylate while using a continuous glucose monitoring system. *J Diabetes Sci Technol.* 2018;12:630-633.
61. Ancuta, C ., Pomirleanu, C., Iordache, C ., Antohe, M.E., Chirieac, R. , Ancuta, E., Luchian, D., Esanu, I.M., Serum Lipid Profile in Diffuse versus Limited Systemic Sclerosis Data from the SASS cohort, *Revista de chimie*, Volume 69, Issue 2, 2018, Page 403-406
62. Herman A, Baeck M, de Montjoye L, Bruze M, Giertz E, Goossens A, Mowitz M. Allergic contact dermatitis caused by isobornyl acrylate in the Enlite glucose sensor and the Paradigm MiniMed Quick-set insulin infusion set. *Contact Dermatitis.* 2019 Dec;81(6):432-437.
63. Raison-Peyron N, Mowitz M, Bonardel N, et al. Allergic contact dermatitis caused by isobornyl acrylate in OmniPod, an innovative tubeless insulin pump. *Contact Dermatitis* 2018;79: 76–80.