

THE SINUS LIFT PROCEDURE APPLIED IN CASES WHERE THE THICKNESS OF THE ALVEOLAR BONE IS INSUFFICIENT USING DOUBLE PRF AS WELL AS IN THE CASE OF AN INTRASINUS MUCOCELE

Mihaela Mitrea^{1*}, Laura Iulia Bozomitu^{2*}, Razvan Tudor Tepordei^{1*}, Irina Luciana Gurzu^{4*}, Edlibi Al Hage Walid^{5*}, Ovidiu Mihail Stefanescu^{6*}, Simona Alice Partene Vicoleanu^{1*}, Simona Niculescu^{7*}, Irina Jemnoschi Hreniuc^{1*}, Angela Tecuceanu^{1*}, Allia Dmour^{1*}, Razvan Radu Maxim^{1*}, Oana Elena Ciurcanu^{6*}, Vlad Danila^{6*}

¹“Grigore T.Popa” University of Medicine and Pharmacy of Iasi, Romania, Faculty of Medicine, Department of Morphological Science I

²“Grigore T.Popa” University of Medicine and Pharmacy of Iasi, Romania, Faculty of Medicine, Department of Gastroenterology, Hospital „Sf, Maria,, Iasi

⁴“Grigore T.Popa” University of Medicine and Pharmacy of Iasi, Romania, Faculty of Medicine, Department of Preventive Medicine and Interdisciplinarity

⁵“Grigore T.Popa” University of Medicine and Pharmacy of Iasi, Romania, Faculty of Dental Medicine, Department of Protheses Technology

⁶“Grigore T.Popa” University of Medicine and Pharmacy of Iasi, Romania, Faculty of Dental Medicine, Surgical Department

⁷“Grigore T.Popa” University of Medicine and Pharmacy of Iasi, Romania, Faculty of Medicine, Department of Mother and Child

*Corresponding authors: Oana Elena Ciurcanu: oana.ciurcanu@umfiasi.ro,
Irina Luciana Gurzu: ilgurzu@gmail.com

***All authors have the same contribution**

Abstract: Missing teeth may result in a functional and cosmetic deficit and have traditionally been replaced with dentures or bridges. Dental implants rely on the maintenance of a direct structural and functional connection between living bone and the implant surface, this is termed osseointegration. Osseointegration has undoubtedly been one of the most significant scientific breakthroughs in dentistry over the past 40 years. Insufficient bone volume is a common problem encountered in the rehabilitation of the edentulous posterior maxilla with implant-supported prostheses. The bone available for implant placement may be limited by the presence of the maxillary sinus together with loss of alveolar bone height. Bone volume may be increased by augmentation, commonly the sinus cavity is augmented with autogenous bone or biomaterials or both. Procedures are variously described in the literature as sinus lift, sinus augmentation, sinus floor elevation or augmentation of atrophic maxillary sinus. Implant placement may be combined with sinus augmentation as one-stage technique. Alternatively sinus augmentation may be carried out as some time prior to implant placement as a two-stage technique.

Key words: sinus lift, sinus floor augmentation, dental implants, sinus grafts, platelet rich fibrin (PRF), intrasinus mucocele, sinus complications.

INTRODUCTION

Loss of teeth in the posterior maxillary area can lead to adverse consequences concerning masticatory functions and occlusal equilibrium, resulting in a negative

psychophysical condition associated with muscular and temporomandibular joint diseases. A negative influence on the mental state and a reduction in the quality of life of the patient has also been reported [1,2]. In

addition, in long-standing edentulous jaws, the regional anatomy is also unfluenced. It is not uncommon, to observe a severe pneumatization of the maxillary sinus that could be influenced by intrasinus positive pressure [1,3]. Furthermore, the resorption of the sinus floor may be aggravated by increased osteoclastic activity originating from the periosteum of the Schneiderian membrane after tooth loss, due to the absence of osteogenesis normally stimulated by the functional load upon the bone, hypothetically reducing implant prosthetic alternatives for the replacement of missing teeth [1,4]. Implant treatment can be an alternative to traditional restorations such as dentures or bridges, an adequate bone volume is clinically needed in the case of a fixed implant-supported prosthesis, due to the osteointegration process firstly described by Branemark [1,5].

The maxillary sinus lift elevation procedure with bone graft augmentation is the most frequently performed surgical procedure to increase the vertical bone height of the posterior maxilla in preparation for dental implant placement. The procedure was first described by Tatum in 1976 at the Alabama Implant Study Group and later published by Boyne and James in 1980 [6,7,8,9].

Maxillary sinus grafting combined with the elevation of the Schneiderian membrane was proposed to reestablish an ideal quantity and quality of bone prior to implant placement, in clinical situation where interocclusal distance is not altered. Onlay bone grafts and guided bone regeneration procedures are indicated in the case of increased interocclusal distance, caused by vertical bone loss in the alveolar ridge below the sinus. More frequently,

apicoronal resorption is combined with a centripetal horizontal bone loss, requiring appositional saddle-shaped bone grafts or guided bone regeneration. If the horizontal and or vertical subsinus bone loss is coupled with an intrasinus vertical resorption, sinus grafting is recommended [1,10].

Davanpanah and colleagues classified posterior maxillary bone loss into several categories: vertical bone loss from within the sinus reduced distance from the floor of the sinus to the alveolar ridge crest, no loss of interocclusal distance; vertical bone loss of the alveolar ridge: loss of alveolar ridge below the sinus, there is an increase in interocclusal distance; horizontal bone loss of alveolar ridge: a loss in buccopalatal width of alveolar bone; combination subsinus loss: both vertical and horizontal bone loss [11,12]. Other grafting techniques suggest bone grafting or guided bone regeneration are required to treat the different atrophy patterns [11,12].

Based on approach to the maxillary sinus or technique involved, classification of the available sinus lifting procedures are: buccal approach/lateral window technique; trans crestal approach [11,12].

Based on surgical technique: subantral option one (SA-1): conventional implant placement; subantral option two (SA-2): sinus lift and simultaneous implant placement; subantral option three (SA-3): sinus graft with immediate or delayed endosteal implant placement; subantral option four (SA-4): sinus graft healing and extended delay of implant insertion [11,13].

Based on the use of bone graft: graft technique, non graft technique.

Based on the operating method for sinus lift: with use of osteotome, modified Summers's technique; Fugazzotto's

technique. Without the use of osteotome: hydraulic sinus condensation, antral membrane balloon, piezoelectric bony window osteotomy [11,13].

Transalveolar technique is more conservative technique than lateral antrostomy technique. The sinus membrane is not directly instrumented. Also, the sinus cavity is not directly visualized and membrane perforation are more difficult to determine. Mid crestal incision along with vertical release incisions made along the lateral aspect of the maxillary alveolar ridge can be used to gain more access. A round bur is used to mark the surgical site along the alveolar ridge. A pilot drill with a diameter of 1 to 1.5 mm less than the final implant diameter is then used. The pilot hole is made to a depth approximately 2 mm from the sinus floor. Creation of pilot hole is not necessary if 5 mm or less of vertical bone height is remaining. Next a mallet is used to drive successively larger osteotomes gradually to the final implant depth. Gradually increasing the depth decreases the potential for membrane tears. There are of fracture increases as larger osteotomes are used. The final osteotome should have a diameter approximately 0.5 mm less than the planned implant diameter. Before implant placement, some investigators have proposed the introduction of bone graft into the osteotomy site. The rationale is to increase the amount of bone between the apex of the implant and sinus floor. Si and colleagues found similar implant survival rates and no advantage is grafted sites versus nongrafted sites. The advantages of this technique are: minimally invasive, less surgical time. The disadvantages are: a minimum thickness of alveolar bone is must to attain primary stability, benign paroxysmal positional

vertigo due to tapping by the osteotome is reported in many, no control over the force generated by mallet [11,14].

Lateral antrostomy technique, a midcrestal palatally positioned incision is made in a mesiodistal direction and vertically releasing incisions are made. A full-thickness mucoperiosteal flap is elevated exposing the lateral wall of the maxillary sinus. The superoinferior and anteroposterior borders of the lateral window are determined by evaluating the CT radiograph. The inferior border of the window should be 2 to 5 mm superior to the sinus floor to prevent difficulty during infracturing. The anterior border is determined by the mesial extent of the sinus, whereas the distal border is the area of the first molar. The window is created with a low-speed drill with a diamond bur or a piezoelectric instrument. The window is prepared until a bluish or reddish hue is visible along the outline of the preparation. This indicates proximity to the schneiderian membrane. The corners should be rounded to prevent sharp edges which can potentially perforate the membrane. The bone window is then infractured into the sinus cavity and elevated in a superior direction along with the sinus membrane which creates space inferior to the bone window for graft material. An alternative is to detach the bone window from the sinus membrane for use as an autologous graft. With either technique, the sinus membrane is gently elevated superiorly with blunt dissection. Graft material is introduced into the space created inferior to the sinus membrane. Graft should fill the cavity loosely. The decision to place a membrane over the antrostomy site is based on provider preference. If a larger window is created it is recommended that a barrier

membrane be placed before closure [11,15]. However, Torres Garcia a-Denclie and colleagues found no significant difference if a membrane was used versus not used. The mucoperiosteal flap is then tension free.

Disadvantages of this technique: perforation of sinus membrane (chance of 35%), long surgical time, severe post operation complication, sloping sinus complicates the buccal window approach especially when sinus access window must be decorticated further superior and posterior to reach the cavity and the membrane [11,15].

Traditionally, the success of the maxillary sinus lift procedure is determined by the amount of vital bone formation after maturation of the graft and the long-term survival rate of the implants placed in that region. Various grafting materials have been used in maxillary sinus lift surgery, including autologous bone, xenogeneic bone, demineralized or mineralized allogeneic bone and alloplasts. These grafts may have potential for osteogenesis, osteoconduction or osteoinduction [12,16].

It would be beneficial for the patient to reduce time interval by accelerating the process of transplanted bone or the bone substitute. Use of platelet-rich plasma was a promising option that remains controversial [17,18]. Platelet-rich fibrin (PRF) is an autologous fibrin matrix used to enhance bone generation [19,20].

MATERIAL AND METHODS

Originally 9 patients (6 women and 3 men) in good general health were recruited from January 2022 to January 2023 in a private

dental clinic. After briefing all the included patients about the study, a written informed consent and a detailed case history of all the enlisted participants was obtained.

Inclusion criteria were both mono- and bilateral partial edentulisms associated with different degrees of vertical and horizontal bone loss in the lateral-posterior maxilla (according to classes II-VI Cawood@Howell atrophy classification) with pneumatization of the maxillary sinus requiring sinus floor elevation procedures for implant placement purpose. Of these 9 patients, 4 required bilateral sinus lift and 5 only right or left sinus lift. All 9 patients presented the native apical-coronary dimension of 8 mm. Exclusion criteria were: signs and symptoms of maxillary sinus disease, poor oral hygiene, active periodontal infections, uncontrolled systemic pathologies and presence of smoking habit more than 10 cigarettes/day. The necessary preoperative radiographs (i.e. OPG and CBCT scans) and other inquiries such as complete blood profile were taken.

Before surgery, patients received proper oral hygiene instructions and professional oral hygiene. At the end of the initial therapy, before starting the surgical procedures, the patients demonstrated proper plaque control. The same pre-surgical protocol was adopted in all cases: prophylactic antibiotics consisted of a preoperative oral amoxicillin-clavulanate (Augmentin 2g given 1h before the procedure) and continued for 7 days (1g twice daily). Patients were also asked to rinse with chlorhexidine 0,2% three times a day starting from one week before surgery and up to suture removal.

The surgical procedures were performed under local anaesthesia, including a pre-

operative rinsing of the oral cavity with a 0,2% chlorhexidine antiseptic solution and perioral skin disinfection with benzalkonium chloride. Local infiltration anaesthesia was used with mepivacaine chlorhydrate, subsequently, 4 mg dexamethasone was injected into the submucosa around the surgical site to reduce post-operative swelling.

Basically, all surgical procedures in case of 8 patients consisted of a sinus floor elevation approached through a lateral-window antrostomy following the Boyne and James procedure protocol. A midcrestal horizontal incision was made with mesial and distal vertical releasing incisions, in order to mobilize a trapezoidal full-thickness flap. The flap was carefully elevated from the buccal and palatal aspect to expose the residual alveolar ridge and lateral-posterior upper maxilla. The lateral wall of the maxillary sinus was approached with a small round diamond bur on a low-speed straight handpiece under sterile saline solution irrigation to create a bony window. The antral mucosa was then carefully elevated and the prepared antrostomy was subsequently in-fractured, like a trap-door and used as the superior border of the sinus compartment leaving it attached to the underlying Schneiderian membrane and being careful not to create perforation. The Schneiderian membrane was visualized and carefully elevated till the medial aspect of the sinus, to ensure sufficient space for placement of graft material. Simultaneously 10 ml of blood from patient's left antecubital vein was drawn and used to process platelet-rich fibrin as per standard protocol. The sinus cavity was augmented meticulously using the respective bone graft material with PRF. A bioresorbable collagen membrane (Biogide, Geistlich,

Wolhusen, Switzerland) was used to cover the window, the flap was reapproximated and suture with 4.0 Vicryl. The same procedure was repeated on the opposite side in case of 3 patients.

The implant insertions was performed after 6 months following sinus floor augmentation.

In only case of a patient with intrasinus mucocele, the same surgical technique was applied until the moment when with a syringe, I extracted the cystic content from inside the sinus (I filled 2 wells with cystic fluid), perforating the membrane at one point, washes with physiologic serum, then Metronidazole, then they were vacuumed. The liquid extraction consented to reduce the internal pressure of the cyst, thus diminished the dimension of the lesion and the risk of laceration during sinus lifting of the Schneiderian membrane. After this stage, a clot PRF was applied over the bone mixed with PRF liquid (forming the sticky bone) having already created the cavity for inserting the implant with it inside surrounded by autologous bone Apathos (OsteoBiol) by Tecnos. The window was closed with 2 PRF membranes. Thus, two membranes were used in this surgical technique, one made of PRF that applied to the ceiling of the cavity created in the sinus and the other resorbable collagen membranane (Biogide, Geistlich, Wolhusen, Switzerland) at the level of the created flap. A double layer suture was applied with horizontal mattress and single stitches (4.0 Vicryl) to seal the overlapping flaps.

The postoperative pain relief was obtain by administration of paracetamol and codeine.

Sutures were removed after 10 days.

All patients were included in a strict hygiene recall protocol.

PRF (platelet-rich fibrin) was obtained from an autologous sample of blood which was drawn from the patient, during surgery. As per standard protocol for preparation of PRF, a 20-cc syringe was used to draw venous blood of the patient and was placed in 3 tubes, these tubes were coated with an agent (citrate dextrose A) to prevent coagulation of blood from occurring, prior to their use. These tubes were then subjected to a centrifugation process in a specially devised centrifuge machine.

An immediate post-operative RVG was obtained in the case of all patients. The removal of sutures was done on day 10 post-operatively. An RVG was obtained after 3 months of surgery, CBCT scans were taken for all the patients, after 6 months to estimate

the bone formation, after which they were planned for implant placement.

RESULTS

Of these 9 patients (6 women and 3 men) aged between 30-55 years, 4 women required a bilateral sinus lift with the insertion at 6 months of 8 Fast@Fix implants from Bredent and one woman and 4 men required sinus right or left lift with also the insertion of implants at 5 months. The latter had a number of 8 implants inserted after 6 months.

The 35-year-old patient DA came to our office complaining of pressure associated with intermittent pain at the level of the left sinus and an incomplete treatment performed at the level of 25 (fig.1).

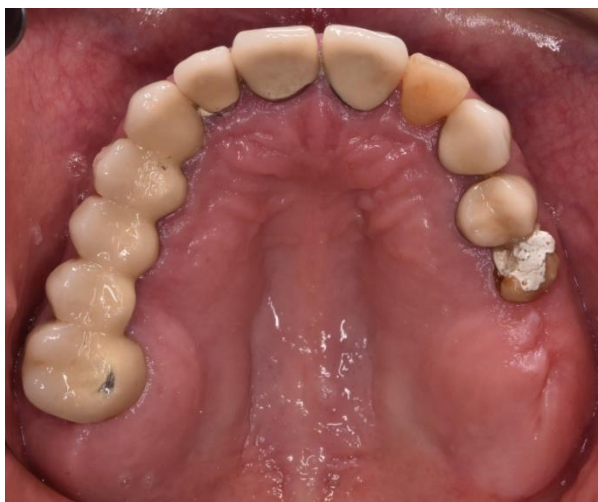

Fig.1. Initial aspect 25 intraoral

Following the CBCT examination, the intrasinusal presence of a cystic formation occupying the entire left sinus cavity was revealed (fig.2,fig.3).

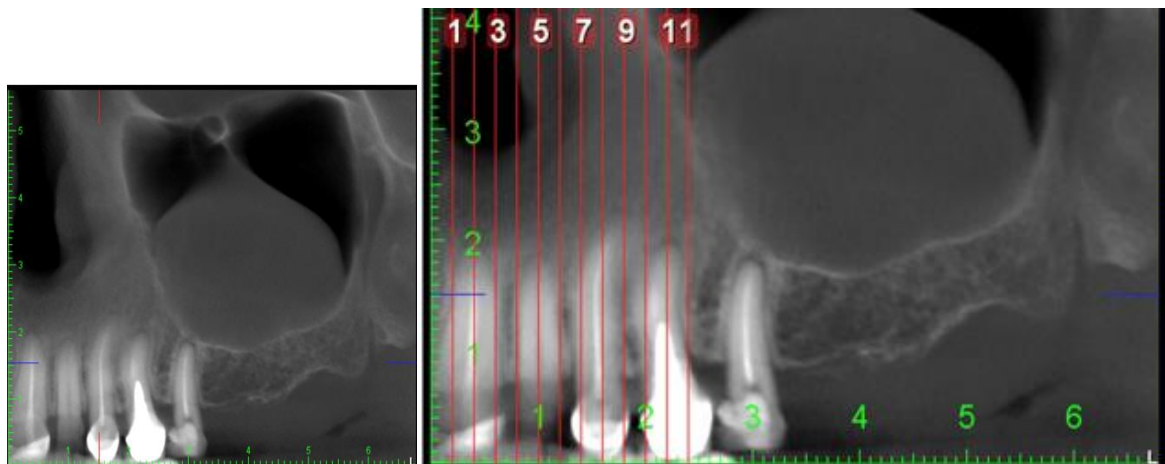


Fig.2. CBCT scan exams shows the presence of a neof ormation in the left maxillary sinus.

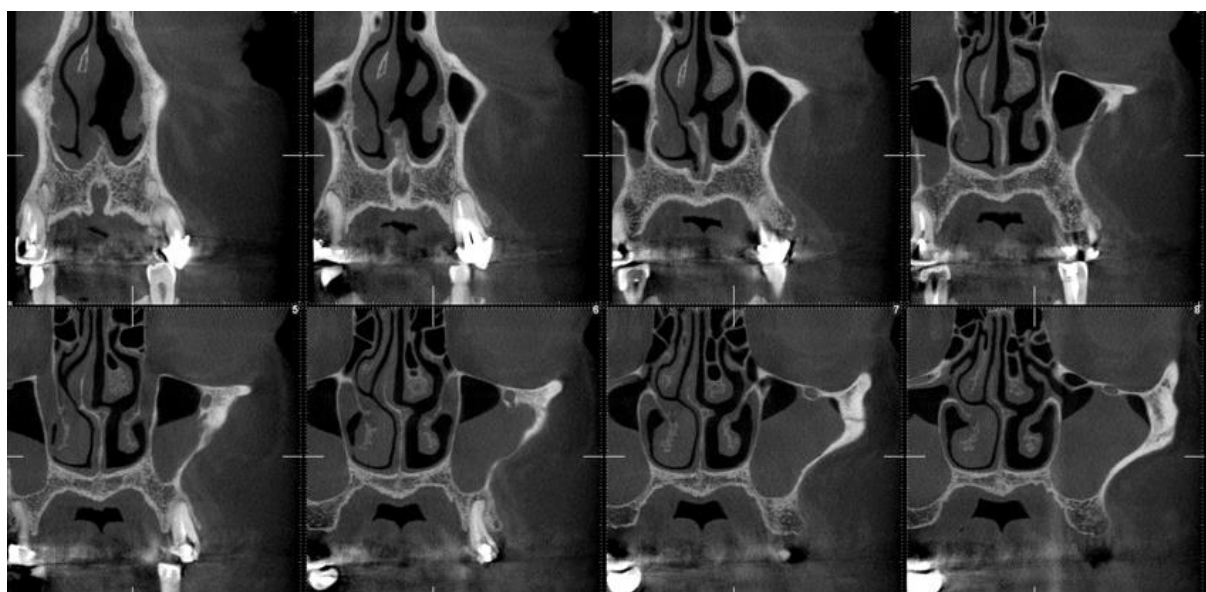


Fig.3. Transverse CBCT sections showing the large changes in the membrane and the left sinus cavity as a result of the presence of the neof ormation



A crestal incision slightly palatal to the crest in order to preserve a band of keratinized attached mucosa and two vertical release incisions were carried out to reflect a mucoperiosteal flap. The lateral wall of the maxillary sinus was exposed and an osteotomic window was performed using a round bur. A perforation through the vestibular wall of the maxillary sinus was made 5 mm over the upper side of the bony window using a 2 mm round bur (fig.4).

This procedure was performed to allow a direct access to the mucosal cyst in order to suck out the liquid contained in the neof ormation by means of a syringe inserted into this communication. The liquid extraction consented to reduce the internal pressure of the cyst, thus diminishing the dimension of the lesion and the risk of laceration during the lifting of the Scheiderian membrane. The sinus membrane was then gently lifted from the

bony floor by means of an antral curette (fig.5).

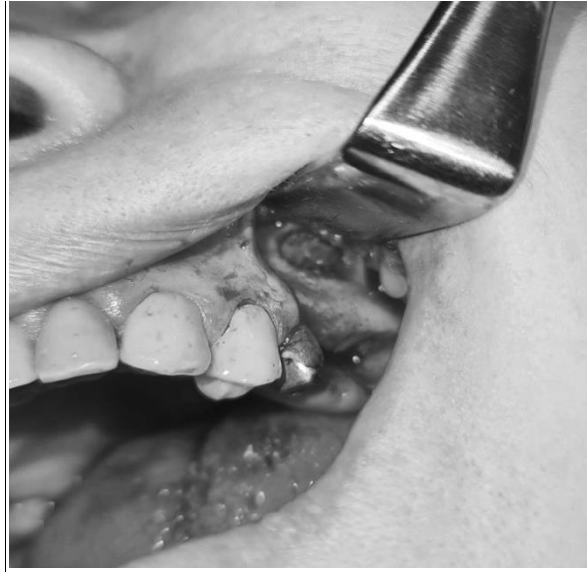

Fig. 4. A perforation was made 5 mm above the upper side of the bony window to allow the suction of the liquid inside de cyst.

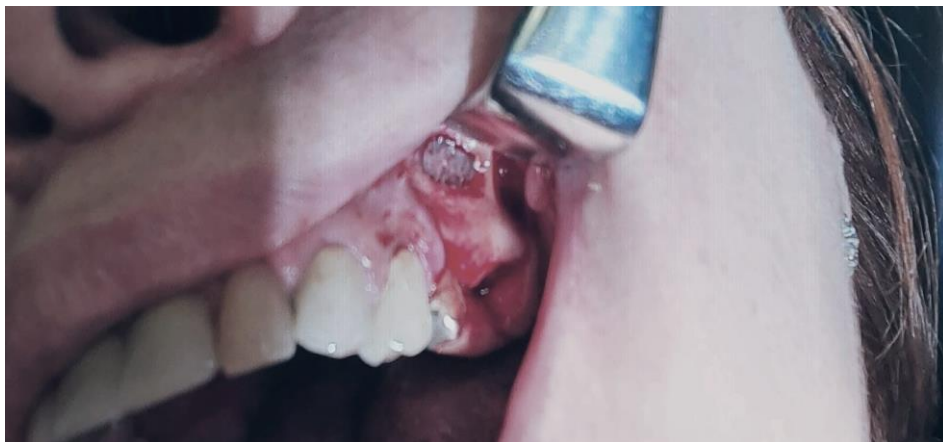

Fig.5. The sinus wall was grafted with autologous bone Apathos (OsteoBiol) by Tecnos mixed with PRF liquid (forming the sticky bone)

PRF clots were produced intra-operatively following a standard protocol: venous blood of the patients was collected in 9 mL vacutainers without clot activator or gel separator. Blood collection was performed with pre-attached, pre-fabricated sets (Vacutainer® Safety-Lok, Becton, Dickinson & C., Franklin Lakes, NJ, USA). Immediately after blood collection, the

vacutainers were centrifuged at 2700 rpm for 12 min. At the end of the centrifugation process, there were three layers in the tubes, represented by the red blood cells at the bottom, the fibrin and red clot in the middle, and serum at the top. Using an atraumatic tweezer, the fibrin matrix was extracted from the vacutainers and separated from the red clot with a scalpel or scissors (fig.6).

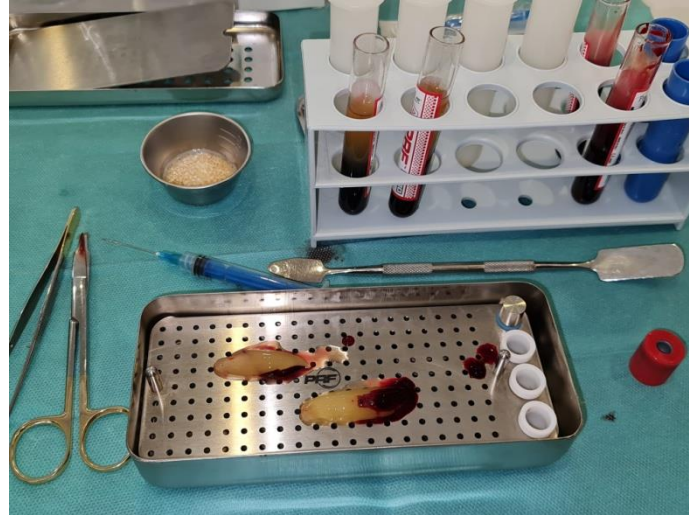

Fig. 6. Separation of the PRF fibrin product from the red blood clot

This PRF clot was applied over the bone mixed with PRF liquid (forming the sticky bone) (fig.7) having already created the cavity for inserting the implant with it inside surrounded by autologous bone Apathos (OsteoBiol) by TecnoSS. The window was closed with 2 PRF membranes. Thus, two membranes were used in this surgical technique, one made of PRF that applied to

the ceiling of the cavity created in the sinus and the other resorbable collagen membrane (Biogide, Geistlich, Wolhusen, Switzerland) at the level of the created flap. A double layer suture was applied with horizontal mattress and single stitches (4.0 Vicryl) to seal the overlapping flaps.



Fig.7. The bone mixed with PRF liquid (forming the sticky bone)

On the same day, the patient performed an OPG examination in order to check the position of the implant in relation to the effected bone addition and the inserted PRF clot (fig.8).

All patients were prescribed medications and were given written indications to follow after the surgery. One day before the surgery, and continuing for the next two days, they were all administered steroidal anti-inflammatory drugs (dexamethasone, 8 mg). For 7 days, they were prescribed

antibiotics, 1 g every 12 h of amoxicillin combined with clavulanic acid. They were instructed to avoid sneezing with the mouth closed, straw drinking and not to blow the nose. All patients were recalled for postoperative control 48 h after the surgery, and then

after 7 days for suture removal, and every 4 weeks until the new-formed bone was visible

on CBCT. Implant uncovering was performed 6 months later and their initial loading

was performed with temporary restorations.

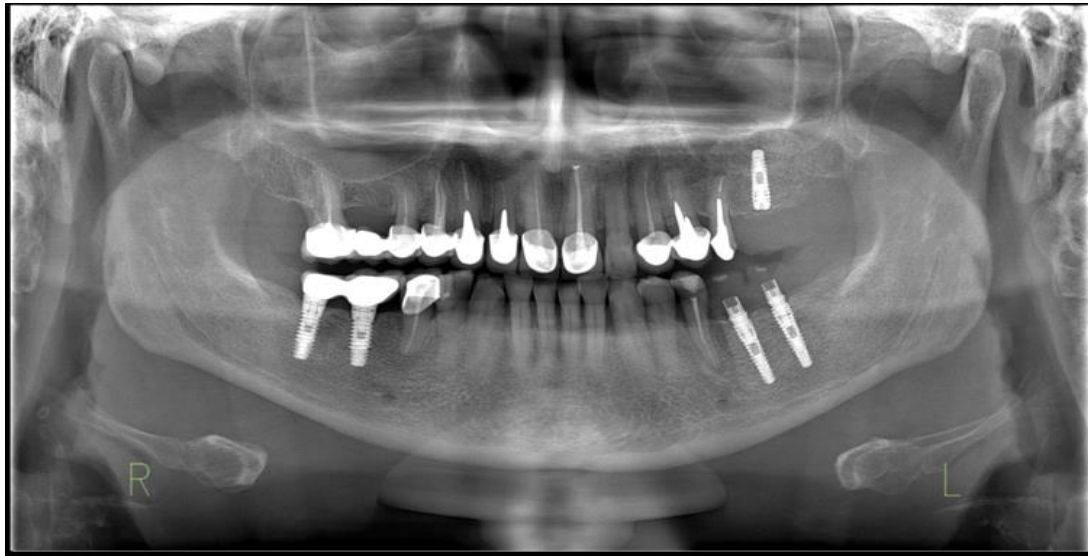

Fig.8. Radiological appearance on the same day post-implantation

DISCUSSION

Research into medical technologies and procedures has the purpose to simplifying the practitioner's work and increasing the patient's comfort and quality of life, reducing morbidity and promoting dental health. The expected results of the treatment should be directed by the surgical technique along with the necessary materials, in a single stage or if necessary, when complications occur, in separated procedures [21,22].

Bone grafting is considered to have been successful when the histological and mechanical properties resemble the native bone of the patient. The result should allow good primary stability of the implant and should be stable over time, ensuring long term survival. The variety of bone substitute materials available for sinus floor augmentation procedures should offer different possibilities for particular clinical cases. Despite the numerous studies emphasizing a specific bone grafting material, sometimes, a surgeon has the best

results with the techniques and materials that they have the greatest mastery of [21,23].

Many generation of autologous concentrates (APCs) have been developed to improve local tissue healing and regeneration under oral conditions or subsequent to surgical wounds. Examples of these preparations include autologous platelet gel (APG) known as plasma rich in growth factors (PRGF), platelet-rich plasma (PRP) and platelet-rich fibrin (PRF). In comparison to PRF, PRGF and PRP have a more complex preparation process (two stages of centrifugation and additional use of coagulation factors, CaCl₂ or bovine thrombin). Furthermore, PRP and PRGF have a limited potential for the bone regeneration process due to their short periods of growth factor release as well as their weak fibrin matrix [21,24,25].

Platelet-rich fibrin is a second-generation APC obtain from the patient's blood, that is inexpensive and easy to produce through centrifugation in collection tubes without anticoagulant or any kind of biochemical manipulation. The coagulation pathway occurs during centrifugation and separates the blood into three different layers, serum at the top, the PRF clot in the middle and the red blood cells in the lower layer. The middle PRF clot is composed of fibrin and fibrin matrix concentrated in growth factors [21,26,27].

The PRF clot is attribute two main properties of the sinus floor bone augmentation process:

A. From a mechanical point of view, the PRF provides, as a result of its volume, a relative scaffold (because it will be

resorbed after a few days) between the implants and the sinus membrane for cell migration during healing and bone formation [21,26,28]. Thus, the PRF clot, as formed in the collection tube is preferable in the sinus cavity, rather than PRF membranes. Another important principle is the elevation of the sinus membrane and its long-term maintenance in a stable position at the desired height from the sinus floor [21,29,30]. Some authors have reported the fact that sinus bone formation does not require additional biomaterials. Chen et al associated bone formation with the maintenance of the required space between the membrane and the bone cavity, followed by blood clot formation and osteoblast migration from the sinus periosteum [21,31].

Because of the rapid resorption rate of the PRF compared to the bone formation process, PRF alone are not suitable for maxillary sinus augmentation without the presence of the implants. Simultaneous implant placement should be considered in order for the implant apices to maintain an elevated Schneiderian membrane. As a result of the membrane, following PRF resorption, leaning on the tip of the implants, that are (1,5 mm) will not form bone, for example, a 13 mm implant will only form bone in the first 11,5 mm. Compared to other bone grafting materials, the volume of the future augmentation site is preserved by the particulate materials with no or minimal resorption. Thus, PRF as the sole material for sinus floor augmentation is indicated only in cases where the residual subantral bone height and density allows primary implants stability [21,29].

- B. The immunohistological benefits of the PRF consist of the abundance of leukocyte, cytokines and red blood cells, which in conjunction with the fibrin clot stimulate wound healing through the slow release of growth factors. For example, platelet-derived growth factors (PDGF) as well as transforming growth factor-B (TGF-B), vascular endothelial growth factor (VEGF), insulin-like growth factor-1 (ILGF-1) and epidermal-growth factor (EGF) released by PRF, have a therapeutic function in bone formation and remodeling. These growth factors induce chemotactic activity and promote cellular differentiation and proliferation [21,24,32].

The different regenerative capacities among different ACPs is determined by the time required for fibrin polymerization which determines the release period of the growth factors. PRF slowly release growth factors, while PRGF has a short period in which release of growth factors place [21,24].

With different centrifugation forces (RCFs), distinctive PRF products have been described in the literature. Choukroun et al produced the widely known Leukocyte-PRF (L-PRF). Lower RCFs produce an improved product with a higher concentration and better distribution of cytokines and leukocytes. Thus, reduces centrifugation forces lead to the valuable slow, constant release of growth factors [21,24]. Modification with respect to the time and speed of the centrifugation process during preparation of the PRFs is meant to increase the concentration of macrophages and leukocytes, which also have important contribution in host defence [21,32].

These biological materials have received wide application in medical procedures such as facial plastic surgery, sinus floor augmentation, treatment of exposed furcation, gingival recession and intrabony defects [21,24].

PRF is a low-cost alternative for sinus membrane sealing because of its „sticky,, consistency, being a natural fibrin scaffold which does not induce a foreign reaction as it the case with collagen membranes [21,33,34]. Some authors have recommended a double-layering of PRF to treat cases of significant Schneiderian membrane perforation [21,33].

In sinus floor augmentation, PRF can be used as a single or combined with other bone grafting substitutes [21,33,34]. The combination of PRF clot fragments with other grafting materials accelerates bone regeneration but increase the risks of infection in cases with multiple or large instance of tearing of the sinus membrane. As a general rule, delayed implantation or sinuses wider than 10 mm are not indicated for PRF as a unique grafting materials [21,33].

CONCLUSIONS

The excision of mucocele on sinus floor and simultaneous sinus augmentation obviates the need for the extended treatment period. The clinician must to be habituated with anatomy and pathology of the maxillary sinus to evade any non-essential complication following lateral sinus floor augmentation procedure. A diminutive mucocele should not be regarded as a contraindication for sinus augmentation, sometimes it manifest with bone erosion.

The prompt diagnosis and careful augmentation are needed to avoid future complication during implant therapy.

Within the limitation of this study, we can conclude that the PRF as a sole graft

material at the same time as implant placement is indicated to simplify treatment from requiring multiple stages to being a one-stage surgery for sinus augmentation, even in complicated cases with significant tearing of the sinus membrane.

REFERENCES

1. Beretta M, Poli PP, Grossi GB, Pieroni S, Maiorana C. Long-term survival rate of implants placed in conjunction with 246 sinus lift floor elevation procedures : Results of 15-year retrospective study. *Journal of Dentistry* 2015, 43:78-86.
2. Bran S, Onisor-Gligor F, Lucaciu D, Campian RS, Lucaciu OP, Ducea D. sinus lift and dental implant treatment as an option for enhancing the quality of life of our patients. *Romanian Journal of Morphology and Embriology* 2013,54:121-124.
3. Hurzeler MB, Kirsch A, Ackermann KL, Quinones CR. Reconstruction of the severely resorbed maxilla with dental implants in the augmented maxillary sinus: a 5-year clinical investigation. *Internal Journal of Oral@ Maxillofacial Implants* 1996,11:466-475.
4. Friberg B, Jemt T, Lekholm U. Early in 4,641 consecutively placed Branemark dental implants: a study from stage 1 surgery to the connection of completed prosthesis. *International Journal of Oral @ Maxillofacial Implants* 1991,6:142-146.
5. Branemark PI, Hansson BO, Adell R, Breine U, Lindstrom J, Hallen O et al. Osseointegrated implants in the treatment of the edentulous jaw. Experience from a 10-year period. *Scandinavian Journal of Plastic and Reconstructive Surgery Supplementum* 1977,16:1-132.
6. Tatum H Jr. Maxillary and sinus implant reconstructions. *Dent Clin North Am* 1986,30:207-229.
7. Tatum OH Jr, Lebipwitz MS, Tatum CA et al. Sinus augmentation. Rationale, development, long-term results. *NY State Dent J* 1993,59 :43-48.
8. Boyne PJ, James RA. Grafting of the maxillary sinus floor with autogenous marrow and bone. *J Oral Surg* 1980,38:613-616.
9. Miriam Ting, Jeremy G Rice, Stanton M Braid, Cameron YS Lee, Jon B Suzuki. Maxillary sinus augmentation for dental implant rehabilitation of the edentulous ridge: a comprehensive overview of systematic reviews. *Implant Dentistry* 2017,26 (3): 438-464.
10. Raja SV. Management of the posterior maxilla with sinus lift: review of techniques. *Journal of Oral and Maxillofacial surgery: Official Journal of the American Association of Oral and Maxillofacial Surgeons* 2009,67:1730-1734.
11. Davarpanah M, Martinez H, Kebir M, Etienne D, Tecucianu JF. Wide-diameter implants : new concepts. *International Journal of Periodontics @ Restorative Dentistry* 2001, 21(2):149-159.
12. Kumar V Sandeep, Swetha M Sai, Reddy K Sridhar. A consolidated review on sinus lift procedures. *Saudi Journal of Dental Research* 2019, 4(3):176-187.
13. Misch CE. Contemporary implant dentistry. *Implant Dentistry* 1999,8(1),90.
14. Pjetursson BE, Lang NP. Sinus floor elevation utilizing the transalveolar approach. *Periodontology* 2000, 66(1):59-71.
15. Harry D. Implant procedures for general dentist. DCNA 2015.

16. Para M, Olate S, Cantin M. Clinical and biological analysis in graftless maxillary sinus lift. *Journal of Korean Association of Oral and Maxillofacial Surgeons* 2017,43(4):214-220.
17. Choukroun J, Diss A, Simonpieri A, Girard M.O, Schoeffler C, Dohan D.M. Platelet-rich fibrin (PRF): A second-generation platelet concentrate. Part V: Histologic evaluation of PRF effects on bone allograft maturation in sinus lift. *Oral Surg Oral Med Oral Pathol Oral Radiol Endod* 2006,101:299-303.
18. Wiltfang J, Kloss FR, Kessler P, Nkenke E, Schultze-Mosgau S, Zimmermann R, Schlegel KA. Effects of platelet-rich plasma on bone healing in combination with autogenous bone and bone substitutes in critical size defects. An animal experiment. *Clin Oral Implant Res* 2004,15:187-193.
19. Gurevich O, Vexler A, Marx G, Prigozhina T, Levdansky L, Slavin S et al. Fibrin microbeads for isolating and growing bone marrow-derived progenitor cells capable of forming bone tissue. *Tissue Eng* 2002,8:661-672.
20. Mitrea M, Edlibi Al Hage Walid, Saveanu CI, Hurjui L.L, Niculescu S, Dmour A, Rusu C, Fornia N.C. Clinical implication of sinus lift procedures. *Romanian Journal of Oral Rehabilitation* 2021,13(2): 144-152.
21. Barbu H.M, Iancu S.A, Hancu V, Referendaru D, Nissan J, Naishlos S. PRF-solution in large sinus membrane perforation with simultaneous implant placement-micro CT and histological analysis. *Membranes* 2021,11,438: 1-13.
22. Gheorghievici TS, Veliceasa B, Puha B, Toader S, Alexa ID, Alexa O. Preoperative hemoglobin dynamics in patients with trochanteric fractures: a multivariate analysis. *Rev. Chim. (Bucharest)* 2018, 69(11):4220-4224.
23. Alexa O, Veliceasa B, Malancea R, Alexa ID. Postoperative cognitive disorder has to be included within informed consent of elderly patients undergoing total hip replacement. *Revista Romana de Bioetica* 2013,11(4):40-49.
24. Marchetti E, Mancini L, Bernardi S, Bianchi S, Cristiano L, Torge D, Marzo G, Macchiarelli G. Evaluation of different autologous platelet concentrate biomaterials: Morphological and Biological Comparisons and Considerations. *Materials* 2020, 13, 2282.
25. Alexa O, Perteza M, Malancea RI, Puha B, Veliceasa B. Our experience in the surgical treatment of acetabular fractures using „spring plate„ technique. *Med Surg J.-Rev. Med. Chir. Soc. Med. Nat.Iasi* 2019, 123(2):275-281.
26. Wu M, Chen G, Li Y.P. TGF- β and BMP signaling in osteoblast, skeletal development and bone formation, homeostasis and disease. *Bone Res* 2016, 4,16009.
27. Vina-Almunia J, Penarrocha-Diago M, Penarrocha-Diago M. Influence of perforation of the sinus membrane on the survival rate of implants placed after direct sinus lift. Literature update. *Med. Oral. Patol. Oral. Cir. Bucal* 2009,14,E133-E136.
28. Coroaba A, Chiriac AE, Sacarescu L, Pinteala T, Minea B, Ibanescu SA, Perteza M, Moraru A, Esanu I, Maier SS et al. New insights into human hair. SAXS, SEM, TEM and EDX for alopecia areata investigations. *Perr J.* 2020,8:e8376.
29. Tajima N, Ohba S, Sawase T, Asahina I. Evaluation of sinus floor augmentation with simultaneous implant placement using platelet-rich fibrin as sole grafting material. *Int. J.Oral Maxillofac. Implants* 2013, 28,77-83.
30. Veliceasa B, Filip A, Perteza M, Popescu D, Carp C and Alexa O. Omega plate for the treatment of acetabular fractures involving the quadrilateral plate. *Exp Ther. Med.* 2012, 22:1064.
31. Hernandez-Alfaro F, Torradeflot M.M, Marti C. Prevalence and management of Schneiderian membrane perforation during sinus-lift procedures. *Clin. Oral. Implants. Res.* 2008,19,91-98.

32. Aydinyurt HS, Sancak T, Taskin C, Basbugan Y, Akinci L. Effects of injectable platelet-rich fibrin in experimental periodontitis in rats. *Odontology* 2012, 109,422-432.
33. Chia-Lai PJ, Orłowska A, Al-Maawi S, Dias A, Zhang Y, Wang X, Zender N, Sander R, Kirkpatrick CJ, Ghanaati S. Sugar-based collagen membranes cross-linking increases barrier capacity of membranes. *Clin. Oral. Investig.* 2018, 22, 1851-1863.
34. Crisci A, Lombardi D, Serra E, Lombardi G, Cardillo F, Crisci M. Standardized protocol proposed for clinical use of L-PRF and the use of L-PRF Wound Box. *J. Unexplor. Data* 2017, 2, 77-87.