

EVALUATION OF THE RADIO-PROTECTIVE EFFECTS OF HIGH CAFFEIC ACID PHENYL ESTER CONTAINING PROPOLIS ON RADIOTHERAPY-MEDIATED BUCCAL MUCOSITIS

Mustafa Sami Demirsoy¹, Aras Erdil^{2*}, Gülhan Güler Avcı³, Fikret Gevrek⁴

¹Department of Oral and Maxillofacial Surgery, Faculty of Dentistry, Sakarya University, Sakarya, Turkey

²Department of Oral and Maxillofacial Surgery, Faculty of Dentistry, Uşak University, Uşak, Turkey

³Department of Radiation Oncology, Faculty of Medicine, Tokat Gaziosmanpaşa University, Tokat, Turkey

⁴Department of Histology and Embryology, Faculty of Medicine, Tokat Gaziosmanpaşa University, Tokat, Turkey

* Corresponding author; Aras Erdil *e-mail*: aras.erdil@usak.edu.tr

ABSTRACT

Aim of the study Lesions such as intraoral buccal mucositis encountered during radiotherapy after head and neck cancers are challenging regarding the prognosis and patient survival. For this purpose, the effectiveness of propolis containing high caffeic acid phenyl ester on buccal mucositis was investigated in a rodent model. **Material and methods** In the study groups, which comprised nine rats each, radiotherapy (15Gy) was delivered to the head and neck regions. In two of the study groups 100 and 200 mg/kg propolis were administered systemically for 14 days. In the harvested buccal mucosa samples, proinflammatory markers (interleukin-6 [IL-6], myeloperoxidase [MPO], tumor-necrosis factor- α [TNF- α]) were analyzed with Enzyme Linked-Immuno-Sorbent Assay method, and tissue samples were stained with Hematoxylin-eosin and classified regarding the inflammation scores. **Results** The tissue levels of IL-6, MPO, and TNF- α significantly decreased in a dose-dependent manner in experimental groups ($P = 0.001$, $P = 0.016$, $P = 0.001$, respectively). Also, the inflammation scores were highest in Group 2 ($P = 0.002$), whereas Groups 3 and 4 had the lowest ($P = 0.012$). **Conclusions** Aqueous propolis extract containing high caffeic acid phenyl ester can prevent lesions with its superior anti-inflammatory and free radical scavenging properties. The administration of aqueous propolis containing high caffeic acid phenyl ester decreased the inflammatory responses in a dose-dependent manner.

Key words: Apitherapy, Radiation therapy, Mucositis, Inflammation

INTRODUCTION

Radiation therapy following surgery is a standard treatment modality applied in the head and neck cancers (1). Even, at later stages of cancer, due to the inoperable conditions radiotherapy may become the only option (2). Although in conjunction with surgery radiotherapy offers high rates of cure, but may induce complications like nausea, vomiting, weight loss, myelosuppression, and mucositis (3). Oral mucositis is one of the most common complications and develops in approximately 80% of patients who receive radiation therapy for head and neck cancers (4). Oral mucositis, is a dysfunction whose

nature, duration and severity cannot be determined exactly, and it varies depending on the treatment method and the patient (5). However, hospitalization rates due to mucositis lesions were reported up to 16%. Seventy percent of patients with grade 3-4 radiation-induced mucositis (RIOM) in need of feeding tube insertion (6).

Oral mucosa constitutes of rapidly proliferating cells. Hereby, mucositis usually develops 2-3 days after initiating radiotherapy. In general, the lesions are frequently observed in the non-keratinized buccal mucosa, anterior part of the tongue and areas such as the floor of the mouth, but

can also be seen in keratinized areas like the dorsum of tongue (3). While erythema, mild pain and taste sensation alterations are observed around 20 Gy in conventional fractionated radiotherapy (in 1-2 weeks); At 30-40 Gy, patchy mucositis, pseudomembrane formation, severe pain and ulceration are observed (4). In the later stages, symptoms like deep inflamed ulcerations and hemorrhage may accompany RIOM (5). Also, the addition of concurrent chemotherapy regime, accelerated fractionation and hyperfractionation applications increase the incidence and severity of mucositis (7). Nevertheless, the long term prognosis of RIOM is considered good due to self-limiting nature. Usually, the RIOM recess within 2-4 weeks following the cessation of radiotherapy (8). However, the lesions may prevent or complicates the usual course of radiotherapy from various aspects, such as radiation dose alterations, and changes in dose fractionation. Besides, RIOM poses risks for the patient's systemic health, such as malnutrition, dehydration, and prolonged hospitalization for total parenteral nutrition (9).

The pathophysiology of RIOM remains unclear. Recently, some studies proposed a pathogenesis constitute of four phases. Due to the hypothesis, initially an inflammatory phase initiates by radiotherapy induced tissue damage, and damage causes the release of inflammatory cytokines such as interleukin (IL)-1, prostaglandins, and tumour necrosis factor- α (TNF- α) (10). Although RIOM is a self-limiting disorder, it could be a fatal damage in moderately to severely ill patients in which RIOM mandates cessation of radiotherapy and even intensive care admission. Also, patient losses may become inevitable in such cases (8).

In 2020, MASC/ISOO systematically reviewed the treatment modalities for RIOM

and grouped under 8 headings in the clinical practice guideline (11). One of these headings is natural and miscellaneous agents. Propolis, one of the products evaluated under the title, and it was stated that new evidence was identified but more data is needed for recommendation (11). Propolis is an adhesive, dark-coloured resin formed by honey bees use in the hive for various purposes, composed by the mixture of the products they collect from plants and their saliva. Anti-inflammatory, antioxidant, antibacterial, antiviral, antifungal, immunomodulatory, and antimutagenic effects of propolis have been demonstrated (12). Propolis reveals its anti-inflammatory effects by restraining prostoglandin synthesis, promoting the phagocytic capacity of immune cells, inducing cellular immunity, and improving the healing capacity of epithelial tissues (12).

Considering the pathobiology of RIOM, the current experimental animal study was designed to investigate the suppressive effects of propolis on pro-inflammatory cytokines and apoptosis that occur in primary damage and ulcerative phases, and possible positive effects on healing of lesions. The primary aim of the study is to examine the effects of propolis on inflammation in the buccal mucosa, which is one of the areas with the most RIOM observed, and the secondary aim is to examine its effects on biochemical changes in the affected tissue.

MATERIAL AND METHODS

The current study was an in vitro study which was conducted between February - May 2021 in the Tokat Gaziosmanpasa University Experimental Medicine Research and Application Center. The study design was approved by Tokat Gaziosmanpasa University Animal Experiments Local Ethics Committee with decision number: 51879863-

221. All experimental applications were conducted in accordance with Tokat Gaziosmanpasa University Faculty of Medicine, Experimental Medicine Research Unit Directives, Tokat Gaziosmanpasa University Animal Experiments Local Ethical Committee Establishment and Operation Directive, and European Commission Directive 86/609/EEC for animal experiments.

Animals

The study was performed with aged 7-12 weeks and weighing 230-300 g 34 male Wistar-Albino rats. After two weeks of acclimatization housed in metal laboratory cages under standard conditions (temperature: $22\pm 2^{\circ}\text{C}$, dark/light cycles: 12/12 hours) with access to food and water ad libitum. The rats were randomly assigned to the four experimental groups. Seven rats were in the control group (Group 1) and 9 rats were in each experimental groups. In Group 2 (n=9) radiotherapy was delivered solely to the head and neck region, in Group 3 (n=9) radiotherapy was applied in the same manner and 100 mg/kg/ml propolis was systematically administered for 2 weeks, in Group 4 (n=9) radiotherapy was applied in the same manner and 200mg/kg/ml propolis was systematically administered for 2 weeks. The water-soluble propolis extracts were acquired in form of Bee'O water-soluble droplets 10%, 20 ml (SBS Scientific Bio Solutions Industry and Trade Inc., İstanbul, Turkey). The rats were administered with propolis due to determined doses by oral gavage once in every day. The rats in control group were administered with 40 mg/kg saline solution by oral gavage. At the end of study protocol on 14th day the rats were sacrificed following injections of high-dose anaesthetics and buccal tissue samples were harvested (Fig. 1).

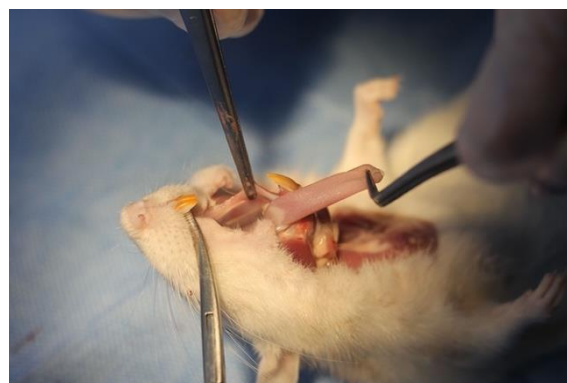

Figure 1. Harvesting a tissue sample from a sacrificed rat.

Irradiation model

The experimental radiotherapies were conducted in Tokat Gaziosmanpasa University, Faculty of Medicine, Department of Radiation Oncology under the supervision of a radiation oncologist (G.G.A). The rats were anesthetized and stabilized in prone position for proper irradiation of the head and neck regions. The target volume was drafted with the 3D conformal radiotherapy technique from two areas using 6 MV photon energy to avoid irradiation the brain and eyes. Twenty seven rats in experimental groups were irradiated on a single plan and same position in the Varian Clinac DHX 5776 LINAC device (Varian Medical Systems Inc., Palo Alto, CA, USA) with 15 Gy in a single fraction. The radiation dose and application method were obtained from previous studies (13).

Experimental Design

The study was conducted in two stages; First stage – proinflammatory markers (IL-6, myeloperoxidase [MPO], and TNF- α) were biochemically analyzed in the harvested tissue samples. Second stage –tissue sample inflammation scores were analyzed regarding intra- and intergroup differences.

Biochemical Analysis

The tissue samples obtained from buccal mucosae were stored at -80°C until needed for analysis. Buccal mucosa samples were homogenized with 50 mM Tris-HCl (pH=7.4)

buffer at 1/10 ratio, while preventing temperature rise using ice slush. In order to obtain supernatants, the homogenates were centrifuged at 3208g + 4 °C for 15 minutes. In buccal mucosa supernatants IL-6, MPO, and TNF- α (BT Lab Immunoassay, Shanghai, China) levels were investigated by Enzyme Linked-Immuno-Sorbent Essay (ELISA) method at 450 nm. Sample concentrations were reckoned utilizing the standard curve formula from the sample absorbances. The results were indicated as the ratio of buccal mucosa sample results to the total protein.

Histomorphological Analysis

The samples from buccal mucosae of the anesthetized rats were harvested prior to the scarification. The samples were immediately transferred in to the 4% buffered neutral formalin solution and fixed for 72 hours.

After completion of the fixation the samples were washed with running tap water, kept in increasing alcohol series (70%, 80%, 90%, 100%) respectively, transparentized in three separate xylene series, and clean paraffin blocking processes were performed after paraffin impregnation in three molten separate paraffin series. Consecutive thin serial sections of 5 μ m thickness were obtained from the paraffin-blocked buccal mucosa tissue samples with a rotary microtome (Leica RM2125 RTS, Leica Biosystems, Deer Park, IL, USA). Finally the sections were placed on grinded frozen slides and turned into preparations that could be stained histologically and microscopically analyzed.

Haematoxylin-eosin Staining

The sample mounted slides were heated at 60 °C and passed through xylene solution (3x5 min) for deparaffinization. The deparaffinized samples were rehydrated by passing decreasing alcohol series (100%, 90%, 80%, and 70% respectively) for 5 min, and immersing in distilled water.

The rehydrated samples were kept in haematoxylin solution for 10-15 min., washed under running tap water for 5 min., immersed in distilled water, kept in eosin solution for 3 minutes. To detract excess dye, the samples were washed with distilled water for several times. The samples were respectively immersed in 70%, 80% and 90% for 1 min., 95% alcohol for 3 min., and in absolute alcohol solution for 5 min. The samples were kept in xylene solutions thrice for 5 min., the mounting medium EntellanTM (Merck KGaA, Darmstadt, Germany) was dropped on, and covered with a cover glass.

Histopathological Analysis

The stained samples were histologically analyzed by a research light microscope (Nikon Eclipse E200, Nikon Instruments Inc., Melville, NY, USA) mounted 40X and 100X lenses, and screenshots of the samples were obtained with a software (NIS-Elements, Nikon Corporation, Tokyo, Japan) integrated into the microscope. The sample analyses were blindly performed by a histologist (F.G) on an average of 6-7 consecutive sections for each rat and in randomly determined five different areas in each section. The samples were scored according to the criteria adopted from Cetinkaya et al. (14) (Table 1).

Table 1. Inflammation Scoring System.

Score	Inflammation grade
0	None
1	Giant cells, Lymphocytes, Plasma cells
2	Giant cells, Plasma cells, Eosinophils, Neutrophils
3	Many inflammatory cells, Microabcess

Statistical Analysis

The required sample size was calculated based on a previous study (15) using G*Power 3.1 (16) with an alpha value of 0.05, and statistical power of 90%; a minimum of 32 animals was determined. The sample size was increased with two animals, taking into account possible losses during the trial period, resulting in 34 animals. The obtained results were analyzed regarding normality distribution by Shapiro-Wilk test and validated by Skewness-Kurtosis values (considered normal with values between -1.5 and +1.5). The homogeneity of variances (for IL-6, MPO, and TNF- α values) were also verified. The ANOVA test was utilized and followed by post-hoc Tukey HSD and Dunnett T3 tests to determine the differences

between the study groups. Also, non-quantitative data (tissue inflammation scores) were analyzed with chi-square (χ^2) test. IBM SPSS version 22 (IBM SPSS Inc., Chicago, IL, USA) software was used for statistical analyzes. *P* values obtained below .05 were considered significant.

RESULTS

Tissue Inflammatory Biomarkers

Significant differences were observed in systemically propolis administered rats' tissue IL-6, MPO, and TNF- α values ($p=0.001$, $p=0.016$, $p=0.001$ respectively). Also, inter-group comparisons revealed significant differences. The group 4 in which 200 mg/kg/ml propolis was administered, differed significantly in comparison with the other study groups (Table 2).

Table 2 The correlations between study groups, and tissue pro-inflammatory cytokines. (SD: standart deviation, IL-6: Interleukin 6, MPO: Myeloperoxidase, TNF- α : Tumour necrosis factor-alpha).

	Variables	N	Mean	SD	<i>P</i> -value	Post hoc (Dunnett T3)
IL-6	Group 1	7	59.03	28.81	0.001 ⁺	Group 2/Group 4 Group 3/Group 4
	Group 2	9	93.41	3.49		
	Group 3	9	92.7	12.38		
	Group 4	9	66.93	21.21		
MPO	Group 1	7	205.37	86.08	0.016 ⁺	Group 2/Group 4
	Group 2	9	313.61	16.4		
	Group 3	9	256.27	75.79		
	Group 4	9	227.61	74.51		
TNF- α	Group 1	7	2079.85	896.55	0.001 ⁺	Group 2/Group 4
	Group 2	9	3197.83	209.73		
	Group 3	9	2917.94	378.05		

Group 4	9	2235.59	663.26
---------	---	---------	--------

+ indicates P values below 0.05 obtained by ANOVA tests, as means that there are statistically significant differences between the groups mentioned on the right. Group 2=15 Gy Radiotherapy group; Group 3=15 Gy Radiotherapy+systemic application of propolis extract at a dose of 100 mg/kg/ml for 2 weeks; Group 4=15 Gy Radiotherapy+systemic application of propolis extract at a dose of 200 mg/kg/ml for 2 weeks.

Tissue Inflammation Scores

In the Group 1, a normal histological structure of the oral mucosa epithelium and lamina propria with a regular appearance in all directions and a histologically normal buccal mucosa were observed. (Fig. 2 G1) Regarding the tissue inflammation, no signs were observed throughout the tissue, which is compatible with general tissue integrity.

In the irradiated Group 2, general tissue disorders were observed in the form of diffuse and local intense inflammatory cell infiltrations in some areas, micro-abscesses, numerous macrophage cells, necrotic areas, congestion and oedema. In the buccal mucosa epithelial tissue, especially in epithelial cells, deformation, ulceration, albeit rare, decrease

in epithelial layer and thickness, and tissue damage such as deep and long papillary recesses in some places were observed (Fig. 2 G2). The tissue inflammation scores of the Group 2 were statistically significantly higher than the other study groups (Table 3, $p=0.002$).

The tissue damages, inflammation, and histological deteriorations were observed significantly decreased in the propolis administered groups (Group 3 and 4) regarding Group 2 ($p=0.012$). The enhancement in the Group 3 and 4 was very similar to each other, and the difference was not statistically significant ($p > 0.05$).

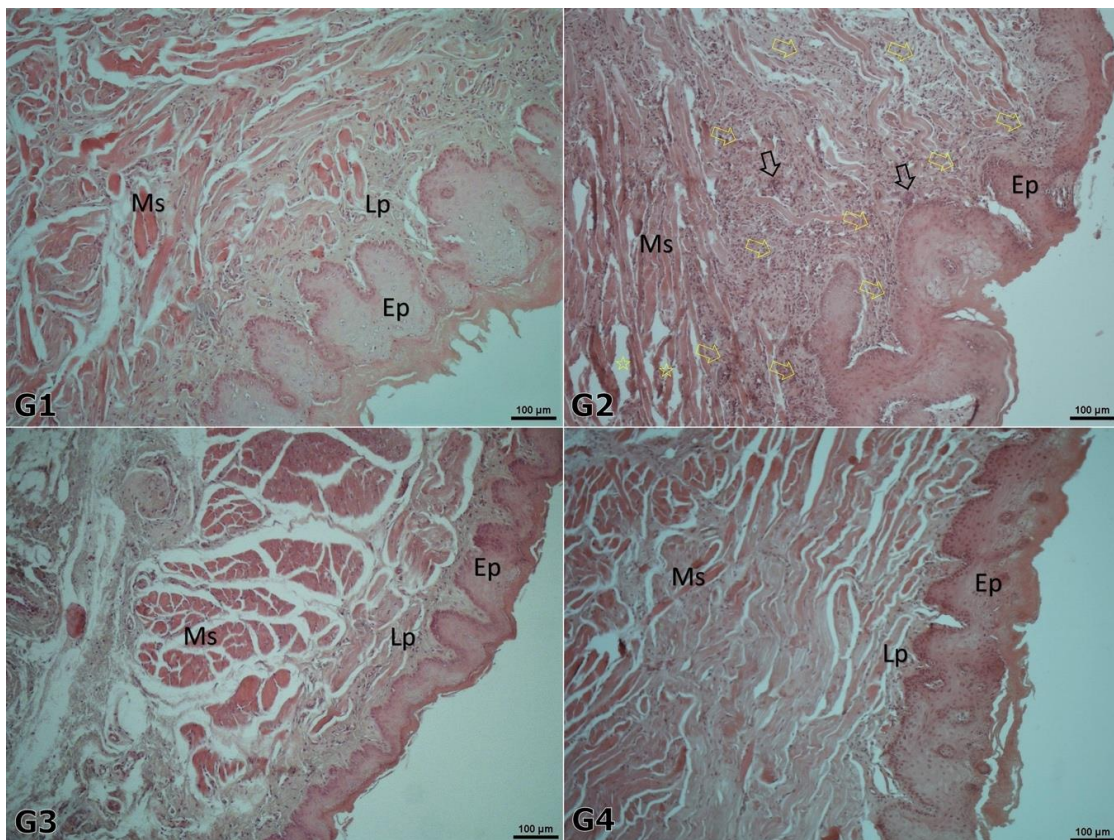


Figure 2 Representative microscopic images indicating histomorphological changes in study groups. (Ep: epithelium, Lp: Lamina propria, Ms: Muscle). G1: control group, G2: Radiotherapy, G3: 100 mg/kg/ml propolis, and G4: 200 mg/kg/ml propolis. In G1, normal

histological buccal mucosa pattern is observed. In G2, histopathological alterations such as, dense inflammatory cells (yellow arrows), micro abscesses (black arrows), necrotic areas (yellow stars), epithelial irregularity, and decrease in epithelial tissue thickness were evident. However, in G3 and G4, the tissue damage was greatly reduced and the normal appearance is mostly seen as a normal buccal mucosa histological pattern.

Table 3 The correlation between the study groups and tissue inflammation scores

Inflammation scores	Group 1	Group 2	Group 3	Group 4	Total	<i>P</i> -value
None (Score:0)	4 57.1%	0 0%	0 0%	0 0%	4 11.8%	0.002*
Giant cells, Lymphocytes, Plasma cells (Score:1)	3 42.9%	0 0%	3 33.3%	2 22.2%	8 23.5%	
Giant cells, Plasma cells, Eosinophils, Neutrophils (Score:2)	0 0%	0 0%	4 44.4%	4 44.4%	8 23.5%	
Many inflammatory cells, Microabcess (Score:3)	0 0%	9 100%	2 22.2%	3 33.3%	14 41.2%	
Total	7 20.6%	9 26.5%	9 26.5%	9 26.5%	34 100%	

* indicates *P* value below 0.05 obtained by chi-square (χ^2) tests. Group 2=15 Gy Radiotherapy group; Group 3=15 Gy Radiotherapy+systemic application of propolis extract at a dose of 100 mg/kg/ml for 2 weeks; Group 4=15 Gy Radiotherapy+systemic application of propolis extract at a dose of 200 mg/kg/ml

DISCUSSIONS

Regarding the current results of the study, oral systemic administration of propolis demonstrated ameliorative effects in the formation of radiotherapy-induced oral mucositis. The affirmative effects of propolis on RIOM was directly proportionate to administration dosage. The significant difference between the tissue IL-6 levels among the study groups, in which propolis was administered, indicated that the anti-inflammatory effects of propolis may increase in a dose-dependent manner.

The pathophysiology of RIOM still remains unclear. However, recent studies have revealed four phases of mechanisms involving in pathophysiology. Due to a study conducted to elucidate the pathophysiology; the formation of a RIOM initiates with DNA damage induced by radiotherapy in epithelial,

vascular endothelial cells, fibroblasts and tissue macrophages and reactive oxygen species (ROS) are released. The DNA damage and ROS lead to matrix metalloproteinase stimulation, the gene expression and release of pro-inflammatory cytokines such as TNF- α , IL-1, and IL-6. Also, ceramide pathway takes place with the mentioned inflammatory factors and lead the tissue injury and stimulated apoptosis. The ongoing reactions cause tissue ulcerations and secondary infections on the ulcerated tissues add more inflammation to the micro-environment (17). Therefore in the current study, the effects of systemic administration of propolis, known to have radioprotective, anti-inflammatory, and antioxidant effects, on RIOM 2 were evaluated. In a previous study, topically administered hydroalcoholic extract of red propolis kept tissue MPO activity on

ultraviolet irradiated dermal tissues at a level similar to that of non-irradiated tissues, and exhibited anti-inflammatory effects in oral administration. Consequently, it has been claimed that propolis has photoprotective effect in topical application and anti-inflammatory effects in systemic application (18). Also, the anti-inflammatory effects of propolis were indicated in murine models, by reducing IL-6 in chronic knee joint arthritis and by inhibiting neutrophil migration, leukocyte rolling and adhesion in LPS-mediated acute peritonitis (19). Consistent with the literature, it was observed in the current study that propolis dose-dependently reduced inflammation biomarkers. The doses of propolis used in the current study were drawn from previous studies that reported successful outcomes (13,20) and no toxic effects were observed in any study groups. Also, in studies on lethal doses of propolis have not reported any toxic effects up to 3000 mg/kg in rats (21).

Previous studies have shown that propolis has high free radical scavenging effects. The free radical scavenging effect of propolis is based on organic aromatic acids, which are high in its content (22). Caffeic acid phenyl ester (CAPE) containing caffeic acid is an important component of aqueous propolis extracts and has been shown to prevent the increase in TNF caused by radiotherapy-

mediated nuclear transcription factor-kappa B elevation (23). Besides, the anti-apoptotic mechanisms of action of CAPE in human peripheral blood mononuclear cells were elucidated (24). Therefore, the use of water-soluble propolis with high CAPE content has produced favorable outcomes.

To the authors' knowledge, the present study is the first to evaluate the outcomes of systemic propolis administration on RIOM formed in the buccal mucosa in an experimental animal model. However, in the current study, systemic propolis application after radiotherapy did not allow to observe the possible protective effects of propolis prior to the radiotherapy. In future studies, it would be beneficial to evaluate the effectiveness of systemic propolis applications concerning the effective doses, chemical composition, timing and routes of administration in controlled studies along with compound analysis.

CONCLUSIONS

1. Inflammatory processes take place in the formation of RIOM after head and neck radiotherapy, and oral systemic administration of water-soluble propolis has significant effects by suppressing inflammatory mediators in rats.
2. The current outcomes may pave the way for new measures to prevent RIOM that occur after radiation exposure.

REFERENCES

1. Satheeshkumar PS, Chamba MS, Balan A, Sreelatha KT, Bhatathiri VN, Bose T. Effectiveness of triclosan in the management of radiation-induced oral mucositis: A randomized clinical trial. *J Cancer Res Ther.* 2010;6(4):466–72.
2. Noronha V, Araujo G, Gomes R, Iwanaga S, Barbosa M, Abdo E, et al. Mucoadhesive Propolis Gel for Prevention of Radiation-Induced Oral Mucositis. *Curr Clin Pharmacol.* 2014;9(4):359–64.
3. Rose-Ped AM, Bellm LA, Epstein JB, Trotti A, Gwede C, Fuchs HJ. Complications of radiation therapy for head and neck cancers: The patient's perspective. *Cancer Nurs.* 2002 Dec;25(6):461–9.
4. Trotti A, Bellm LA, Epstein JB, Frame D, Fuchs HJ, Gwede CK, et al. Mucositis incidence, severity and associated outcomes in patients with head and neck cancer receiving radiotherapy with or without chemotherapy: A systematic literature review. *Radiother Oncol.* 2003

- Mar;66(3):253–62.
5. Saadeh CE. Chemotherapy- and radiotherapy-induced oral mucositis: Review of preventive strategies and treatment. *Pharmacotherapy*. 2005 Apr;25(4):540–54.
 6. Maria OM, Eliopoulos N, Muanza T. Radiation-Induced Oral Mucositis. *Front Oncol*. 2017;7(MAY):89.
 7. Stokman MA, Spijkervet FKL, Boezen HM, Schouten JP, Roodenburg JLN, De Vries EGE. Preventive intervention possibilities in radiotherapy- and chemotherapy-induced oral mucositis: Results of meta-analyses. *J Dent Res*. 2006 Aug;85(8):690–700.
 8. Schmidt W, Rainville LC, Mceneff G, Sheehan D, Quinn B. A proteomic evaluation of the effects of the pharmaceuticals diclofenac and gemfibrozil on marine mussels (*Mytilus* spp.): Evidence for chronic sublethal effects on stress-response proteins. *Drug Test Anal*. 2014 Mar;6(3):210–9.
 9. Kusiak A, Alicjajereczek-Fossa B, Cichońska D, Alterio D. Oncological-therapy related oral mucositis as an interdisciplinary problem—literature review. *Int J Environ Res Public Health*. 2020;17(7).
 10. Chamberlain G, Fox J, Ashton B, Middleton J. Concise Review: Mesenchymal Stem Cells: Their Phenotype, Differentiation Capacity, Immunological Features, and Potential for Homing. *Stem Cells*. 2007 Nov;25(11):2739–49.
 11. Elad S, Cheng KKF, Lalla R V., Yarom N, Hong C, Logan RM, et al. MASCC/ISOO clinical practice guidelines for the management of mucositis secondary to cancer therapy. *Cancer*. 2020;126(19):4423–31.
 12. Singla S, Kumar N, Kaur J. In vivo studies on the protective effect of propolis on doxorubicin-induced toxicity in liver of male rats. *Toxicol Int*. 2014 May;21(2):191–5.
 13. Ghassemi L, Zabihi E, Mahdavi R, Seyedmajidi M, Akram S, Motalebnejad M. The effect of ethanolic extract of propolis on radiation induced mucositis in rats. *Saudi Med J*. 2010;31(6):622–6.
 14. Çetinkaya ÖA, Çelik SU, Hasırcı N, Gürel M. Effects of intraperitoneal administration of simvastatin on collagen deposition, inflammation level and wound tension in an experimental incisional wound model. *Acta Oncol Turc*. 2020;53(1):181–8.
 15. Ivanovska ND, Dimov VB, Bankova VS, Popov SS. Immunomodulatory action of propolis. VI. Influence of a water soluble derivative on complement activity in vivo. *J Ethnopharmacol*. 1995 Jul;47(3):145–7.
 16. Faul F, Erdfelder E, Lang AG, Buchner A. G*Power 3: A flexible statistical power analysis program for the social, behavioral, and biomedical sciences. *Behav Res Methods*. 2007;39(2):175–91.
 17. Redding SW. Cancer therapy-related oral mucositis. *J Dent Educ*. 2005 Aug;69(8):919–29.
 18. Batista CM, Alves AVF, Queiroz LA, Lima BS, Araújo AAS, de Albuquerque Júnior RLC, et al. The photoprotective and anti-inflammatory activity of red propolis extract in rats. *J Photochem Photobiol B Biol*. 2018;180:198–207.
 19. Franchin M, Colón DF, Da Cunha MG, Castanheira FVS, Saraiva ALL, Bueno-Silva B, et al. Neovestitol, an isoflavonoid isolated from Brazilian red propolis, reduces acute and chronic inflammation: Involvement of nitric oxide and IL-6. *Sci Rep*. 2016;6(February):1–12.
 20. Benderli Cihan Y, Deniz K. [Effect of propolis against radiation-induced oral mucositis in rats]. *Kulak Burun Bogaz Ihtis Derg [Internet]*. 2011;21(1):32–41. Available from: <http://www.ncbi.nlm.nih.gov/pubmed/21303315>
 21. El Adham EK, Hassan AI, A. Dawoud MM. Evaluating the role of propolis and bee venom on the oxidative stress induced by gamma rays in rats. *Sci Rep [Internet]*. 2022;12(1):1–22. Available from: <https://doi.org/10.1038/s41598-022-05979-1>
 22. Benkovic V, Horvat Knezevic A, Dikic D, Lisicic D, Orsolcic N, Basic I, et al. Radioprotective effects of propolis and quercetin in γ -irradiated mice evaluated by the alkaline comet assay. *Phytomedicine*. 2008 Oct;15(10):851–8.
 23. Khayyal MT, Abdel-Naby DH, El-Ghazaly MA. Propolis extract protects against radiation-induced intestinal mucositis through anti-apoptotic mechanisms. *Environ Sci Pollut Res*.

- 2019;26(24):24672–82.
24. Khanduja KL, Avti PK, Kumar S, Mittal N, Sohi KK, Pathak CM. Anti-apoptotic activity of caffeic acid, ellagic acid and ferulic acid in normal human peripheral blood mononuclear cells: A Bcl-2 independent mechanism. *Biochim Biophys Acta - Gen Subj.* 2006 Feb;1760(2):283–9.