

THE ROLE OF SUBMUCOSAL DEXAMETHASONE INJECTION IN REDUCING COMPLICATIONS AFTER LOWER THIRD MOLAR SURGERY

Horatiu Urechescu¹, Anca Tudor², Victor-Vlad Costan^{3*}, Serban Talpos¹, Marius Pricop¹

¹University of Medicine and Pharmacy “Victor Babes”, Timisoara, Romania, Department of Maxillofacial Surgery

² University of Medicine and Pharmacy “Victor Babes”, Timisoara, Romania, Department of Functional Sciences

³ University of Medicine and Pharmacy “Grigore T. Popa”, Iasi, Romania, Department of Oral and Maxillofacial Surgery

Corresponding author; *e-mail*: victorcostan@gmail.com

ABSTRACT

Aim of the study Prophylaxis of inflammatory complications resulting after lower third molar surgery remains a common topic. The data found in the literature come with solutions for submucosal injection of a dose of dexamethasone. The aim of this paper is to determine the dose of dexamethasone which has an antiplatelet effect and which would suppress exudative edema and to demonstrate the effectiveness of this technique.

Material and methods We performed a clinical trial in which we analysed the effect of a 4 mg dose of dexamethasone injected submucosal into a group of patients who underwent surgery to remove a lower third molar. We compared the results with a control group in which only the surgical removal of the third lower molar was performed. **Results** Statistical analysis of the results showed a low severity in postoperative complications for patients who were injected submucosal with dexamethasone. They showed better amplitude of mouth opening and reduced pain. **Conclusions** Submucosal injection of a 4 mg dose of dexamethasone provides increased postoperative comfort for a patient who has undergone surgery to remove a lower third molar.

Key words: third molar surgery, dexamethasone, inflammatory complications.

INTRODUCTION

An impacted tooth is a partially or completely unerupted tooth that is unlikely to erupt due to its anatomical position.¹ The third molar impaction is occurring in about 73% of the young adults in Europe.²

The impaction of the lower third molar is caused by insufficient space between the anterior border of the ascending ramus of the mandible and the second molar, the compact bone that the tooth has to “go through”, third molar vicious position and the evolution of the human race along with the diet of modern man.³

Surgical removal of the included lower third molar is one of the most commonly

performed oral surgery procedures. This procedure involves mucosal incisions, flap reflection, bone removal or tooth sectioning. All this leads to postoperative sequelae such as pain, edema, trismus that reduce the quality of life for the patient.^{4,5,6}

In order to minimize postoperative sequelae related to third molar surgery, different treatment protocols have been proposed. One method is the use of corticosteroids to control postoperative pain and inflammation.^{7,8} Glucocorticosteroids inhibit inflammation and are utilized to relieve pain and reduce trismus and edema. The most commonly used corticosteroid in oral surgery is dexamethasone (dex), which is

a synthetic glucocorticosteroid and has potent anti-inflammatory effects that are 20–30-fold greater than natural corticosteroids.^{9,10,11}

There are many studies in the literature regarding the administration of dexamethasone in case of lower third molar surgery, but no consensus has been reached on timing, dose and route of administration.¹²

Dexamethasone is used due to its anti-inflammatory activity and proven safety. It inhibits vascular dilation and fluid transudation and decreases cell turnover through inhibition and chemotaxis of inflammatory cells that produce several inflammatory mediators.^{12,13} Diabetes mellitus, peptic ulcers, tuberculosis, hypertension, ocular herpes, glaucoma, Cushing's syndrome, renal insufficiency and pregnancy, all are contraindications to dexamethasone.¹⁴

MATERIAL AND METHODS

In this randomized and comparative study, we wanted to observe the effects of postoperative submucosal administration of 4 mg dexamethasone in case of surgical extraction of lower third molar.

Records from 20 patients who had undergone third molar surgery with a conventional rotary device were evaluated.

Inclusion criteria:

- asymptomatic lower third molar impaction;
- clinically healthy patients who were not on medication that could interfere with postoperative healing;
- patients who show no signs of acute inflammatory infection, such as pericoronitis, periodontal disease;

Exclusion criteria:

- pregnant or breastfeeding women;
- patients with associated general medical conditions;
- patients with contraindications to

dexamethasone;

- patients who refused to receive dexamethasone;

The selected patients were randomly divided into 2 groups.

- Group 1 - control group
- Group 2 - dexamethasone group

The control group consisted of 10 patients who underwent surgery with a conventional rotary device and the dexamethasone group consisted of 10 patients who underwent surgery with the conventional rotary device in combination with postoperative submucosal 4 mg dexamethasone injections.

Surgery was performed by the same surgeon using the same technique for all the patients. Inferior alveolar and buccal nerve blocks was provided by administration of 4 % articaine in a 1:100,000 ratio with epinephrine. Triangular full thickness flap was used and osteotomies were done with conventional rotary device at 35000 rpm. Wound closure was done with a 4–0 supramid suture. Submucosal dexamethasone (4mg/ml) infiltrations were performed immediately postoperative for patients in group 2.

All patients received postoperative medication, including amoxicillin clavulanic acid (875/125 mg every 12 h for 5 days), ibuprofen (400mg every 12h). The sutures were removed seven days after surgery.

Postoperative edema was evaluated by measuring the following distances: Tragus-Pogonion, Tragus - buccal commissure, Gonion - lateral corner of the eye. To determine the amplitude of the mouth opening, we measured the distance between the upper incisors and the lower incisors. The measurements were in mm and were performed preoperatively, on the same day with the intervention, and postoperatively, at 24 hours and 7 days.

We determined the intensity of the pain by

questioning the patient and asking him to give us a grade using a scale from 0 to 10.

A database was created in Microsoft Excel.

Statistical analysis was performed in SPSSv17 and Microsoft Excel. In case of nominal variables, frequency tables were prepared together with pie charts. For numerical variables, mean values, standard deviations, minimum and maximum values, medians, and ranks were calculated.

RESULTS

Regarding the distribution of patients in both working groups, out of the total of 20 patients, 13 (65%) were female patients and 7 (35%) were male patients. Patients included in the study ranged in age from 19 to 35 years old. Of the total impacted lower third molars that were extracted, 8 of them were located on the left side (3.8) and 12 on the right side (4.8), and their percentage distribution was 40% in the case of the 3.8 molars and 60% in the case of the molars 4.8.

The amplitude of the mouth opening (MO) on day 2 is significantly increased for Group 2 ($p < 0.001$) (Table 1, Fig. 1).

Pain (P) on day 2 is significantly lower for the dexamethasone group compared to the control group ($p < 0.001$) (Table 1).

Regarding postoperative edema, there are no significant differences between the two groups (Table 1).

Regarding the comparison between days 1, 2 and 7, regardless of the group of patients, the results show that on day 2 the values of Tragus - Pogonion (Tr-Pog), Tragus - buccal commissure (Tr-Com) and Gonian - lateral corner of the eye (Go-Ce) measurements are significantly higher compared to days 1 and 7 (Friedman Test, p

Histogram, column and boxplot charts were drawn. The comparisons between the numerical series were performed with the non-parametric Mann-Whitney tests in the case of comparisons between the 2 sets of values with non-gaussian distribution and with the non-parametric Friedman test between the 3 time points. The value $p < 0.05$ indicates significant differences.

< 0.001) (Table 3,4,5). Also, on day 2, the amplitude of the mouth opening (MO) is significantly lower than on days 1 and 7 (Friedman Test, $p = 0.002$) (Table 6) and the pain (P) on day 2 is significantly higher compared to days 1 and 7 (Friedman Test, $p < 0.001$) (Table 7).

Table 1. The two groups on day 2

Group 1 vs Group 2	Tr-Pog2	Tr-Com2	Go-Ce2	MO2	P2
P values	0.143	0.529	0.912	<0.001	<0.001

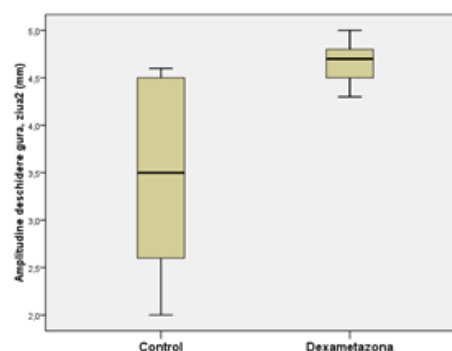


Figure 1. Boxplot for MO values on day 2, comparison between groups

Table 2. The two groups on day 7

Group 1 vs Group 2	Tr-Pog7	Tr-Com7	Go-Ce7	MO7	P7
--------------------	---------	---------	--------	-----	----

P values	0.353	0.029	0.063	0.739	1.000
----------	-------	-------	-------	-------	-------

Table 3. On day 2, Tr-Pog values are significantly higher than on days 1 and 7 (Friedman Test, $p < 0.001$).

Tr-Pog	N	Mean	Std. Deviation	Minimum	Maximum	50th (Median)	Mean Rank
Day 1	20	14,710	,9470	12,5	16,8	14,500	1,53
Day 2	20	15,325	1,0088	13,5	17,5	15,000	2,85
Day 7	20	14,750	,9406	12,8	16,8	14,500	1,63

Table 4. On day 2, Tr-Com values are significantly higher than on days 1 and 7 (Friedman Test, $p < 0.001$).

Tr-Com	N	Mean	Std. Deviation	Minimum	Maximum	50th (Median)	Mean Rank
Day 1	20	12,000	,9364	10,5	14,0	12,000	1,68
Day 2	20	12,485	,9371	11,0	14,8	12,400	2,60
Day 7	20	12,025	,9147	10,5	14,0	12,000	1,73

Table 5. On day 2, Go-Ce values are significantly higher than on days 1 and 7 (Friedman Test, $p < 0.001$).

Go-Ce	N	Mean	Std. Deviation	Minimum	Maximum	50th (Median)	Mean Rank
Day 1	20	10,125	,9765	8,0	12,5	10,150	1,50
Day 2	20	10,795	1,1799	8,3	13,5	10,750	2,90
Day 7	20	10,165	,9740	8,0	12,5	10,150	1,60

Table 6. On day 2, MO values are significantly lower than on days 1 and 7 (Friedman Test, $p = 0.002$).

MO	N	Mean	Std. Deviation	Minimum	Maximum	50th (Median)	Mean Rank
Day 1	20	4,820	,5268	4,0	6,5	4,700	2,38
Day 2	20	4,075	,9037	2,0	5,0	4,500	1,50
Day 7	20	4,745	,5671	3,8	6,5	4,700	2,13

Table 7. On day 2, the pain is significantly higher than on days 1 and 7 (Friedman Test, $p < 0.001$).

P	N	Minimum	Maximum	50th (Median)	Mean Rank
Day 1	20	0	0	,00	1,58
Day 2	20	0	8	3,50	2,85
Day 7	20	0	0	,00	1,58

DISCUSSIONS

The main inflammatory sequelae after

lower third molar surgery are represented by pain, edema and decreased amplitude of the

mouth opening. These complications are also influenced by a number of local factors such as the position of the impacted tooth and bone density, but also by preoperative planning, surgical technique and the surgeon's experience. A very important aspect is related to the way in which the periodontal bone is removed. This can be done with either a conventional rotary instrument or a piezotome. Active irrigation during this operation is mandatory to prevent uncontrolled heat that would lead to bone necrosis and healing complications.

The administration of anti-inflammatory drugs is often used to limit postoperative complications. Dexamethasone is a commonly used corticosteroid due to its longer duration of action and strong anti-inflammatory effect.

Several routes to administering dexamethasone in association with oral surgery had been described, among them submucosal, intramuscular, intra-alveolar and intravenous, all with advantages and disadvantages in case of third molar surgery.^{15,16,17}

The dose has not yet been determined, with various studies in the literature ranging from 4 mg to 8 mg dexamethasone.¹⁷ The dosing remains arbitrary depending on the difficulty of surgery and patient tolerance.¹¹

Regarding the timing of administration, there are clinical trials in the literature referring both to preoperative and postoperative administration for third molar surgery.

Several studies in the literature have

found that the use of dexamethasone significantly reduce the postoperative complications after lower third molar surgery. Regarding our study, we did not observe any significant differences related to postoperative edema between the control group and the group of dexamethasone patients. There were statistically significant differences in pain and trismus in favour of the group of patients who were administered postoperatively dexamethasone. These differences occurred on day 2 and can be attributed to the anti-inflammatory effect of dexamethasone. On day 7 there were no differences between the two groups.

Regarding the postoperative evolution, the study showed that by day 7 the postoperative sequelae remit regardless of the group of patients, the maximum being on day 2.

CONCLUSIONS

Taking into account data from the literature, perioperative submucosal injection of dexamethasone in case of lower third molar surgery is effective for reducing postoperative edema, pain and trismus.

The data obtained by us show a significant improvement related to pain and trismus in the second postoperative day for patients who received 4mg dexamethasone submucosal postoperatively.

REFERENCES

1. Janakiraman EN, Alexander M, Sanjay P. Prospective analysis of frequency and contributing factors of nerve injuries following third-molar surgery. *J Craniofac Surg.* 2010 May;21(3):784-6.
2. Matsuyama J, Kinoshita-Kawano S, Hayashi-Sakai S, Mitomi T, Sano-Asahito T. Severe impaction of the primary mandibular second molar accompanied by displacement of the permanent second premolar. *Case Rep Dent.* 2015;2015:582462.
3. Santosh P. Impacted Mandibular Third Molars: Review of Literature and a Proposal of a Combined Clinical and Radiological Classification. *Ann Med Health Sci Res.* 2015 Jul-Aug;5(4):229-34.
4. Saravanan K, Kannan R, John RR, Nath Kumar C. A single pre operative dose of submucosal

- dexamethasone is effective in improving post-operative quality of life in the surgical management of impacted third molars: a comparative randomised prospective study. *J Maxillofac Oral Surg* 2016;15:67–71.
5. Moraschini V, Hidalgo R, Porto Barbazo E. Effect of submucosal injection of dexamethasone after third molar surgery: a meta-analysis of randomized controlled trials. *Int J Oral Maxillofac Surg* 2016;45:232–40.
 6. Gümrukçü Z. The effects of piezosurgery and submucosal dexamethasone injection on post-operative complications after third molar surgery. *J Stomatol Oral Maxillofac Surg*. 2019 Jun;120(3):182-187.
 7. Mutlu I, Abubaker AO, Laskin DM. Narcotic prescribing habits and other methods of pain control by oral and maxillofacial surgeons after impacted third molar removal. *J Oral Maxillofac Surg* 2013;71:1500-3.
 8. Herrera-Briones FJ, Prados Sánchez E, Reyes Botella C, Vallecillo Capilla M. Update on the use of corticosteroids in third molar surgery: systematic review of the literature. *Oral Surg Oral Med Oral Pathol Oral Radiol*. 2013 Nov;116(5):e342-51
 9. Bortoluzzi MC, Capella DL, Barbieri T, Pagliarini M, Cavalieri T, Manfro R. A single dose of amoxicillin and dexamethasone for prevention of post-operative complications in third molar surgery: a randomized, double-blind, placebo controlled clinical trial. *J Clin Med Res* 2013;5:26–33.
 10. Boonsiriseth K, Klongnoi B, Sirintawat N, Saengsiravin C, Wongsirichat N. Comparative study of the effect of dexamethasone injection and consumption in lower third molar surgery. *Int J Oral Maxillofac Surg* 2012;41:244–7.
 11. Antunes AA, Avelar RL, Martins Neto EC, Frota R, Dias E. Effect of two routes of administration of dexamethasone on pain, edema, and trismus in impacted lower third molar surgery. *Oral Maxillofac Surg* 2011;15:217-23.
 12. Selvido DI, Bhattarai BP, Niyomtham N, Riddhabhaya A, Vongsawan K, Pairuchvej V, Wongsirichat N. Review of dexamethasone administration for management of complications in postoperative third molar surgery. *J Korean Assoc Oral Maxillofac Surg*. 2021 Oct 31;47(5):341-350.
 13. Nandini GD. Eventuality of dexamethasone injected intra-massetrically on post-operative sequel following the surgical extraction of impacted mandibular third molars: a prospective study. *J Maxillofac Oral Surg* 2016;15:456–60.
 14. Dhanavelu P, Shanmugapriyan S, Ebenezer V, Balakrishnan B, Elumalai M. Dexamethasone for third molar surgery- a review. *Int J Pharm Bio Sci* 2013;4:9-13.
 15. Klongnoi B, Kaewpradub P, Boonsiriseth K, Wongsirichat N. Effect of single dose preoperative intramuscular dexamethasone injection on lower impacted third molar surgery. *Int J Oral Maxillofac Surg* 2012;41:376-9.
 16. Bhargava D, Sreekumar K, Deshpande A. Effects of intra-space injection of Twin mix versus intraoral-submucosal, intramuscular, intravenous and per-oral administration of dexamethasone on postoperative sequelae after mandibular impacted third molar surgery: a preliminary clinical comparative study. *Oral Maxillofac Surg* 2014;18:293-6.
 17. Sabhlok S, Kenjale P, Mony D, Khatri I, Kumar P. Randomized controlled trial to evaluate the efficacy of oral dexamethasone and intramuscular dexamethasone in mandibular third molar surgeries. *J Clin Diagn Res* 2015;9:ZC48-51.