

ASPECTS OF AESTHETIC REHABILITATION USING DIGITAL SMILE DESIGN

Elena Luca¹, Cristina Iordache², Oana Țânculescu¹, Zenaida Surlari¹, Dragoș Virvescu¹, Laura Checheriță¹, Arina Ciocan-Pendefunda¹, Maria-Antonela Beldiman³

"Grigore T.Popa" University of Medicine and Pharmacy of Iasi, Faculty of Dental Medicine

¹Prosthodontics Department

^{2,3}Implantology, Removable Dentures, Technology Department

Corresponding author: Iordache Cristina, e-mail: cmmiordache@yahoo.com

Surlari Zenaida, e-mail: zinaamaseluta@yahoo.com

ABSTRACT

The main purpose of oral rehabilitation is to restore the aesthetic appearance, to the dental level in accordance with the surrounding tissues and correlated with the facial appearance. In the last period of time, there were developed and introduced several computer software programs for Digital Smile Design (DSD), both in research activity and in clinical practice. **Material and methods** A 36-year-old female patient with aesthetic and functional disturbances, were evaluated in order to a complex rehabilitation treatment plan. Because there was complete mouth rehabilitation necessary, we decided to use the Digital Smile Design, after the initial clinical examination – all facial aspects, dental and gingival contours elements. **Results** After the Digital Smile Design simulation, the team dentist-dental technician decided to prepare a mock-up for a better and realistic image of the future prosthetic rehabilitation. **Conclusions:** The use of Digital Smile Design offers the possibility of restoring aesthetic aspects, correlated with the understanding of the dynamic movement and the connections between the teeth, gums, lips and smile, in order to increase the level of satisfaction of the patient with the complex prosthetic treatment.

Key words: Digital Smile Design, Mock-up, Aesthetic Rehabilitation

INTRODUCTION

The main purpose of oral rehabilitation is to restore the aesthetic appearance, to the dental level in accordance with the surrounding tissues and correlated with the facial appearance. Thus, it is necessary to evaluate all these aspects by smile and face analysis, objectively and with the help of previously established marks, in order to obtain the best aesthetic results.

In the last period of time, there were developed and introduced several computer software programs for Digital Smile Design (DSD), both in research activity and in

clinical practice. These software programs are multi-use conceptual tools that can strengthen diagnostic vision, improve communication, and enhance treatment predictability, by permitting careful analysis of the patient's facial and dental characteristics that may have been overlooked by clinical, photographic or diagnostic cast based evaluation procedures (Coachman and Calamita, 2012)¹.

Digital Smile Design is a modern technique for complex and complete dental rehabilitation planning, which allows planning of the main details for the doctor, and for the patient an accurate and real

understanding of the prosthetic treatment that will be applied. The program offers the possibility of a digital design of the patient's smile as well as a temporary representation of the smile for the patient.

Smile aesthetics are related to the form, texture, colour, and alignment of the anterior teeth as well as to intraoral soft tissues, lips, and facial aesthetics.² An important objective of an aesthetic treatment is that the final result should be as close as possible to the patient's expectations, improving the facial aesthetics and smile.^{2,3,4}

MATERIAL AND METHODS

A 36-year-old female patient with aesthetic and functional disturbances determined by the absence of upper central incisor and upper premolars on the maxillary dental arch, and the absence of lower premolars and first lower molars on the mandibular arch, were evaluated in order to an complex rehabilitation treatment plan.

Because there was complete mouth rehabilitation necessary, we decided to use the Digital Smile Design, after the initial clinical examination – all facial aspects, dental and gingival contours elements.

Digital Smile Design plan included

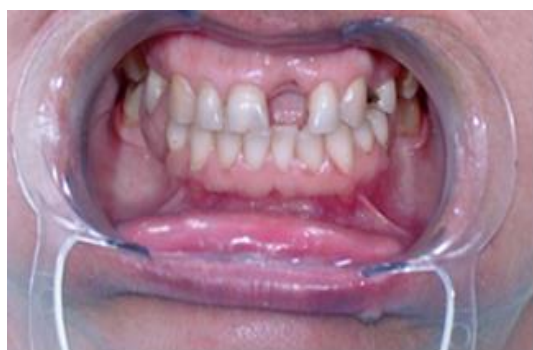

Figure 1. Intra-oral photo for initial

RESULTS AND DISCUSSIONS

After the Digital Smile Design simulation, the team dentist-dental technician decided to prepare a mock-up for a better and realistic image of the future prosthetic rehabilitation.

intraoral photographs, photographs of a bite, and side photographs of a bite, photographs of upper and lower jaw surface, isolated upper and lower jaw, lines and digital drawings that are inserted on the facial and intraoral photographs of the patient. (Fig.1)

For the extra-oral photographs, there is necessary to record the mimic of the patient's face and other parameters of aesthetics we will use to plan the prosthetic rehabilitation. (Fig. 2)

The Digital Smile Design program opened on the initial page with the first photo, we had first take the two lines to place it in the central part, than we marked the interpupillary line for the horizontal plane. We also marked the mid-facial line based on some facial-references – nose, chin, in order to have no interference from the dental position, angle or midline.

After that, we transferred the first line to the smile region, to allow in this way, the positioning of the smile, and analyse the teeth and the face. For smile aesthetic it is important to have a good proportion between teeth and their position in the arch, to analyse the dental contour according to the lower lip proportions and the antero-posterior curvature of the teeth. (Fig. 3)

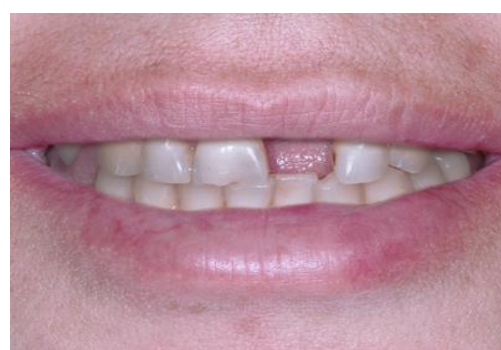

Figure 2. Image of smile line examination

(Fig. 6)

Facial analysis is performed using reference lines from which standardized parameters have been developed for frontal and profile views of the face. The horizontal

reference lines used in frontal analysis include the inter-pupillary and inter-commissural lines that provide an overall sense of harmony and horizontal perspective in the aesthetically pleasing face (Chiche and Pinault, 2004, Cohen, 2007)⁵, while the vertical reference lines include the facial midline, dental midline and mandibular midline.

The dental analysis will render the conclusive size, shape and colour of the restored teeth. There have been several theories used to define adequate tooth dimension which include the golden proportion (Priya et al., 2013)⁶, width to length ratio (McLaren and Culp, 2013)⁷, pound's theory (Vassantha Kumar et al., 2011, Ward, 2015)⁸, recurring esthetic dental proportion (Ward, 2015)⁸, law of harmony, dentogenic theory (Farias et al., 2010,

Pedrosa et al., 2011)⁹, and, more recently, visagism (Sharma et al., 2015)¹⁰. In considering tooth colour there are four primary attributes (hue, value, chroma, and translucency) and characteristics such as texture and luster which can change the perception of the tooth shape and value (Culp et al., 2013)¹¹. (Fig. 4,5)

The use of registered information and their digital processing together with wax-up and mock-up improves the activity of the dentist-dental technician team, and represents an objective and efficient communication tool between dentist, dental technician and patient.

Digital Smile Design is a useful tool with many advantages; meanwhile the mock-up will confirm the treatment plan before the final preparations and evaluate final restorations within the limitations of biological and functional considerations.¹²

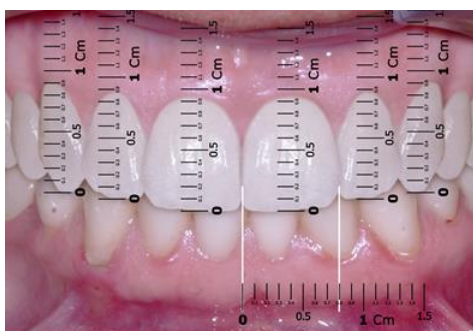


Figure 3. Analyse of the teeth proportion

Most of the times, it is important to support the digital treatment planning with a mock-up, as it gives the patient and dentist, a tri-dimensional visualization of the final result

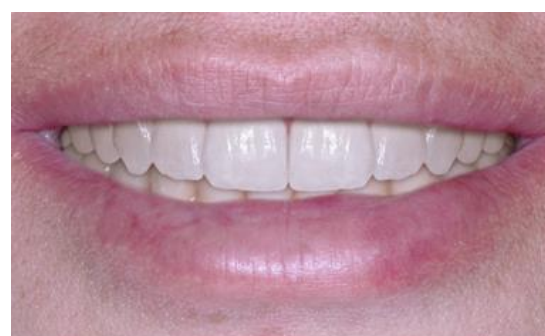

Figure 4. Digital Smile Design Simulation

of the proposed treatment as one of its big advantages¹³, the visualization of the shape integrated to the gingiva, lips, face, and phonetics, during the evaluation period¹⁴⁻¹⁸.

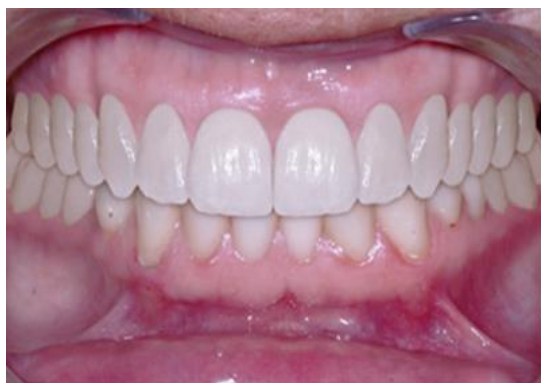

Figure 5. Intraoral view of Digital Smile Design Simulation

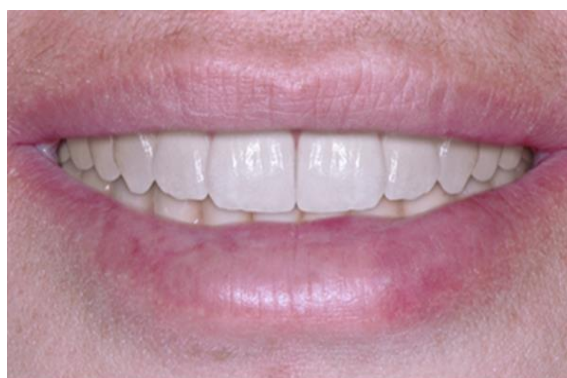

Figure 6. Mock-up of rehabilitation

CONCLUSIONS

1. Digital Smile Design software program include digital technology to obtain the best smile design, and is the most performing tool to diagnosing, visualization of a complex rehabilitation treatment plan, to explain it to the patient, to take the decision together with the dental technician.
2. The mock-up technique is necessary to complete the Digital Smile Design analyse, because is, easy and efficient

for the diagnosis and planning treatments, and for higher predictability of the results.

3. The use of Digital Smile Design offers the possibility of restoring aesthetic aspects, correlated with the understanding of the dynamic movement and the connections between the teeth, gums, lips and smile, in order to increase the level of satisfaction of the patient with the complex prosthetic treatment.

Acknowledgements

The authors would like to thank to Magic Smile Design Lab, for all the support.

REFERENCES

1. Coachman, C., Van Dooren, E., Gürel, G., Landsberg, C.J., Calamita, M.A., Bichacho, N., 2012. Smile design: from digital treatment planning to clinical reality. In: Cohen, M. (Ed.). *Interdisciplinary treatment planning, vol. 2, comprehensive case studies*. Quintessence, pp. 119–174.
2. Meereis CT, de Souza GB, Albino LG, Ogliari FA, Piva E, Lima GS, et al. Digital smile design for computer-assisted aesthetic rehabilitation: Two-year follow-up. *Oper Dent*. 2016; 41:E13–22. [PubMed] [Google Scholar]
3. Miranda ME, Olivieri KA, Rigolin FJ, de Vasconcellos AA. Esthetic challenges in rehabilitating the anterior maxilla: A Case report. *Oper Dent*. 2016; 41:2–7. [PubMed] [Google Scholar]
4. Reshad M, Cascione D, Magne P. Diagnostic mock-ups as an objective tool for predictable outcomes with porcelain laminate veneers in aesthetically demanding patients: A clinical report. *J Prosthet Dent*. 2008;99:333–9. [PubMed] [Google Scholar]osenstiel S.F., Land M.F., Fujimoto J., *Contemporary fixed prosthodontics*. St. Louis: Mosby-Year Book; 2005:51.
5. Cohen, S.E., 2007. Fundamentals of dental aesthetics: analysis. In: *Atlas of cosmetic and reconstructive periodontal surgery, third ed.*, PMPH, pp. 217–238.

6. Priya K., Rahul D.P., Varma S., Namitha R. Norms for crafting a beautiful smile. *Amirta J. Med.* 2013; 2 (9):4–9. [Google Scholar]
7. McLaren E.A., Culp L. Smile analysis: the Photoshop smile design technique part 1. *J. Cosmet. Dent.* 2013;1(29):98–108. [Google Scholar]
8. Ward H.D. Proportional smile design using: the recurring aesthetic dental proportion to correlate the widths and lengths of the maxillary anterior teeth with the size of the face. *Dent. Clin. North Am.* 2015; 59 (3):623–638. [PubMed] [Google Scholar]
9. Pedrosa V.O., Franca F.M., Florio M.F., Basting R.T. Study of the morpho-dimensional relationship between the maxillary central incisors and the face. *Braz. Oral. Res.* 2011; 25(3):210–216. [PubMed] [Google Scholar]
10. Sharma A., Luthra R., Kaur P. A photographic study on Visagism. *Indian J. Oral Sci.* 2015;6(3):122–127. [Google Scholar]
11. Culp L., McLaren E.A., Swann L.C. Smile analysis: the Photoshop smile design technique part 2. *J. Cosmet. Dent.* 2013; 2(29):94–108. [Google Scholar]
12. Gürel G. Porcelain laminate veneers: Minimal tooth preparation by design. *Dent Clin North Am.* 2007; 51:419–31, ix. [PubMed] [Google Scholar]
13. Miranda ME, Olivieri KA, Rigolin FJ, de Vasconcellos AA. Esthetic challenges in rehabilitating the anterior maxilla: A Case report. *Oper Dent.* 2016; 41:2–7. [PubMed] [Google Scholar]
14. Magne P, Magne M. Use of additive waxup and direct intraoral mock-up for enamel preservation with porcelain laminate veneers. *Eur J Esthet Dent.* 2006; 1:10–9. [PubMed] [Google Scholar]
15. Magda Ecaterina Antohe, Cristina Iordache, Gabriel Drug, The Smile Aesthetics and its Implications in Social Prosthetic Rehabilitations: A Case Report. *Biomed J Sci & Tech Res* 1(7), 2017
16. Dascălu, CG; Antohe, ME; Dimitriu, G., Particular Image Processing Techniques for Decision Support in Aesthetic Dentistry, PRACTICE OF PATIENT CENTERED CARE: EMPOWERING AND ENGAGING PATIENTS IN THE DIGITAL ERA Book Series: Studies in Health Technology and Informatics Volume: 244 Pages: 87-87 Published: 2017
17. Antohe, ME; Fornă, DA; Dascălu, CG; Fornă, NC (Fornă, Norina Consuela), The importance of observing the aesthetic requirements in partial edentulous rehabilitation - implications in medical-dental training, INTERNATIONAL JOURNAL OF EDUCATION AND INFORMATION TECHNOLOGIES, Volume: 10, Pages: 199-203, 2016
18. Antohe, ME; Fornă, DA; Dascălu, CG; Fornă, NC, Implications of Digital Image Processing in the Paraclinical Assessment of the Partially Edentated Patient, REVISTA DE CHIMIE, 69 (2), 521-524, 2018