

MAXILLARY DISTOMOLARS AT PATIENTS WITHOUT ASSOCIATED SYNDROMES: A CASE REPORT

Carmen Gabriela Stelea¹, Ovidiu Ștefănescu^{1*}, Alina Mateuță³, Marius Enașoaie³,
Oana Elena Ciurcanu¹, Cristina Popa²

¹ “Grigore T.Popa” University of Medicine and Pharmacy Iasi, Faculty of Dental Medicine, Department of Dento-Alveolar Surgery

^{1*} “Grigore T.Popa” University of Medicine and Pharmacy Iasi, Faculty of Dental Medicine, Department of Dento-Alveolar Surgery, E-mail: ovidiu_stefanescu@yahoo.com (corresponding author)

² “Grigore T.Popa” University of Medicine and Pharmacy Iasi, Faculty of Dental Medicine, Department of Oral Medicine

³ “St. Spiridon” Hospital Iasi, Department of Oral and Maxillofacial Surgery

Abstract

The distomolars are supernumerary teeth that forms behind of maxillary and mandibular third molars. The etiology of this numerary anomaly has multiple theories but none of them is fully accepted. Most of the time, supernumerary teeth are associated with genetics syndromes like labio-palatal cleft, cleidocranial dysostosis, Gardner syndrome, but at healthy patients the prevalence is very low. This study presents three cases diagnosticated at Hospital “Sf. Spiridon” Iasi, Oral and Maxillofacial department, with maxillary distomolars at patients without any associated syndromes. The anomaly did not had local complications, it was diagnosticated following paraclinic exams like panoramic radiographs and cone-beam computer tomography.

Key word : distomolars, odontectomy, wisdom tooth, supernumerary teeth, impacted teeth

Introduction

Supernumerary teeth are defined as those in addition to the normal series of deciduos or permanent dentition. In literature, for this numerary anomaly it has been used terms like supernumerary teeth, excess numerary anomaly, hiperdontia, hiperodontogenesis, dental polegenesis, pleiodontie^(1,2).

Throughout history, supernumerary teeth were found in very old human remains, but in the literature they were mentioned for the first time by Paul from Aegina, in the 7th century BC⁽³⁾. Supernumerary teeth can be single or multiple, unilateral or bilateral, erupted or impacted⁽⁴⁾. They can be observed in both dentition, but with a higher prevalence at permanent dentition, on both jaws, in anterior region. Also they can have shape or dimension anomaly, but also they can be identical with normal teeth.

The supernumerary teeth can be classified, according to the location, into mesiodens, paramolar, distomolar and parapremolar.

The etiology is not completely understood, there are different theories. Some of them support the theory of dental lamina hiperactivity according to which dental lamina

generate multiple dental buds, and from them some that should atrophy continue with normal development^(5,1). Other autors supports the atavic theory or the reverse dental formula of some elements disappeared along phylogenesis^(6,1). Another assumption is about the division of the dental bud which can explain the likeness of supranumerary teeth with normal dentition. Another theory is the ereditary one, but at the moment there are not sufficient data to firmly support the importance of genes in transmitting this anomaly^(1,7,8). Supernumerary teeth in a proportion of 13%-34 % are erupted and 73% remain impacted⁽⁹⁾.

The most frequent occurrence, in the order of frequency are: mesiodens, maxillary distomolar, maxillary parapremolar, mandibular parapremolar, supranumerar maxillary lateral incisor, mandibular distomolar.

Distomolars are supernumerary, rudimentary teeth, usually with conical shape, situated distal to the third molar, on both jaws.

In most cases, they are associated with some syndromes like Gardner syndrome, cleidocranial dysostosis or labial and palatal clefts^(10,11). They are often asymptomatics, but

sometimes they can cause neuralgial pain, pericoronaritis, cysts, tumors, rotations and malpositions of permanent teeth, crowding, eruption delays and teeth impaction⁽¹²⁾.

Due to the complications they can determine, the diagnosis of this anomaly is based on clinical and paraclinical examination such as orthopantomography, retrodentalalveolar radiographs and cone-beam computer tomography.

In the literature, there are two options regarding the treatment plan: patient monitoring or extraction of the supernumerary tooth. Patient monitoring includes clinical and radiographic follow-up to identify possible complications that may occur. If the complications are present the extraction of the supernumerary tooth is mandatory.

Cases reports

Case 1

The 16 year old female patient C.L. has been presented in the Ambulatory of Oral and Maxillofacial Surgery on Hospital "Sf. Spiridon" Iasi, referred by the orthodontist with the indication of odontectomy as part of the treatment plan for the correction of her crowding.

At the clinical examination, the patient was healthy, without personal and heredo-collateral affections. Intraoral examination revealed maxillary crowding in the area of the premolars bilaterally, mandibular crowding in frontal area, and the absence of the molars in all 4 quadrants.

The orthopantomography (fig. 1) analysis revealed the impaction of all 4 third molars and the presence of an supernumerary tooth impacted also in second quadrant in retromolar area.

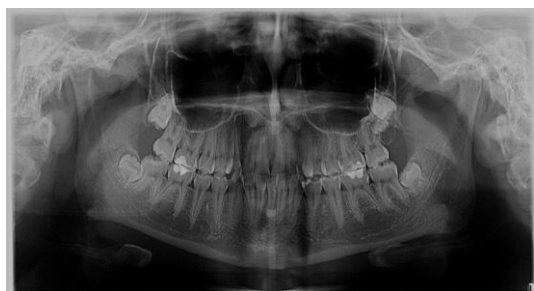

Fig.1 Orthopantomography

In order to complete the paraclinic examination, it was indicated to do CBCT, for the three dimensional observation of the positioning of the impacted third molar and the impacted distomolar, but also their relations with the neighboring anatomical elements.

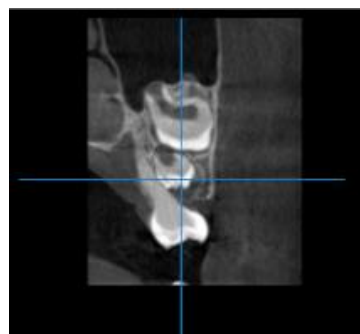


Fig. 2 CBCT image – coronal section

It can be observed that the distomolar has a vertical-oblique to the distal orientation, being located vertically and superior to the impacted third molar (Fig. 2) and the incompletely formed roots are in contact with the schneiderian membrane of the left maxillary sinus

The treatment plan consisted in odontectomy of the impacted molars under local anesthesia (fig. 3), after signing the informed consent of the patient's mother.

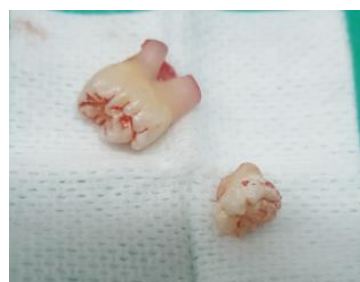

Fig. 3 Clinical view of the third molar and the distomolar after extraction

Case 2

The 27 year old female patient G.M. has been presented in the Oral and Maxillofacial Surgery Ambulator at the Hospital "Sf Spiridon" Iasi, referred by dentist for the extraction of the third molars, as part of treatment plan for future therapy of her crowding.

At the general clinical examination, the patient was healthy, without any personal or heredo-collateral affections. The intraoral

examination revealed the presence of the wisdom teeth anclaved in all four quadrans and the tooth 1.8 had deep caries with sensitivity at cold vitality test. The orthopantomography reveals the presence of impacted distomolars at the maxilla bilaterally (fig. 4).

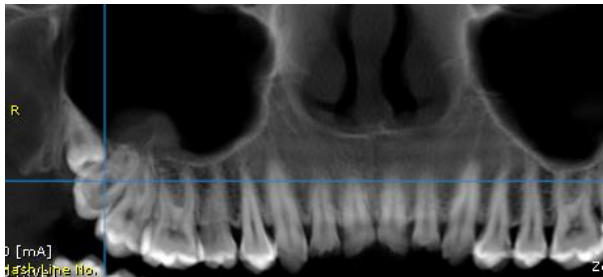


Fig. 4 Maxillary

panormic view

To determine the relationship of supernumerary teeth with the adjacent anatomical elements we have recommended the CBCT (fig. 5).

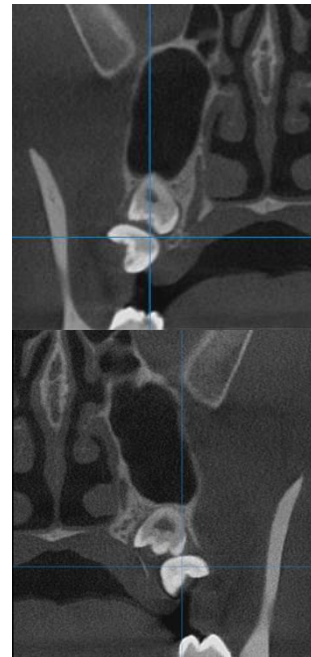


Fig. 5 CBCT cross sectional view quadrant 1 and 2

It has been pointed out that the distomolar from first quadrant was situated distal and superior to 1.8, having a vertical-oblique direction towards the medial and contacting the right maxillary sinus posterior wall and distal part of the tooth 1.8. The distomolar from second quadrant was located superior and distal to 2.8, almost vertical, in contact with left maxillary sinus by his root and in contact with the distal part of 2.8.

The treatment plan consisted in sanitizing the oral cavity, followed by the extraction of the third molars and the distomolars (fig.6)

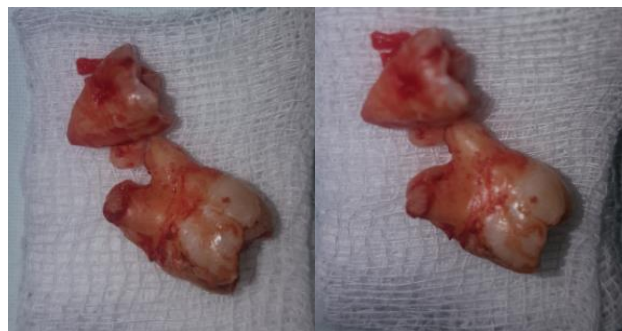

Fig. 6 Clinical image of the extracted wisdom teeth and distomolars

Clinical case 3

The 23 years old female patient B.S. was presented in the Ambulatory of Oral and examination, the diagnosis was acute pericorony disease 2.8, absence of 1.8 on

Maxillofacial Surgery at the Hospital “ Sf. Spiridon” Iasi. Following the clinical dental arch and multiple dental caries. In order to establish the diagnosis of certainty,

orthopantomography was recommended (fig. 7), which showed the inclusions of 1.8, 2.8 but

also the presence of bilaterally impacted maxillary distomolars.

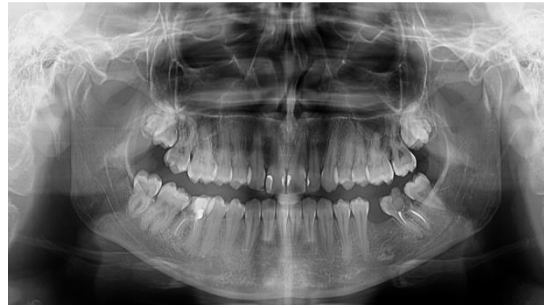

Fig. 7 The orthopantomography

To determine the relationship of supernumerary teeth with the adjacent anatomical elements, a CBCT examination was indicated (fig. 8). It has been observed that the distomolar from the first quadrant had a vertical-oblique direction to the distal and he

was in contact with the posterior wall of the right maxillary sinus. The supernumerary tooth from the second quadrant was positioned transversally vestibulo-orally with the occlusal face oriented vestibular and in contact with the palatal face of tooth 2.8

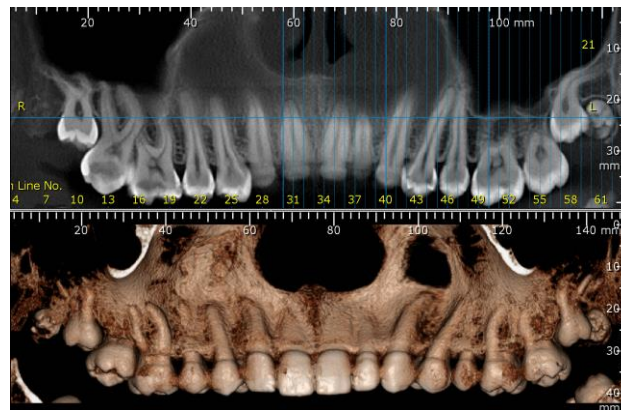


Fig. 8 CBCT : maxillary 3D and panoramic view

After treatment of the pericoronitis from the tooth 2.8, the patient was booked for

odontectomy, in separate sessions, of the molars 1.8, 2.8 and the distomolars (fig. 9).

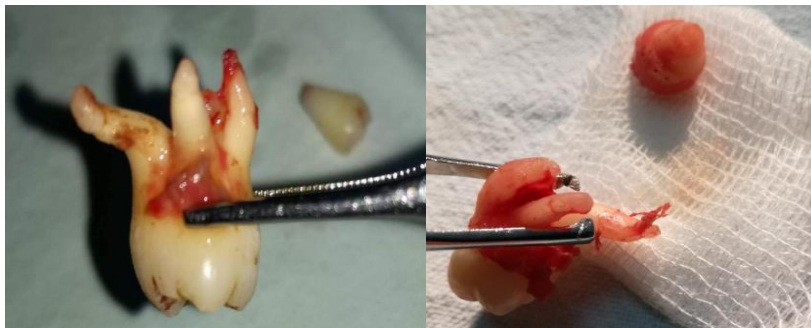

Fig. 9 Clinical aspect of teeth 1.8, 2.8 and the distomolars

Discussions

Supernumerary teeth are classified according to chronology, morphology, topography and orientation. Chronologically they can be pre-

deciduous, deciduous, permanent or complementary. From a morphological point of view, supernumerary teeth can be conic, tuberculous or odontoam. Topographically,

they are classified as mesiodens, paramolar, distomolar and parapremolar, and depending on the orientation they can be vertical or transverse.

Supernumerary teeth is a rare anomaly located at the maxilla or mandible. Numerous theories have attempted to explain the occurrence of this number anomaly, the most suggestive being the theory of heredity determined by multiple factors. The occurrence of distomolars is often associated with development disorders like labio-palatal cleft, cleidocranial dysostosis and Gardner syndrom. In this context, the occurrence of this anomaly in healthy patients it has not been explained yet, the prevalence being rare. This anomaly is more common on maxilla than the mandible, and at males rather than females. In literature the ratio of men:women is 2:1 until 9:2⁽¹³⁾. Although it is more common in males, there is still no difference in number and localization between genders⁽¹⁴⁾. In patients without associated syndromes,

supernumerary teeth appear most frequently in the mandibular premolar region in a 45.29%, in the molar region in a 0.05% and anterior mandibular region in 0.04%. Distomolars are often impacted with a ratio impacted:erupted of 5:1⁽¹⁵⁾.

Although this study does not seek to detect the prevalence and incidence indices, it should be noted that in all three cases the subjects are female and do not have associated syndromes, whereas the literature cites a higher prevalence of supernumerary teeth at males with associated syndromes.

Conclusions

As a result, the absence of third molars in permanent dentition of the contemporary man is very common, but the presence of supernumerary teeth in the posterior area is very interesting. Clinical examination and paraclinical radiological explorations are required to establish a correct diagnosis and treatment planing.

Bibliography

1. Ionescu E. Anomaliile dentare. Editura Cartea Universitară, Bucuresti, 2005, 73-94.
2. Zegan G. Ortodonție și ortopedie dento-facială. Tehnopress, Iași, 2005, 99-108.
3. Anthonappa RP, Omer RSM, King NM. Characteristics of 283 supernumerary teeth in southern Chinese children. *Oral Surg Oral Med Oral Pathol Oral Radiol Endod* 2008;105:e48-e54.
4. Christopher S. D. Savitha AN, Lazarus F., Sankar P., Fourth Molars – Bilateral Impaction – A Case Report. *J Dent Res Updates* 2014 Dec; 1(1): 79-81.
5. Gündüz K., Muglali M. Non-syndrome multiple supernumerary teeth: A case report. *J Contemp Dent Pract* 2007;8:81–86.
6. Kaya E, Gungor K, Demirel O. Prevalence and characteristics of non-syndromic distomolars: a retrospective study. *J Investig Clin Dent* 2015;6:281-286
7. Mishra M. Types of hyperodontic anomalies in permanent dentition: Report of 5 cases. *Int J Clin Dent Sci* 2011;2:15-21
8. Fleming PS, Xavier GM, Diabiase AT, Cobourne MT. Revisiting the supernumerary: The epidemiological and molecular basis of extra teeth. *Br Dent J* 2010;208:25-30.
9. Rajab LD, Hamdan MAM. Supernumerary teeth: Review of the literature and a survey of 152 cases. *Int J Paediatr Dent* 2002;12:244-54.
10. Maity S., Kashyap RR., Naik V., Kini R., Begum N. Multiple Permanent Impacted Supernumerary Teeth in a Non-Syndromic Patient – A Case Report with a Review of Literature. *International Journal of Advanced Dental Science and Technology*, 2015, Volume 2, Issue 1, pp. 47-52.
11. Wang Xiu-Ping and Fan Jiabing. Molecular Genetics of Supernumerary Tooth Formation. *Genesis*. 2011. 49; 261-277.
12. Marcela De Oliveira Santos, Leticia Neido Magalhaes F. Moraes and col: 3rd and 4rd superior right molars exodontia in the same surgical act: case report. *BJSCR* Mar-May 2017.vol.1.18, n.2,pp.60-65.
13. Gaphor SM, Abdulkareem SA, Abdullah MJ. Unilateral maxillary distomolar: A casa report and review of the literature. *Journal of Dental and Medical Sciences*. 2014;13(4):17-20
14. Alvira-Gonzalez J, Gay-Escoda C. Non syndromic multiple supernumerary teeth: Meta-analisis. *J Oral Pathol Med* 2012;41:361-6
15. Pupkit Khandelwal, Hajira N. Supernumerary teeth-Fourth molars: bilateral maxillary distomolars An extremely rare case report. *Journal of applied Dental and Medical Sciences*, 2016.2, (1)