

TEMPOROMANDIBULAR JOINT IN JUVENILE IDIOPATHIC ARTRITIS: AN IMAGING STUDY AND ERGONOMIC CONSIDERATIONS

Cristina Iordache¹, Ana Maria Fătu¹, Cristina Pomârleanu², Daniel Scurtu³, Codrina Ancuța²

¹ Department of Implantology, Removable Dentures, Technology, School of Dentistry “Grigore T. Popa” University of Medicine and Pharmacy, Iași, Romania

² Rheumatology Department, “Grigore T. Popa” University of Medicine and Pharmacy, Iași, Romania

³ Dentist

*Corresponding author: Fatu Ana Maria

“Grigore T. Popa” University of Medicine and Pharmacy, Iași, Romania

Email: anafatu2007@yahoo.com tel +40745907257

ABSTRACT

Temporomandibular joint (TMJ) may be involved in different JIA subtypes, with a prevalence ranging between 40 to 70%, leading to various degrees of disability, mainly related to pain, inflammation, reduced mandibular mobility, damage of the condyle and secondary masticatory muscle impairment. The aim of the present work was to describe TMJ involvement in different subtypes of JIA, based on a complex epidemiological, clinical and imaging approach. We performed a prospective observational study on 22 consecutive JIA attending an academic rheumatology department. Imagistic assessments comprised: (i) an X-ray of vertebral (lumbar and cervical spine) as well as peripheral joints in order to support the diagnosis and to evaluate the stage of the disease; (ii) a TMJ ultrasonography; (iii) a TMJ CT scan; and (iv) a CBCT. The following parameters were evaluated in our patients: demographics and general characteristics (sex, age, duration of disease, JIA onset); TMJ-related data e.g. spontaneous or provoked unilateral or bilateral TMJ pain measured on a visual analog scale (VAS), accompanied by morning stiffness or stiffness after rest; clicking and crepitation were noted in the context mandible mobilization; muscle contracture (masseter, temporal, internal pterygoid); parafunctions; TMJ imaging; dental, gingival and occlusal status. TMJ involvement is classically described among JIA patients, presenting with various clinical signs and symptoms and different degrees of inflammation and condylar damage.

Key words: *temporomandibular joint, juvenile idiopathic arthritis, imaging assessment, ergonomics*

INTRODUCTION

Juvenile idiopathic arthritis (JIA) is currently a widely accepted term to describe different settings of chronic arthritis developing under 16 years old, and also the most common rheumatologic disease in children [1,2]. Since a large variability in signs and symptoms characterizing the disease are documented, seven separate JIA subtypes are actually recognized by ILAR,

the International League of Associations for Rheumatology, including systemic JIA, oligoarticular JIA, polyarticular rheumatoid factor negative and polyarticular rheumatoid factor positive JIA, psoriatic JIA, enthesitis-related JIA and undifferentiated arthritis as well. Both articular (axial and peripheral) and extraarticular features (particularly eye inflammation) may be responsible of significant disability and impaired quality of

life.

Although the pathobiology of JIA remains still poorly defined, a multifactorial contribution (e.g. genetic background, environmental triggers, autoimmunity and inflammation) is typically recognized. [3,4].

Temporomandibular joint (TMJ) may be involved in different JIA subtypes, with a prevalence ranging between 40 to 70%, leading to various degrees of disability, mainly related to pain, inflammation, reduced mandibular mobility, damage of the condyle and secondary masticatory muscle impairment. Moreover, early TMJ arthritis may be responsible for growth disorders (e.g. disturbed sagittal and vertical endochondral mandibular growth with condylar growth cartilage damage, eroded or resorbed condyle) and orthodontic issues due to micrognathia, impaired alignment of the jaw, limited anterior open bites, significant esthetic and functional restrictions; caries and periodontal problems represent another reality among JIA with TMJ arthritis [5,6,7].

Early diagnosis of TMJ arthritis usually requires a complex imaging assessment, since TMJ involvement may present with a wide range of clinical signs and symptoms; moreover, a dynamic approach is also mandatory in order to evaluate progression, activity as well as TMJ damage. Panoramic X-ray or ortopantomography (OPT), ultrasonography and computer tomography (CT) are typically used for both diagnosis and follow-up of TMJ arthritis, but newer techniques such as magnetic resonance imaging (MRI) and cone beam computer tomography (CBCT). A closer look into the imaging evaluation of TMJ in JIA is able to show different aspects. [8,9].

Thus, joint effusion and synovial involvement are commonly depicted with US and gadolinium, both techniques measuring also the activity of TMJ arthritis.

OPT and CT scan are of interest for the assessment of condylar damage; unfortunately none of them is able to detect early inflammatory synovial lesions and to point on active versus chronic synovitis with subsequent active or chronic damage. While OPT is traditional, simple and widely

available technique, actually CT is preferred for TMJ pathology providing a rapid and low radiating joint evaluation.

Interestingly, different US, CT and, even, MRI scoring systems are actually suggested for the assessment of synovitis activity and condylar damage in TMJ pathology.

We have to mention the role of CBCT, a novel technique specifically designed for dentistry, able to provide not only accurate 3D images of the surface of the condyle, but also to enhance the specificity of arthroscopic examination and treatment of different TMJ disorders; however, CBCT is not suitable for a correct evaluation of soft tissues involvement [10,11,12, 13,14].

The aim of the present work was to describe TMJ involvement in different subtypes of JIA, based on a complex epidemiological, clinical and imaging approach.

In the context of stomatognathic system lesions ergonomics contributes not only as a modern diagnostic approach, but also for correct functional oral rehabilitation [15].

MATERIAL AND METHODS

We performed a prospective observational study on 22 consecutive jia attending an academic rheumatology department (rheumatology 2 department, clinical rehabilitation hospital iasi, romania).

Patients were classified as having one of the seven subtypes of arthritis recognized by ilar: oligoarticular jia, polyarticular jia (both rheumatoid factor positive and negative), systemic jia, juvenile psoriatic arthritis, enthesitis-related arthritis, and undifferentiated arthritis.

A predefined set of inclusion and exclusion criteria were applied in all cases in order to select suitable patients for this project. Inclusion criteria were focused on: (i) pain in the tmj region (spontaneous or movement-related pain); (ii) joint stiffness (morning stiffness or stiffness after rest); (iii) difficulties in opening or closing the mouth; (iv) trismus; (v) noises felt in tmj (crepitation or crackles). Exclusion criteria included cranio-facial trauma, tumors and infections of facial and cranial region.

A dual, rheumatologic and orthodontic, examination was undergone in all cases, and a multifaceted protocol recording demographic, epidemiological, clinical, biologic and imaging data about the underlying disease, tmj and odontal-periodontal system was proposed for all cases.

Imagistic assessments comprised:

- (I) An x-ray of vertebral (lumbar and cervical spine) as well as peripheral joints in order to support the diagnosis and to evaluate the stage of the disease (radiology department, clinical rehabilitation hospital, iasi);
- (II) a tmj ultrasonography (radiology department, clinical rehabilitation hospital, iasi);
- (III) a tmj ct scan (radiology department "sf spiridon" clinical hospital, iasi); and
- (IV) a cbct ("edenta" laboratory, iasi).

The following parameters were evaluated in our patients:

- demographics and general characteristics (sex, age, duration of disease, jia onset);
- tmj-related data e.g. Spontaneous or provoked unilateral or bilateral tmj pain measured on a visual analog scale (vas), accompanied by morning stiffness or stiffness after rest; clicking and crepitation were noted in the context mandible mobilization; muscle contracture (masseter, temporal, internal pterygoid); parafunctions; tmj imaging;

- dental, gingival and occlusal status: partially or total edentation, with or without prosthesis, the degree of tooth mobility; gingival recession; malocclusion.

The study has received the ethics committee approval and all enrolled patients have signed the written informed consent.

Statistical analysis was performed in sas 4.3 software, both descriptive and analytical tests being proposed (χ^2 test, pearson correlation, anova tests) ($p < 0.05$).

Results and Discussions

Demographics and disease-related parameters are summarized in tables 1-3; as expected, we enrolled mainly female, with a mean age of 20.68 ± 4.84 years (range between 10 and 30 years), with both early and established disease.

Table 1: Distribution of cases by gender

Patients	Male		Female		Significance of difference
	n	%	n	%	P
JIA	6	27.27	16	*72.73	.04

Table 2: Average age groups studied

Patients	N	Average	σ	Min.	Max.	ESM	-95%	+950%
JIA	22	20.68	4.84	10	30	1.03	18.53	22.83

Table 3: The average duration of illness in groups examined

Patients	N	Average	Σ	Min.	Max.	ESM	-95%	+950%
JIA	22	8.55	4.35	1.00	15.00	.93	6.62	10.47

Clinical assessment of TMJ in JIA
The great majority of patients had TMJ

involvement; 81.82%, cases presented with bilateral TMJ involvement clinically

characterized by pain, stiffness, noises, and abnormal, painful TMJ mobility. The following data were demonstrated:

- Pain. 86.36% of patients felt pain at palpation in the pretragus area, 77.27% in the ear canal, while 77.27% reported pain at mastication. In addition, pain was felt when opening the mouth (100%); pain was common in the masseter (81.82%) and temporal muscles (81.82%), while contracture detected in 72.73% cases in the masseter, but also internal pterygoid muscle in 54.55%;

- Noises. 95.45% cases reported crepitus, while clicking less often (31.82%);

- Morning stiffness. About half of JIA presented with morning stiffness (54.55%).

Facial growth massive abnormalities were dominated by two features in JIA: sagittal and increased facial convexity.

TMJ imaging in JIA

The standard X-ray of the TMJ, either panoramic, is currently classified as unsatisfactory for the study of this joint. However, orthopantomogram is a good method, highlighting abnormal mandible and condyle, and was performed in all cases. Up to 50% of patients presented with different condyle lesions, potentially related to limited mobility of the mandible and to malocclusion (Table 4).

Table 4: Panoramic X-rays in studied JIA patients

Results	Cases (no)	%
Short mandibular ramus	9	40.91
Obtuse angle of mandible	7	31.82
Clamping articular space	2	9.09
Mandibular condyle osteoarthritic lesions	10	45.45
Mandibular condyle destructive lesions	1	4.55
Injury to the mandibular and temporal condyle	3	13.64
TMJ – normal	3	13.64

Furthermore, a standard radiological

assessment of the cervical spine was done in our patients, based on the well-recognized functional relationship with the stomatognathic system.

JIA is classically characterized by an increased proportion of degenerative disc-vertebral issues, although the age does not involve such a risk for our patients (Table 5).

Table 5: Cervical spine X-ray in studied JIA patients

Results	N	%
Normal	3	9.09
Degenerative lesions (osteophytes)	12	36.36
Syndesmophytes	15	45.45

TMJ ultrasound. Through its main attributes (non-invasive, inexpensive, repeatable), ultrasonography has a major contribution in diagnosing musculoskeletal pathology. A standard protocol for the ultrasonographic evaluation of the TMJ was applied in all cases, with cross-sectional sequences in different compartments. We performed both static and dynamic assessment with a Color Doppler Ultrasound System with a 10MHz probe, using the following score:

- the condyle shape: N (normal) = 0; flat (T) = 1, extended lysis (L) = 2;

- joint space: N (> 0.5) = 0; <0.5 = 1;

- the presence of increased amount of joint fluid (hypoechogenic): LA = 2

- condyl mobility-furniture condyle (trajectory amplitude): normal (M0) = 0; moderately impaired (M1) = 1, severely altered (M2) = 2;

- condyle surface: linear (CL) = 0; sclerosis (CCS) = 2; toothed (CD) = 3;

- temporal bone surface: linear (CL) = 0; sclerosis (CCS) = 1; Tooth (CD) = 2;

- erosion: one (E1) = 1; > 1 (E2) = 2;

- geode: one (G1) = 1; > 1 (G2) = 2;

- osteoporosis: OP = 1;

- disc abnormalities

- movement - DD = 1; morphological changes - MMD = 2;

- osteophytes: Os = 2;

We revealed inflammatory destructive

lesions (59.09%), but also degenerative signs in up to 18.18% (Table 6, Figure 1).

Table 6: Ultrasound examination results

Results	N	%
Normal	3	13.64
Inflammatory lesions	10	45.45
Destructive lesions	3	13.64
Destructive lesions + degenerative lesions	2	9.09
Osteoarthritis	4	18.18

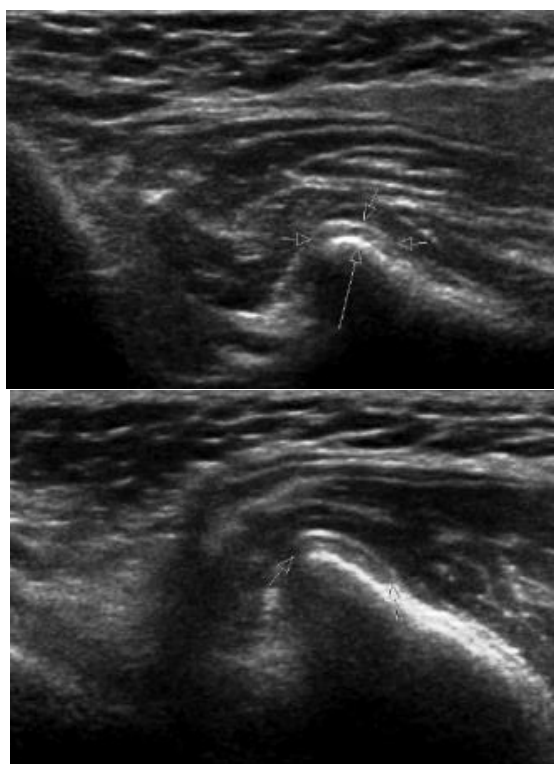


Figure 1. TMF ultrasound in JIA (a, b)

Computer tomography (CT) was applied for the first time in the TMJ study in 1980 (Suarez); since then CT was regarded as an effective method TMJ imaging (Manziona-1984 Sartoris- 1984 Larheim-1984 Reck-1986 Avrahami-1989).

In our patients, CT evaluation was performed according to a specific protocol and score (Goupil modified), comprising several parameters as follows:

- Condyle shape: convex (0) flattened (1) concave (2);
- Condyle size: normal (0), hypoplasia (1), hyperplastic (2);
- Erosions condyle: no (0), one (1)> 1 (2);

- Lysis condyle: mild (1), impairment (2);
- Condyle subchondral cysts: Yes (0); one (1); > 1 (2)
- Mandibular condyle sclerosis: yes (1) no (0);
- Temporal bone erosions: Yes (0); one (1); > 1 (2);
- Subchondral cyst time: no (0), one (1)> 1 (2);
- Temporal bone sclerosis: yes (1) no (0);
- Osteophytosis: yes (2) no (0);
- Joint space <0.5 mm (1); > 0.5 mm (0);
- Osteoporosis: yes (1) no (0);
- Ankylosis: yes (2) no (0);
- Disc calcification: yes (1) no (0);
- Condylar abnormalities mobility: yes (2) no (0).

The bone lesions were grouped according to their character – erosive-inflammatory, degenerative (osteoarthritis) and mixed (degenerative lesions associated with inflammatory-destructive ones), with a maximal estimated inflammation score of 14 and 7 for osteoarthritis.

We demonstrated the maximal CT score in 32.4% cases, particularly in those JIA with a disease onset at young age (10-12 years); therefore, pathological phenomena in JIA is characterized primarily by frequency and aggressiveness. Craniofacial changes and the lesions in the stomatognath system were not counted in our patients. Main CT abnormalities described in studied JIA are summarized in table 7.

Table 7. TMJ CT assessment in our JIA patients

CT lesion	Cases (no)	%
Degenerative lesions	3	33.33
Inflammatory lesions	4	44.44
Destructive lesions	2	22.22

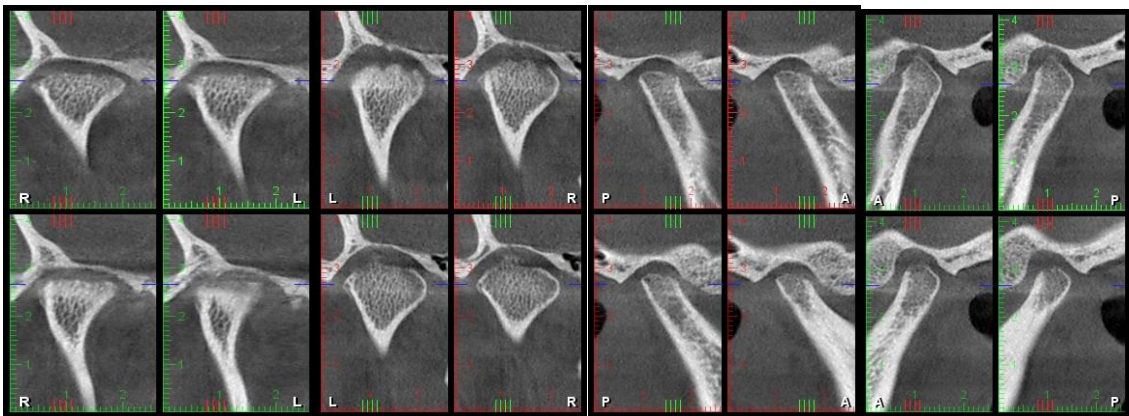
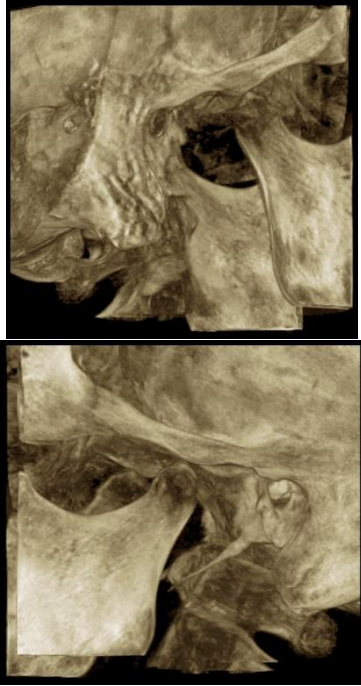
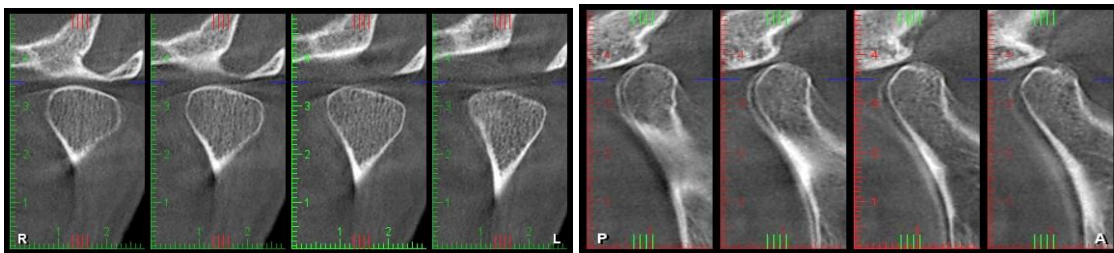


Figure 2. Native CBCT exam sections analyzed in the axial, coronal, sagittal and 3D (case 1)

Right TMJ: condyle aplasia, with remodeling and small osteophytes (anterolateral, posterolateral), with marked narrowing of the intraarticular space, small intra-articular bone bridges, irregular contour;

Left TMJ: remodeling osteoarthritis, with subchondral cysts and condyle remodeling, predominantly posterior narrowing of the joint space, intra-meniscal calcification



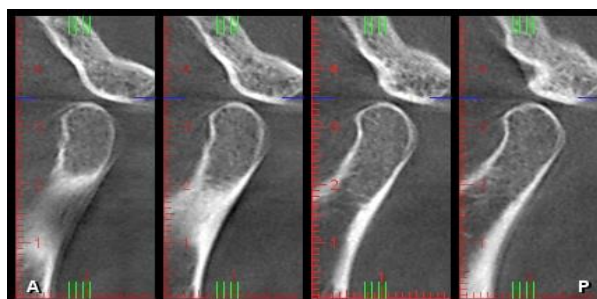


Figure 3. Native CBCT exam sections analyzed in the axial, coronal, sagittal and 3D (case 2)
Right TMJ: condyle with minimal subchondral geodes and osteosclerosis of posterior tubercle of the temporal bone, narrowing of the joint space

Left TMJ: thinning of cortical area condyle with small head subchondral erosions.

Conclusions

1. Juvenile idiopathic arthritis is usually characterized by high disability issues and significant impaired quality of life.
2. TMJ involvement is classically described among JIA patients, presenting with various clinical signs and symptoms and different degrees of inflammation and condylar damage.
3. A complex protocol including imaging assessment of TMJ arthritis may be necessary, providing a correct evaluation of the activity and tissue damage in JIA.
4. The complex pathology of the somatognath system commonly requires a prompt intervention of ergonomic concepts promoting the development of specific guidelines for dentistry field

REFERENCES

1. Priit Niibo, Chris Pruunsild, Ülle Voog-Oras, Tiit Nikopensius, Triin Jagomägi, Mare Saag, Contemporary management of TMJ involvement in JIA patients and its orofacial consequences, EPMA Journal, 2016; 7(12); 2-9.
2. Ringold S., Cron R.Q., The temporomandibular joint in juvenile idiopathic arthritis: frequently used and frequently arthritic, *Pediatr Rheumatol Online J.*, 2009, 7 (11)
3. Cannizzaro E., Schroeder S., Müller L.M., Kellenberger C.J., Saurenmann R.K., Temporomandibular joint involvement in children with juvenile idiopathic arthritis, *J Rheumatol*, 2011;38(3); 510–5.
4. Munir S., Patil K., Miller E., Uleryk E., Twilt M., Spiegel L., et al. Juvenile idiopathic arthritis of the axial joints: a systematic review of the diagnostic accuracy and predictive value of conventional MRI, *Am J Roentgenol.*, 2014: 202(1); 199–210.
5. Engstrom A.L., Wanman A., Johansson A., Keshishian P., Forsberg M., Juvenile arthritis and development of symptoms of temporomandibular disorders: a 15-year prospective cohort study. *J Orofac Pain*, 2007; 21;120–126.
6. Rönning O., Väliäho M.L., Laaksonen A.L., The involvement of the temporomandibular joint in juvenile rheumatoid arthritis, *Scand J Rheumatol*. 1974; 3(2); 89–96.
7. Weiss P.F., Arabshahi B., Johnson A., Bilaniuk L.T., Zarnow D., Cahill A.M, Feudtner C., Cron R.Q., High prevalence of temporomandibular joint arthritis at disease onset in children with juvenile idiopathic arthritis, as detected by magnetic resonance imaging but not by ultrasound. *Arthritis Rheum.*, 2008; 58; 1189–1196.
8. Müller L., Kellenberger C.J., Cannizzaro E., Ettlin D., Schraner T., Bolt I.B., et al. Early diagnosis of temporomandibular joint involvement in juvenile idiopathic arthritis: a pilot study comparing clinical examination and ultrasound to magnetic resonance imaging. *Rheumatology (Oxford)*, 2009;48(6); 680–5.
9. Jeffrey P., Okeson R., Differential Diagnosis of Temporomandibular Disorders and Other Orofacial Pain Disorders, *Dent Clin North Am*. 2011; 55(1); 105–20.
10. Wadhwa S., Kapila S., TMJ disorders: future innovations in diagnostics and therapeutics., *J Dent Educ.*, 2008; 72(8); 930–47.
11. Larheim T.A., Abrahamsson A.K., Kristensen M., Arvidsson L.Z., Temporomandibular joint diagnostics using CBCT. *Dentomaxillofac Radiol*. 2015; 44(1).

12. Kitai N., Kreiborg S., Murakami S., Bakke M., Møller E., Darvann T.A., et al. A three-dimensional method of visualizing the temporomandibular joint based on magnetic resonance imaging in a case of juvenile chronic arthritis, *Int J Paediatr. Dent.* 2002; 12(2); 109–15.
13. Assaf A.T., Kahl-Nieke B., Feddersen J., Habermann C.R., Is high-resolution ultrasonography suitable for the detection of temporomandibular joint involvement in children with juvenile idiopathic arthritis? *Dentomaxillofac Radiol.*, 2013; 42(3); 20110379
14. Pedersen T.K., Kuseler A., Gelineck J., Herlin T., A prospective study of magnetic resonance and radiographic imaging in relation to symptoms and clinical findings of the temporomandibular joint in children with juvenile idiopathic arthritis, *J Rheumatol.* 2008; 35; 1668–1675.
15. Gupta S., Ergonomic applications to dental practice, *Indian Journal of Dental Research*, 2011;22(6); 816-22.